Synchronous Central Nervous System Atypical Teratoid/Rhabdoid Tumor and Malignant Rhabdoid Tumor of the Kidney: Case Report of a Long-Term Survivor and Review of the Literature

Mohammad H. Abu Arja[1], Priyal Patel[1], Summit H. Shah[2], Jeffery J. Auletta[1], Erin K. Meyer[3], Suzanne E. Conley[1], Jennifer H. Aldrink[4], Jonathan A. Pindrik[5], Mohamed S. AbdelBaki[1]

Key words
- Atypical teratoid/rhabdoid tumor
- Autologous peripheral blood stem cell transplant
- Intrathecal chemotherapy
- SMARCB1
- Synchronous/metachronous rhabdoid tumors

Abbreviations and Acronyms
AT/RT: Atypical teratoid/rhabdoid tumor
CNS: Central nervous system
CT: Computed tomography
DFCI: Dana-Farber Cancer Institute
EU-RHAB: European protocol for AT/RT
GTR: Gross total resection
MRI: Magnetic resonance imaging
MRT: Malignant rhabdoid tumor
PBSCT: Peripheral blood stem cell transplant
SWI/SNF: Switch/sucrose non-fermentable

From the [1]Division of Hematology/Oncology/Blood and Marrow Transplant, Department of Pediatrics, [2]Department of Radiology, [3]Department of Pathology and Lab Medicine, [4]Division of General Pediatric Surgery, Department of Pediatric Surgery, The Ohio State University College of Medicine, and [5]Division of Pediatric Neurosurgery, Department of Pediatric Surgery, Nationwide Children's Hospital, Columbus, Ohio, USA

To whom correspondence should be addressed: Mohamed S. AbdelBaki, M.D.
[E-mail: Mohamed.AbdelBaki@nationwidechildrens.org]

Mohammad H. Abu Arja, MD, MSc, Priyal Patel, DO, contributed equally to this study.

Citation: World Neurosurg. (2018) 111:6-15.
https://doi.org/10.1016/j.wneu.2017.11.158

*Journal homepage: **www.WORLDNEUROSURGERY.org***

*Available online: **www.sciencedirect.com***

■ BACKGROUND: **Atypical teratoid/rhabdoid tumor (AT/RT) of the central nervous system (CNS) with synchronous or metachronous extra-CNS disease is a rare childhood malignancy with a dismal prognosis.**

■ CASE DESCRIPTION: **We report a 7-week-old female with metastatic AT/RT and synchronous malignant rhabdoid tumor of the kidney who received an intensive multimodal approach combining surgical resection, intrathecal chemotherapy, and high-dose chemotherapy with autologous peripheral blood stem cell transplant (PBSCT). She is currently 24 months old without any evidence of disease. In addition, we completed an extensive literature review of cases with CNS AT/RT and synchronous or metachronous extra-CNS primary tumors. To date, 31 pediatric cases have been reported, and the median overall-survival was 6 months after diagnosis. The only 3 survivors received autologous PBSCT, and 2 of these patients had complete resection of their CNS tumor.**

■ CONCLUSIONS: **The rarity of CNS AT/RT with extra-CNS primary disease and the lack of standard treatment contribute to its reported dismal prognosis. We report a case of a long-term survivor with metastatic AT/RT and synchronous extra-CNS primary tumor. Maximal surgical resection, intrathecal chemotherapy, and consolidative autologous PBSCT may improve prognosis and avoid radiation.**

INTRODUCTION

Atypical teratoid/rhabdoid tumors (AT/RTs) are infrequent and aggressive tumors of early childhood.[1] They are typically located in the central nervous system (CNS), kidneys, and soft tissues.[2] Approximately one-third of children diagnosed with rhabdoid tumors have germline inactivating mutations, which involve deletions and duplications of the SMARCB1 (INI1, hSNF5, BAF47) gene in chromosome band 22q11.2.[3]

SMARCB1 is a tumor suppressor gene that encodes a subunit of the switch/sucrose non-fermentable (SWI/SNF) chromatin-remodeling complex. SWI/SNF complex plays a crucial role in DNA differentiation, proliferation, and repair.[4] In addition, AT/RT can also be associated with inactivating mutations of SMARCA4 gene, which is another member of the SWI/SNF complex.[5] Most of the mutations are de novo. However, mutations can also be inherited as a familial syndrome known as *rhabdoid tumor predisposition syndrome*.[3] Individuals with germline mutations usually present in the first 3 years of life and have a higher incidence of developing synchronous or metachronous multiple primary rhabdoid tumors, as compared with patients with somatic mutations.[6] Children with CNS AT/RT are challenging to treat, and even more so in the presence of an extra-CNS rhabdoid disease.

We report on a 24-month-old female patient who had a SMARCB1 germline inactivating mutation and at the age of 7 weeks exhibited posterior fossa AT/RT and brain and spinal metastases along with synchronous malignant rhabdoid tumor (MRT) of the right kidney. She was treated with combination complete surgical resection of the intracranial tumor and the metachronous tumor of the kidney, triple intrathecal chemotherapy, and consolidative autologous peripheral blood stem cell transplant (PBSCT) without receiving radiation therapy. Furthermore, we review the literature on cases diagnosed with CNS AT/RT and either synchronous or metachronous extra-CNS disease.

MATERIAL AND METHODS

A literature search using the U.S. National Library of Medicine database PubMed was conducted. Information on clinical

presentation, histopathologic features, genetic manifestations, management strategies, and clinical outcomes for patients with CNS AT/RT and synchronous or metachronous extra-CNS disease was extracted from articles published from 1989 through September 2017. The search terms "atypical teratoid/rhabdoid tumor OR rhabdoid tumor predisposition syndrome OR rhabdoid tumor" were used. Initially, 474 primary hits were identified. Only articles that were written in English, targeted children aged 18 years or younger, and examined CNS AT/RT with synchronous or metachronous extra-CNS disease were included. Studies that examined only metastatic AT/RTs (M4) were excluded. Studies that reported extra-CNS primary rhabdoid tumors with primary CNS tumor that was not documented as AT/RT were excluded, unless a *SMARCB1* germline mutation or rhabdoid features in the primary brain tumor were documented (n = 2). Finally, the reference list of all articles that met the inclusion and exclusion criteria was searched manually to identify any related published manuscripts.

Clinical Presentation

A 7-week-old girl had a 1-week history of progressive vomiting, decreased oral intake, and lethargy. Physical examination demonstrated bulging fontanelles and increased head circumference. Brain magnetic resonance imaging (MRI) revealed a T1 hypointense, T2 isointense to hyperintense posterior fossa mass centrally located in the fourth ventricle, causing obstructive hydrocephalus and mass effect on the brainstem (**Figures 1A** and **B**). The mass extended into the left cerebellopontine angle and displaced the brainstem anteriorly (**Figure 1A**). The lesion demonstrated minimal thin linear enhancement pattern with small foci of susceptibility and showed small cysts in the central portion along with areas of restricted diffusion. Spine MRI demonstrated an intradural enhancing nodule splaying the cauda equina nerve roots at the L2 level and a solid mass within the middle to lower pole of the right kidney (**Figure 1C**). Computed tomography (CT) of the abdomen demonstrated a large hypodense renal mass with severe thinning of the overlying parenchyma (**Figure 1D**). CT of the chest and pelvis did not reveal additional disease. Moreover, the results of a lumbar cerebrospinal fluid cytology study were negative for malignant cells.

Gross total resection (GTR) of the posterior fossa mass was achieved, followed 1 week later by radical right nephrectomy and adrenalectomy. Pathologic analysis for both the intracranial and renal tumors revealed negative INI-1 immunohistochemical staining, confirming the diagnosis of a CNS AT/RT with synchronous disease in the right kidney. Furthermore, germline loss of the *SAMRCB1* gene was determined by whole blood gene sequencing. Follow-up brain MRI performed 3 weeks after the intracranial tumor resection and before starting systemic chemotherapy showed progressive multifocal intracranial disease with positive tumor resection margins (**Figure 2A**).

A tailored treatment strategy was designed, given the very young age of the patient and the available published data (described later). An induction phase based on the Dana-Farber Cancer Institute (DFCI) protocol for AT/RT was selected,[7] which consisted of eight, 21-day cycles incorporating vincristine, cisplatin, doxorubicin, cyclophosphamide, and triple intrathecal chemotherapy (methotrexate, hydrocortisone, and cytarabine). Consolidation phase included 2 cycles of high-dose chemotherapy with carboplatin and thiotepa followed by autologous PBSCT. Follow-up MRI 6 weeks after starting chemotherapy did not show any evidence of disease within the brain, spine or the chest, abdomen, and pelvis (**Figures 2B–D**).

Overall, the patient tolerated chemotherapy well, with the exception of sensorineural hearing loss that was likely caused by cisplatin-related toxicity. She has remained symptom-free and without clinical or radiologic evidence of relapse for nearly 2 years after her initial presentation.

Literature Review

A comprehensive literature review revealed 22 articles that met the predefined inclusion and exclusion criteria. Thirteen articles were case reports, and 9 were case series studies. Thirty children were reported to have synchronous CNS AT/RT and extra-CNS primary disease, and only 1 child had a CNS AT/RT with a metachronous renal rhabdoid tumor. Clinical

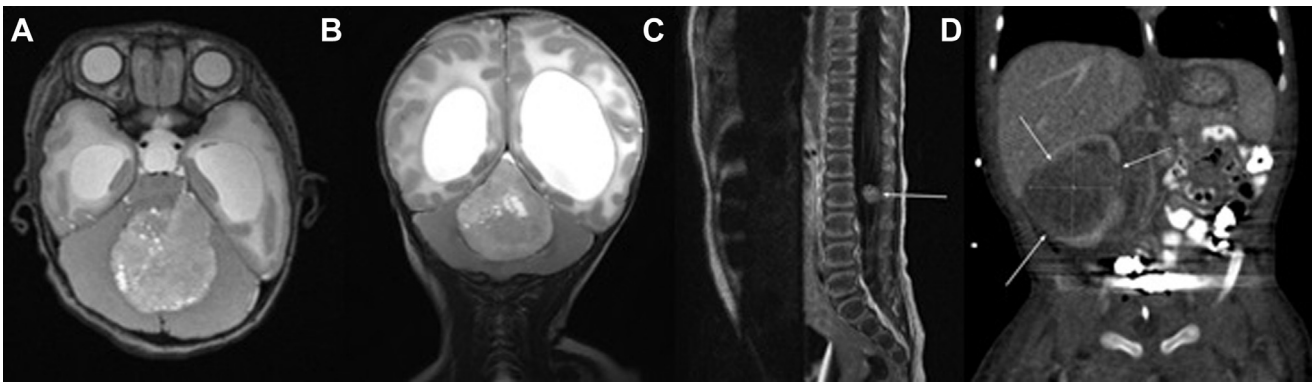

Figure 1. Initial magnetic resonance imaging (MRI) of the head and spine and computed tomography (CT) of the abdomen. (**A**) Initial brain MRI demonstrates a 4.2-cm posterior fossa mass extending through the left cerebellopontine angle, causing obstructive hydrocephalus on axial T2 imaging. (**B**) Coronal T2 MRI of the brain. (**C**) MRI of the lower spine reveals a 7-mm intraspinal, subarachnoid enhancing nodule at the L2 level with splaying of the cauda equina nerve roots. (**D**) Initial abdomen and pelvic CT scan shows a 3.6-cm hypodense mass within the right kidney without evidence of thrombus in the renal vein or inferior vena cava.