

Contents lists available at ScienceDirect



Future Dental Journal

journal homepage: <http://www.journals.elsevier.com/locate/fdj>

Intraparotid facial nerve schwannoma: A case report

Bacem A.E.O. Khalele

Ministry of Health, Cairo, Egypt

ARTICLE INFO

Article history:

Received 29 March 2016

Received in revised form

4 July 2016

Accepted 27 July 2016

Available online xxx

Keywords:

Schwannoma

Intraparotid

Facial nerve tumors

Benign

Ultrasound

Salivary glands sonography

ABSTRACT

Quite rarely, major salivary glands tend to display neural tumors. Intraparotid facial nerve schwannoma, when encountered, is often confusing given the similarity of the histological pictures of such tumors with other primary salivary variants and phenotypes as well as the lack of definitive histological findings of fine needle biopsies. Therefore, the final decision is usually made, at the surgical setting. There, the lesional intimacy to the nerve and the frozen biopsy of the safety margins determine, quite correctly, the best treatment option. This paper reports a rare case of intraparotid facial nerve schwannoma and focuses light on such a diagnostic challenge.

© 2016 Faculty of Oral & Dental Medicine, Future University. Production and hosting by Elsevier B.V. This is an open access article under the CC BY-NC-ND license (<http://creativecommons.org/licenses/by-nc-nd/4.0/>).

1. Introduction

Tumors of the salivary glands, especially major ones, are usually benign of which pleomorphic adenoma and Warthin tumor pose the highest incidence. Minor salivary glands, however, tend to favor, neoplastically speaking, malignancies. Very rarely, major salivary glands tend to develop neural benign and exceedingly rare malignant tumors [1]. Intraparotid facial nerve schwannoma (IPFNS) hits the trunk of the facial nerve (VII) or any of its terminal branches either at the glial- Schwann cell junction, located at the cerebellopontine angle, or at the intraparotid terminal nerves. When IPFNS represents clinically within the parotid gland, the designation of intraparotid facial nerve schwannoma is given [2]. This benign tumor is not only surgically challenging, given its relation to the facial nerve, but also diagnostically so. Confusing the histological variants and phenotypes, which is common in reading the sparse findings of fine needle biopsies, given the similarity to other primary salivary tumors, postpone the management options to the surgical scene. There, the lesional intimacy to the nerve and the frozen biopsy of the safety margins determine, quite correctly, the best treatment option [3].

2. Case presentation

A 48-year-old male had a small asymptomatic swelling in the right parotid gland. The patient has reported a slow growth, over years (Fig. 1). There was no dysfunction of the facial nerve. Conducting an ultrasound study, the right parotid gland showed a well-defined hypoechoic lesion within the glandular parenchyma (Fig. 2). The left gland was typically normal and so were the submandibular glands. The cervical lymph nodes revealed a slight reactionary affection while they preserved their oval shape and fat sinus. No other salient findings were observed. A sonar-guided pre-operative tru-cut biopsy was performed. Submitting the obtained tissues to the microscopic examination, the histological picture was suggestive of pleomorphic adenoma.

The patient, after signing an informed consent, was scheduled for surgery. At the surgical scene, the tumor was superficially related to the main trunk of the facial nerve. A careful dissection was performed and the lesion was excised without nerve injury. A frozen section was obtained from the periphery of the tumor to decide about the involved neural trunk. The result showed the margins to be free of tumor. Therefore, conservative partial parotidectomy was done.

The histological picture of the excised tumor read numerous slender spindle shaped cells, arranged in a biphasic tissue architecture. There, areas of hypercellularity as well as areas of relative hypocellularity were appreciated (Fig. 3). The hypercellular area demonstrated numerous broad interlacing ribbons of extended

E-mail address: bacemottoman@gmail.com.

Peer review under responsibility of Faculty of Oral & Dental Medicine, Future University.

<http://dx.doi.org/10.1016/j.fdj.2016.07.003>

2314-7180/© 2016 Faculty of Oral & Dental Medicine, Future University. Production and hosting by Elsevier B.V. This is an open access article under the CC BY-NC-ND license (<http://creativecommons.org/licenses/by-nc-nd/4.0/>).

Please cite this article in press as: Khalele BAEO, Intraparotid facial nerve schwannoma: A case report, Future Dental Journal (2016), <http://dx.doi.org/10.1016/j.fdj.2016.07.003>

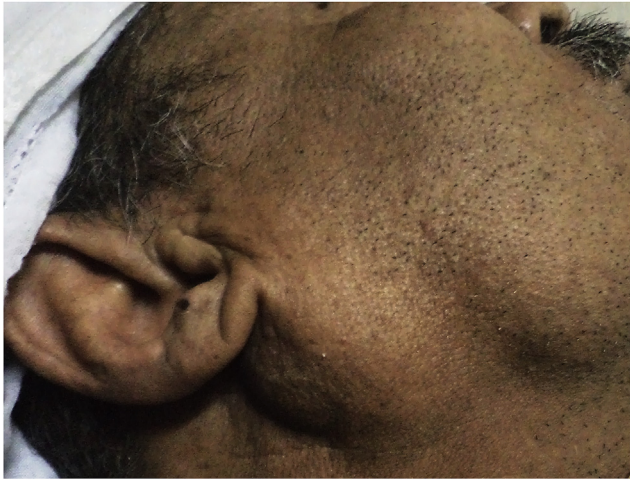

Fig. 1. Clinical picture showing a small lesion within the right parotid gland.

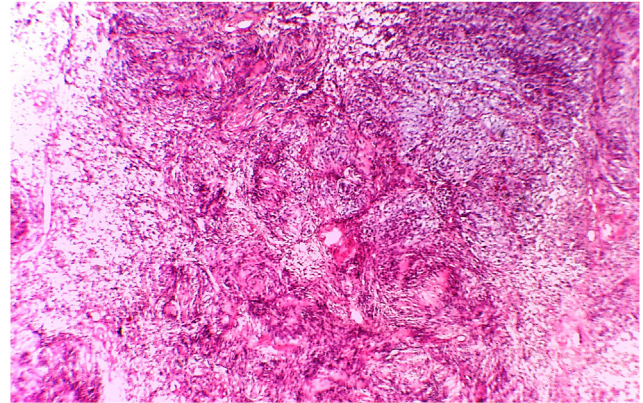


Fig. 3. Photomicrograph demonstrating areas of hypercellularity as well as areas of relative hypocellularity (Antoni A and B respectively) (H&E stain, Original magnification: 4×).

spindle cells with elongated nuclei arranged in waves, and ill-defined cytoplasm. Occasional nuclear palisading and Verocay body formation were conspicuous (Antoni A). However, the hypocellular areas evinced abundant acellular material punctuated by bland cigar-shaped nuclei, which demonstrated a little pleomorphism (Antoni B architecture) (Fig. 4). The arrangement of Antoni B displayed, partly, myxoid stroma, microcystic degenerative changes and several xanthoma cells (Fig. 5). Moreover, the overall picture characterized medium-sized vessels with ectasia, thrombosis and perivascular hyalinization. Notwithstanding, there were no reticular formations, lymphoid aggregations, peripheral entrapped ducts or cytological atypia. Mitotic figures and necrosis were also absent. The case was signed out as a benign intraparotid facial nerve schwannoma. Hitherto, there is no evidence of recurrence at 18-month follow-up. Moreover, the functionality of the facial nerve was considered, in May 2016, within normal.

3. Discussion

Intraglandular nerve schwannoma, solitary [4] or multiple [5], was reported in the major salivary gland, including, most often the

parotid, even, the sublingual glands [6]. The clinical picture of intraparotid facial nerve schwannoma (IPFNS) is, paradoxically, that of slowly growing asymptomatic swelling with sporadic cases of neural involvements [3].

In our reported case of solitary IPFNS, the patient has developed an asymptomatic slowly growing neural tumor. Even paresis of the motor facial nerve was not evident. However, the histological picture, read by two professors who are well-versed in head and neck pathology, was misleading. This may be attributed to the close similarity of schwannomas, in small sections, to pleomorphic adenoma or to the several phenotypes IPFNS may display [7–9]. Speaking of the categorization of the tumor, malignancy cannot be ruled out based on fine needle, tru-cut or on frozen-section biopsies [3]. Eschewing the inaccuracy of fine needle biopsies in salivary tumors, a sonar-guided pre-operative tru-cut biopsy was obtained in our case.

Ultrasound studies (US), on salivary glands, can differentiate benign lesions from the malignant ones [10]. This distinction is of an enormous significance. Although mitoses are usually absent in intraparotid facial nerve schwannoma and malignant transformation is exceptionally rare, few cases have been recently manifested a malignant transformation. This posed a diagnostic

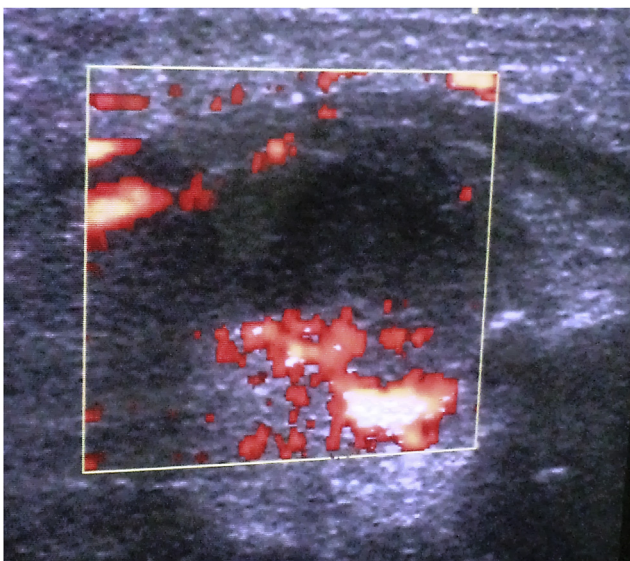


Fig. 2. Ultrasound picture characterizing a hypoechoic benign lesion, with a fair blood supply at the periphery, on Doppler interrogation.

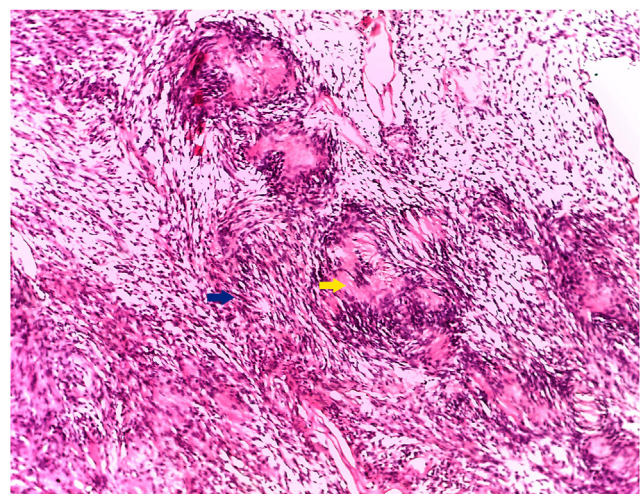


Fig. 4. Photomicrograph displaying spindle cells with elongated nuclei arranged in waves, and ill-defined cytoplasm (blue arrow). Focal Verocay body formation (yellow arrow) and occasional nuclear palisading are conspicuous. Hypocellular areas with myxoid stroma are also seen (H&E stain, Original magnification: 20×).

Download English Version:

<https://daneshyari.com/en/article/8697667>

Download Persian Version:

<https://daneshyari.com/article/8697667>

[Daneshyari.com](https://daneshyari.com)