



Contents lists available at ScienceDirect

# Journal of Oral and Maxillofacial Surgery, Medicine, and Pathology

journal homepage: [www.elsevier.com/locate/jomsmmp](http://www.elsevier.com/locate/jomsmmp)

## Case report

# Synovial chondromatosis of temporomandibular joint spreading into the cranial space

Antonio Romano<sup>a</sup>, Carmelo Lo Faro<sup>a,\*</sup>, Giovanni Salzano<sup>a</sup>, Giovanni Dell'aversana Orabona<sup>a</sup>, Marzia Petrocelli<sup>a</sup>, Raffaele Corvino<sup>a</sup>, Luigi Angelo Vaira<sup>b</sup>, Giorgio Iaconetta<sup>c</sup>, Luigi Califano<sup>a</sup>

<sup>a</sup> Division of Maxillofacial Surgery, Department of Neurosciences, Reproductive and Odontostomatological Sciences, University of Naples "Federico II", Via Pansini 5, 80131 Naples, Italy

<sup>b</sup> Operative Unit of Maxillofacial Surgery, University of Sassari, Viale San Pietro 43/b, Sassari, Italy

<sup>c</sup> Division of Neurosurgery, University of Salerno, Via Allende, 84081, Baronissi, Salerno, Italy

## ARTICLE INFO

### Keywords:

Synovial chondromatosis  
TMJ  
Large synovial joint  
Middle cranial fossa  
Cranial space

## ABSTRACT

Synovial Chondromatosis (SC) of the upper temporomandibular joint (TMJ) compartment spreading into the cranial space is a very rare condition and only 13 cases are described in Literature. The case of a 45-year-old woman with a slight swelling of the right TMJ and opening clicking is presented in this report. Patient orthopantomography showed large calcified masses in the right TMJ space. CT scan and MRI confirmed this finding showing granular masses surrounding the right condylar head spreading into the middle cranial fossa. After biopsy, the lesion was diagnosed as SC, and radical surgical excision was performed. A good functional recovery with no signs of recurrence at 18 months of follow-up was obtained with a good cosmetic result.

An extensive review of the literature has been performed and the results are presented in order to establish a correct diagnostic-therapeutic protocol for these oncologic patients.

## 1. Introduction

Synovial chondromatosis (SC) is a rare metaplastic disease that usually affects the large synovial joint. It is characterized by the formation of metaplastic cartilage nodules of the mesenchymal remnants, with or without calcification in the synovial membrane or floating free bodies in the synovial fluid inside the articular space [1]. These nodules may present themselves as attached or unattached osteocartilagenous calcified loose bodies within the joint. The three percent of the cases occur in the temporomandibular joint (TMJ) [2]. This disease is considered to be metaplastic and shows no malignant tendencies, but can become locally aggressive, eroding the cranial base and even spread intracranially [3,4]. However, this last condition is very uncommon and only 13 cases are reported in Literature [1,3–13].

SC aetiology and pathogenesis are still unclear. Some authors propose a correlation with traumatic injury of the synovial tissue in the joint space [14], but also a relationship with osteoarthritic processes have been mentioned [15].

Clinical presentation are often not-specific: pain, limitation or deviation of mandibular movements, displacement to the opposite side, inability to close the jaw. This nuanced clinical presentation can be mistaken as caused by mandibular disorders significantly delaying the

correct diagnosis.

A case of SC of the TMJ upper compartment spreading into the middle cranial fossa is presented in this report. Furthermore, an extensive review of the literature has been performed in order to establish a correct diagnostic-therapeutic protocol for these patients.

## 2. Case report

A 45-year-old Caucasian woman presented to the Naples "Federico II" Maxillo-Facial Surgery Unit with incidental right TMJ accidental mass evidence reported at orthopantomography examination (OPTG).

The patient did not report history of trauma, but presented TMJ disorders since the age of 24, with crepitation and opening clicking. She reported an episode of mandibular luxation at the age of 30.

Accurate anamnesis revealed an episode of limitation of mouth opening, occurred 15 years before, treated with analgesic therapy; patient also described increasing headache while chewing during the last 5 years. Clinical examination showed a slight swelling of the right TMJ and one-sided opening clicking. Initial imaging studies included OPTG and CT scans, followed by magnetic resonance imaging (MRI).

The OPTG revealed radio-opacity in the right TMJ region showing large calcified masses in the right TMJ space (Fig. 1). Axial and coronal

\* Corresponding author.

E-mail address: [carmelolofaro28@gmail.com](mailto:carmelolofaro28@gmail.com) (C. Lo Faro).

<https://doi.org/10.1016/j.ajoms.2018.01.006>

Received 17 January 2017; Received in revised form 27 December 2017; Accepted 26 January 2018

2212-5558/ © 2018 Asian Association of Oral and Maxillofacial Surgeons. Published by Elsevier Ltd All rights reserved.

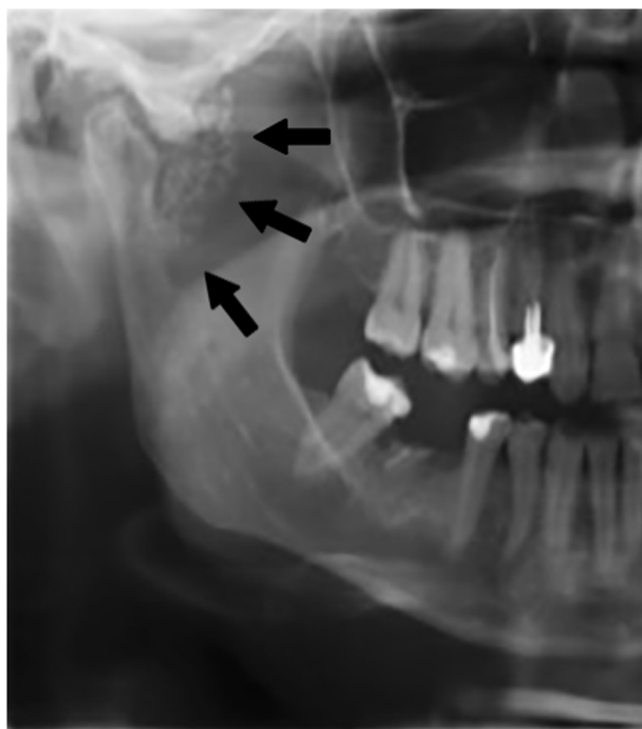


Fig. 1. OPTG shows large calcified masses in the right TMJ space.

CT images showed distinct nodules within an extremely expanded upper joint compartment and also revealed granular masses in the joint space surrounding the right condylar head. CT scan images showed a  $39 \times 13$  mm mass (Fig. 2) while the MRI images revealed the middle cranial fossa spreading of the mass that appeared in close relation with the extracranial portion of the internal carotid artery canal. An open biopsy of the lesion was performed under general anaesthesia through the Al-Kayat surgical approach to expose the right articular capsule. The capsule was then incised laterally and the upper and the lower compartments of the temporomandibular joint were exposed. The cartilaginous bodies were identified, removed, and sent to the histopathological examination in 10% formalin solution (Fig. 3).

The histological diagnosis was: “joint capsule parts with atypical chondral tissue” confirming the clinical diagnosis (Fig. 4). A radical surgical removal of the synovial chondromatosis of temporomandibular joint was then performed one month after the biopsy.

Surgical approach followed previous access on the right pre-auricular region. The mass and surrounding capsule were completely resected and a revision of cavity was performed through endoscopic assistance using  $0^\circ$  optic and  $45^\circ$  optic. The mass appeared in close contact with extracranial part of the internal carotid artery canal, spreading into the medial cranial fossa without interruption of the cranial dura mater. A CT scan follow-up was performed 6 and 12 months after surgery confirming the lesion radical excision (Fig. 5). Twenty-eight months after surgery, no clinical evidence of recurrence were evident with a satisfactory functional and aesthetic outcome

### 3. Discussion

SC is a rare proliferative disorder of the synovia that is associated with the formation of metaplastic cartilaginous or osteocartilaginous nodules in the synovial membrane, joints tendons and bursae. This condition was first reported in 1558 by Ambrosio Pare [16], but only in 1933 Axhausen described the first case of synovial chondromatosis affecting the temporomandibular joint [17]. Some authors have reported a female predominance of approximately 2:1, the right side is more often affected. Commonly, only one TMJ is affected but Peng et al. [18]

reported a case of bilateral occurrence of the disease. The age at the diagnosis range from 39 to 55 years though the onset of TMJ SC mostly occurs later than in other joints. Aetiology of SC is not clearly recognized, Martin-Granizo et al. [19] divided SC cases in two categories: primary SC without specific aetiological factors that represent an active cartilaginous metaplasia originating in the synovial membrane, and secondary SC related to previous trauma, repetitive micro-trauma and degenerative arthritis or other arthropathies where a less cellular atypia was found.

The symptoms of TMJ SC are non-specific: pain, swelling, limitation of the movements of the jaw and crepitation or clicking sound when opening the mouth, malocclusion. The presence of cranial nerve dysfunction indicates that the disease has reached an advanced stage. SC may extend from TMJ to the surrounding tissues: parotid gland, middle ear, intra-cranial space. In the case presented in this report, the patient was referred to our institution for an accidental mass reported on the orthopantomography. The referred symptoms were slight swelling of the right TMJ and one-sided clicking sound when opening the mouth.

Diagnosis is based on clinical manifestations, radiological imaging and histological examination. The differential diagnosis included condylar tumors, osteoarthritis, avascular necrosis, osteochondrytis, rheumatoid arthritis and intra-capsular condylar fractures [20–22].

The radiological images (OPTG, CT scan, MRI) show asymmetry of the condylar heads and/or glenoid fossa, a brighter joint space, or a mass in the TMJ compartment.

Most authors report CT and MRI as the most useful imaging techniques for diagnosis and surgical planning. CT scan allows a wider visualization of the joint space clearly showing erosions of the glenoid fossa, bony alterations of the skull base and condyle head and intracranial spreading mass [23,24]. CT scan also shows multiple calcified loose bodies in the joint space which form the basis of Milgram's classification [23–25]. According to Wong et al., [26]. MRI is the gold standard in the case of TMJ SC: through T2-weighted images it is possible to identify fluid and loose body components and detect the extension of the lesion to the dura mater.

In our experience MRI and CT scan images allow a complete and satisfying surgical planning. According to current Literature, we performed an open biopsy to confirm the radiologic diagnosis [27]. The pathological findings showed the cartilaginous nodules embedded within the synovium, and the chondrocytes frequently show moderate to severe atypia, which were compatible with SC.

The histological evidence of SC is a benign chronic inflammation of the synovium with metaplastic activity. In 1977, Milgram [28] described a 3-phase course of SC in the limb joint. The first stage involves metaplastic changes in the synovial membrane without the presence of detached particles, the second stage is characterized by metaplasia of the synovial membrane with the presence of detached particles, and the third stage shows only detached particles, which may vary in diameter from less than 1 mm to 10 mm.

In 1993, Gerard [29] divided SC in 4 stages based on the synovial activity of the disease:

Stage 1: presence of fibrocartilaginous nodules with plenty of ground substance in the synovium.

Stage 2: presence of a very thick synovium with numerous small calcification or ossification cartilaginous nodules.

Stage 3: presence of large ossified nodules.

Stage 4: the synovium is nearly normal or atrophic without any sign of metaplasia.

According to the radiological and histopathological aspects, our patient is classified as a phase III in Milgram's classification, as a stage III in Gerard's classification.

Malignant transformation of SC of the TMJ appears to be very uncommon; some authors reports a relative 5% malignancy risk of SC in large joints, and in the literature only few cases of malignant transformation of SC involving the TMJ have been described [11,30].

According to current scientific Literature, enucleation of the lesion

Download English Version:

<https://daneshyari.com/en/article/8700583>

Download Persian Version:

<https://daneshyari.com/article/8700583>

[Daneshyari.com](https://daneshyari.com)