Journal of Oral and Maxillofacial Surgery, Medicine, and Pathology xxx (2017) xxx–xxx

Contents lists available at ScienceDirect

Journal of Oral and Maxillofacial Surgery, Medicine, and Pathology

journal homepage: www.elsevier.com/locate/jomsmp

Case report

Ganglion cyst occurring in the temporomandibular joint: A case report

Hiromi Otawara[a,e,*], Yoshinori Jinbu[a], Yasuhisa Shinozaki[a], Hiroto Ito[a,f], Tadahide Noguchi[a], Natsuki Segami[b], Kaoru Kobayashi[c], Naoyuki Matsumoto[d], Yoshiyuki Mori[a]

[a] Department of Dentistry, Oral and Maxillofacial Surgery, Jichi Medical University, Japan
[b] Department of Dentistry, Oral and Maxillofacial Surgery, Kanazawa Medical University, Japan
[c] Department of Oral and Maxillofacial Radiology and Diagnosis, Tsurumi University School of Dental Medicine, Japan
[d] Department of Pathology, Tsurumi University School of Dental Medicine, Japan
[e] Department of Dentistry, Oral and Maxillofacial Surgery, Kyowa Chuo Hospital, Japan
[f] Department of Dentistry, Oral and Maxillofacial Surgery, Nasu Red Cross Hospital, Japan

ARTICLE INFO

Article history:
Received 26 October 2016
Received in revised form 25 June 2017
Accepted 31 August 2017
Available online xxx

Keywords:
Ganglion cyst
Temporomandibular joint

ABSTRACT

Ganglion cysts frequently occur on the dorsal side of the carpal joints, but rarely involve the temporomandibular joint. We encountered a 64-year-old woman with a chief complaint of swelling in the right cheek. Lipoma was observed in the right cheek on magnetic resonance imaging, along with a cystic lesion in the left temporomandibular joint. The cyst in the left temporomandibular joint was extracted under general anesthesia. Histological diagnosis was ganglion cyst. We report our experience with a case of ganglion cysts occurring on the temporomandibular joint with reference to the literature.
© 2017 Asian AOMS, ASOMP, JSOP, JSOMS, JSOM, and JAMI. Published by Elsevier Ltd. All rights reserved.☆

Introduction

Ganglion cyst is a cystic disease that occurs on tendons as well as in the vicinity of synovial joints, and must be distinguished from synovial cyst, as a similar cystic disease in which the cavity becomes lined with synoviocytes. Ganglion cysts frequently occur on the dorsal side of the carpal joints, but rarely involve the temporomandibular joint [1]. We report herein a case of ganglion cyst occurring in the temporomandibular joint, and discuss with reference to the literature.

Case report

The patient was a 64-year-old woman with a chief complaint of swelling in the right cheek. She had been aware of increasing swelling in the right cheek since June 2012 and had observed its progress, finally consulting the Department of Plastic Surgery at another hospital when no improvement was observed. She was subsequently referred to the Department of Oral Surgery of the same hospital for examination in December 2012. Lipoma was observed in the right cheek on magnetic resonance imaging (MRI), along with a cystic lesion in the left temporomandibular joint, so she was referred to our department for treatment of the right temporomandibular joint. Her medical history included pyelonephritis.

The patient was in good general condition, with mild swelling observed in the right cheek. No tenderness or clear mass was observed in the right temporomandibular joint on palpation. She was able to open her mouth unaided to a maximum of 38 mm and mild trismus was observed. No pain was observed in the temporomandibular joint when opening or closing the mouth. No modification of the incisal path was evident.

No deformation was observed in either mandibular condyle on panoramic radiography and no abnormalities were apparent in the vicinity of the temporomandibular joint (Fig. 1).

A 10-mm, well-defined, oval mass was observed in the left anterior mandibular condyle on MRI. The mass was hyperintense on T2-weighted imaging (Fig. 2) and hypointense on T1-weighted imaging (Fig. 3). The interior portion was homogeneous. The clinical diagnosis was synovial cyst of the left temporomandibular joint.

In April 2013, the cyst in the left temporomandibular joint was extirpated under general anesthesia. Skin incision was followed by temporomandibular joint endoscopy. A pre-articular approach to the cyst using the "AL-KAYAT" method was made from the supe-

* Corresponding author at: Department of Dentistry, Oral and Maxillofacial Surgery, Jichi Medical University, 3311-1 Yakushiji, Shimotsuke, Tochigi, Japan.
E-mail address: oralsurg@jichi.ac.jp (H. Otawara).

http://dx.doi.org/10.1016/j.ajoms.2017.08.008
2212-5558/© 2017 Asian AOMS, ASOMP, JSOP, JSOMS, JSOM, and JAMI. Published by Elsevier Ltd. All rights reserved.☆

Fig. 1. Panoramic radiography. No deformations are apparent in either mandibular condyle on panoramic radiography, and no abnormalities are evident in the vicinity of the temporomandibular joint.

rior articular cavity and a slightly translucent synovial cyst was observed on the anterior side of the articular disk. The cyst was exfoliated from the lateral pterygoid muscle, but mucoid contents leaked during extraction and the cyst self-destructed, and so was extirpated with some of the lateral pterygoid muscle (Fig. 4). Specimens were extracted as multiple fragments.

Histopathologically, a cystic lesion was observed (Fig. 5). The cystic wall was composed of dense collagenous connective tissue without synovial lining cells (Fig. 5, area A). Mucoid degeneration was observed within cystic the wall (Fig. 5, area B). The histological diagnosis was ganglion cyst.

No trismus or facial palsy was observed following surgery, no relapse was seen on MRI 3 years postoperatively, and no recurrence has since been observed (Fig. 6).

Discussion

Ganglion cysts are cystic lesions containing hyaluronic acid, and frequently occur on the dorsal side of the carpal joints. The underlying mechanisms are unknown, but are considered likely to involve joint capsule and a thecal collagen-like myxomatosis or cyst-like softening [1].

Our search of the literature identified 26 cases of ganglion cyst since 2000 [2–23], including the present case (Table 1). Patients ranged in age from 12 to 88 years old, with a mean of 49.4 years.

Fig. 3. T1-weighted MRI. The mass is hypointense on T1-weighted imaging.

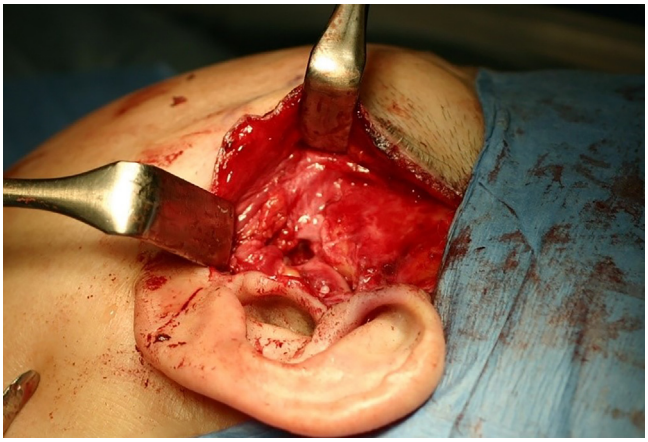

Fig. 4. Ganglion cyst after self-destruction during surgery ("AL-KAYAT" incision).

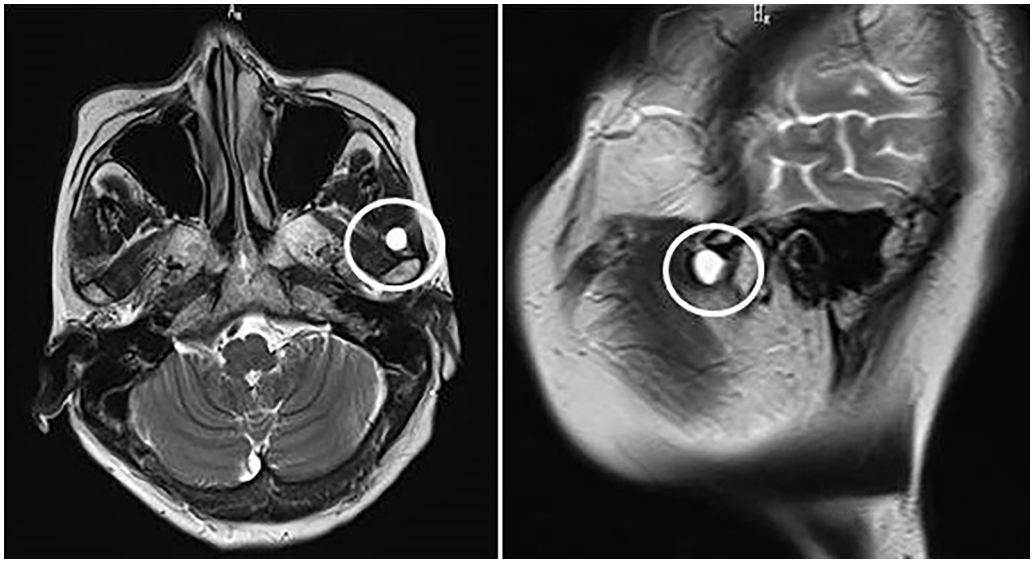

Fig. 2. T2-weighted MRI. A 10-mm, well-defined, oval mass is seen in the left anterior mandibular condyle.

Please cite this article in press as: Otawara H, et al. Ganglion cyst occurring in the temporomandibular joint: A case report. J Oral Maxillofac Surg Med Pathol (2017), http://dx.doi.org/10.1016/j.ajoms.2017.08.008

Download English Version:

https://daneshyari.com/en/article/8700630

Download Persian Version:

https://daneshyari.com/article/8700630

Daneshyari.com