JPFA-111; No. of Pages 4
ARTICLE IN PRESS
JOURNAL OF PIERRE FAUCHARD ACADEMY (INDIA SECTION) XXX (2016) XXX–XXX

Available online at www.sciencedirect.com
ScienceDirect
journal homepage: www.elsevier.com/locate/jpfa

Andrews Bridge: A fixed removable prosthesis

Anup Gopi *, *N.K. Sahoo*

CMDC(WC), India

ARTICLE INFO

Keywords:
Ridge defects
Fixed removable prosthesis
Andrews Bridge
Bar & Clip prosthesis

ABSTRACT

Prosthodontic rehabilitation of a large anterior ridge defects is often a challenge. Such defects require not just the replacement of the missing teeth, but also closure of the defective area so as to achieve proper speech and esthetics. Andrews Bridge is a fixed-removable prosthesis that is one of the treatment modality indicated in patients with large ridge defects. The prosthesis successfully replaces the missing teeth along with complete closure of the defect, restoring speech and esthetics. This article presents a case report describing the process of fabrication of Andrews Bridge to treat a Siebert's Class III anterior ridge defect using natural teeth as abutments for its fixed component followed by a removable superstructure.

1. Introduction

Prosthodontic rehabilitation of a large anterior ridge defects is often a challenge. An Andrews Bridge is a fixed-removable prosthesis that is one of the treatment modalities indicated in patients with large ridge defects. Apart from providing maximum aesthetics and optimum phonetics in cases involving considerable supporting tissue loss or when alignment of the opposing arches or aesthetic position of the replacement teeth creates difficulties, another favourable criterion of the Andrew's bar system is that it can be removed by the patient for hygiene. This forms an alternative faster and efficient treatment option compared to surgical correction and rehabilitation following the placement of implants.

2. Case report

A 33-year-old male patient was referred from the division of Oral and Maxillofacial Surgery for evaluation and prosthetic rehabilitation. On eliciting the history, the patient had undergone multiple surgical procedures following a road traffic accident for fracture of frontal bone, zygomatico-maxillary complex fracture, bilateral sub condylar fracture and fracture parasymphysis. Extra-oral examination revealed multiple scar marks and a facial deformity. The anterior portion of the chin was depressed extending from the junction of the vermilion border of the lower lip up to the base of the mandible (Fig. 1). It was also associated with a whistling speech. Intra oral examination revealed missing teeth number 31, 32, 33 and 41 with an associated alveolar defect extending up to the basal bone (Fig. 2). Teeth number 34 and 42 were restored with composite restorations. A three-unit full coverage Porcelain fused to metal (PFM) fixed partial denture was present replacing missing 21. The occlusion was group function on the left side and canine protected on the right side. An orthopantamograph (OPG) was taken to check the condition of the remaining teeth and the supporting bone to help in the diagnosis and treatment planning (Fig. 3). OPG revealed multiple bone plates in the anterior region of the mandible with loss of alveolar bone in the area of the missing

* *Corresponding author at*: No-321, Sector B, Chandimandir, Haryana 134107, India.
E-mail address: anup.gopi@yahoo.in (A. Gopi).

http://dx.doi.org/10.1016/j.jpfa.2016.10.002

Please cite this article in press as: Gopi A, Sahoo NK. Andrews Bridge: A fixed removable prosthesis, *J Pierre Fauchard Acad (India Sect)*. (2016), http://dx.doi.org/10.1016/j.jpfa.2016.10.002

Fig. 1 – Pre-operative extra oral view.

Fig. 2 – Intra oral view showing the alveolar defect.

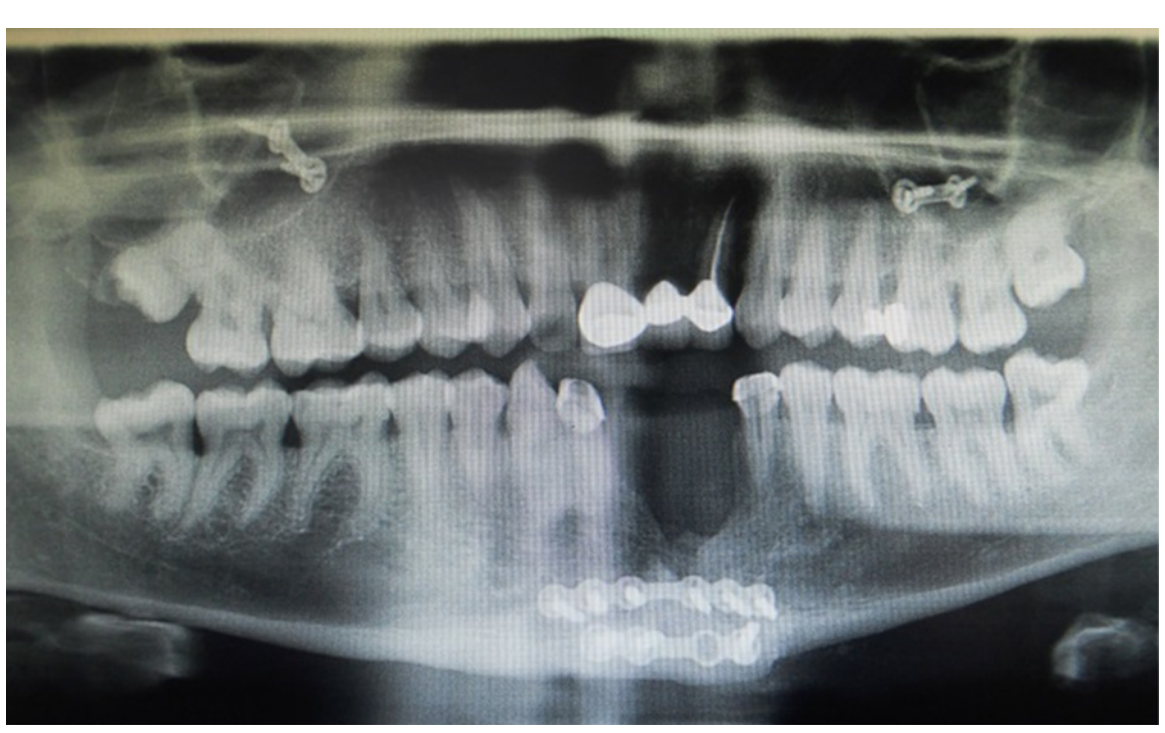

Fig. 3 – OPG depicting the extent of the defect.

Fig. 4 – Tooth preparation.

Fig. 5 – Coping Trial.

teeth. A diagnosis of a post-traumatic partially edentulous mandibular arch with a residual dentoalveolar defect was made. Considering the clinical situation, it was decided to rehabilitate the patient using a fixed and a removable prosthodontic intervention. A teeth supported Andrews Bridge with a modified hybrid prosthesis to restore the lost tooth and residual alveolar defect was planned. Arbitrary face bow transfer was done to a Hanau semi adjustable articulator and the casts were mounted in maximum intercuspation. The incisal guidance on the articulator was then customised using autopolymerising resin.

In the first phase of treatment, teeth no.: 34, 35, 42 and 43 were prepared for a full coverage PFM restoration (Fig. 4) and impressions were made using addition silicone impression material. Provisional crowns were fabricated and luted on the prepared teeth simultaneously. The wax pattern was fabricated on the prepared die and a bar assembly of the appropriate size was contoured, cut and waxed up to follow the contour of the residual alveolar ridge without interfering with the surrounding mucosa and also ensuring adequate self-cleansing space between the pattern and the floor of the mouth. The entire framework of the bar and the waxed up crown was then sprued, invested and casted. Occlusion was first adjusted on the articulator and then checked intra orally. The framework was then trimmed and finished before a try in was done to check for the extension and fit (Fig. 5). The metal coping framework was also checked for any interference in centric, protrusive and eccentric movements. Try in was repeated once again after porcelain firing. The occlusion was maintained as group function on the left side and canine protected on the right side. Glaze firing was done and the entire crown assembly with the bar was luted into the patient's mouth (Fig. 6). The anterior bar with the crowns was luted using a provisional cement until the entire prosthesis was finished, and anterior guidance was established.

Please cite this article in press as: Gopi A, Sahoo NK. Andrews Bridge: A fixed removable prosthesis, *J Pierre Fauchard Acad (India Sect)*. (2016), http://dx.doi.org/10.1016/j.jpfa.2016.10.002