



Contents lists available at ScienceDirect

Journal of Prosthodontic Research

journal homepage: www.elsevier.com/locate/jpor



Technical procedure

Metal free, full arch, fixed prosthesis for edentulous mandible rehabilitation on four implants

Alfredo Passaretti^a, Giulia Petroni^a, Giovanna Miracolo^b, Valeria Savoia^b,
Angelo Perpetuini^b, Andrea Cicconetti^{a,*}

^a Department of Oral and Maxillofacial Sciences, Sapienza University of Rome, Italy

^b Private Practice, Rome, Italy

ARTICLE INFO

Article history:

Received 30 November 2015
Received in revised form 4 September 2017
Accepted 20 October 2017
Available online xxx

Keywords:

Trinia
Fiber reinforced composite material
Metal-free
Short implant

ABSTRACT

Purpose: The goal of this work is to describe an implant-prosthetic protocol for rehabilitation of edentulous mandible, by using a fixed prosthesis made of fiber-reinforced composite material (FRC). The protocol contemplates a minimal invasive surgery and ensures predictable and safe results, with good aesthetic and performance combined to cost savings.

Methods: FRC material is used to build the substructure of a prosthetic framework supported by four short implants (5 mm long and 4 mm wide). The prosthesis substructure is made of Trinia immersed in a matrix of epoxy resin (FRC). It is supplied in milling blocks (pre-cured) for the CAD/CAM (computer-aided design/computer-aided manufacturing) technique.

Implants are placed in lower edentulous jaw in position of first molar and canine, each side. Four month after, a resin bar is build based on a stone model, denture teeth are placed and the occlusion is checked. The resin bar and the stone model with milled abutments are scanned and a FRC bar is achieved with the CAD/CAM technique. The teeth are mounted to the substructure trough denture resin. Temporary cementation of framework is achieved on the abutments connected to the implants.

Conclusion: A protocol for a fixed mandibular implant-prosthetic rehabilitation is described. The protocol contemplates a minimal invasive surgery and ensures predictable and safe results, with good aesthetic and performance combined to cost savings. In addition, this technique allows performing basic surgery also in presence of atrophy.

© 2017 Japan Prosthodontic Society. Published by Elsevier Ltd. All rights reserved.

1. Introduction

Replacing dental tissues is one of the primary goal of dentistry. Continuous research for dental materials able to reproduce teeth is carried on. Although metal ceramic restoration is still the gold standard in prosthetic dentistry [1,2], in the last few years the interest was focused on composite materials [3–6]. Many studies have been conducted [7–12] to evaluate the performance of fixed partial dentures made of composite material, which offer several advantages over traditional metal-ceramic systems, including: improved aesthetics, a biomechanical behavior more akin to natural dentition (biomorphism) and the possibility of repairing or modifying denture chairside [11,13]. The main alternatives to the metals

are pressed ceramic, zirconia ceramics and fiber-reinforced polymer (FRP) materials. Given the limited applications of pressed ceramic [14,15] and the frequent “chipping” of porcelain layered on zirconia ceramics, research interest has turned toward fiber-reinforced polymer (FRP) [16–19].

Fiber-reinforced composite material (FRC) materials have been shown to achieve better functional-esthetical result and a good bio-tolerability [20–24]. In this study, we describe an implant-prosthetic protocol for rehabilitation of edentulous mandible, by using a fixed prosthesis made of FRC. The protocol contemplates a minimal invasive surgery and ensures predictable and safe results, with good aesthetic and performance combined to cost savings.

2. Materials and methods

2.1. Indications to the technique

This procedure is indicated in all cases of edentulous mandible needing a fixed rehabilitation [25–27]. Particularly, the technique

* Corresponding author at: Department of Oral and Maxillofacial Sciences, School of Dentistry, Sapienza University of Rome, Via Caserta 6, 00161 Rome, Italy.
E-mail address: andrea.cicconetti@uniroma1.it (A. Cicconetti).

is indicated to patients with a mandibular complete denture who complain for discomfort or poor esthetic results.

2.2. Patient selection

Patients with mobile prosthesis in the lower jaw were recruited, based on clinical and radiographic examinations.

2.3. Surgical procedure

Patients receive four short implants (Bicon LLC, Boston, MA, USA), 4 mm in diameter and 5 mm in height to support the fixed prosthesis. The implant is characterized by a plateau design, a crestal module with pure locking taper connection, sloping shoulder, abutment hemispheric profile and calcium phosphate based treatment. The implants and abutments of the system are made from Ti-6Al-4V alloy.

Implants are inserted in lower edentulous jaw in position of first molar and canine, each side, through small surgical access. Four months after the first surgical stage, the implants are uncovered and healing abutments are placed.

2.4. Prosthetic procedure

The prosthesis substructure is made of Trinia (Bicon LLC) made up of interlaced multidirectional, multilayered fiberglass, immersed in a matrix of epoxy resin (FRC). It is supplied in milling blocks (pre-cured) for the CAD/CAM (computer-aided design/computer-aided manufacturing) technique.

After 15 days of healing, the abutments are removed and related transfers with their copings are connected to the fixtures (Fig. 1). An implant-level transfer impression is recorded in silicone material. The bite is recorded with articulation wax.

The stone model reproducing the position of the implants in the oral cavity is mounted in an articulator with the antagonist. Appropriate abutments are selected and milled parallel to one another with a 2–4° axis (Fig. 2). The model with the milled abutments is used to fabricate a light cured resin bar, and then used to set up denture teeth for an intra-oral confirmation.

Once the denture set-up has been clinically approved, a facial occlusal silicone mask is formed over the denture wax set-up. Denture teeth are removed from the resin bar and glued to the silicone mask with a cyanoacrylate glue. The stone model with the milled abutments and the resin bar are sprayed separately and digitally scanned (DS Scan, EGS).

The fiber-resin bar is digitally designed (EXOCAD) on the computer, with a minimum thickness of 7.0 mm throughout, an abutment clearance of 30 microns for cement and a maximum

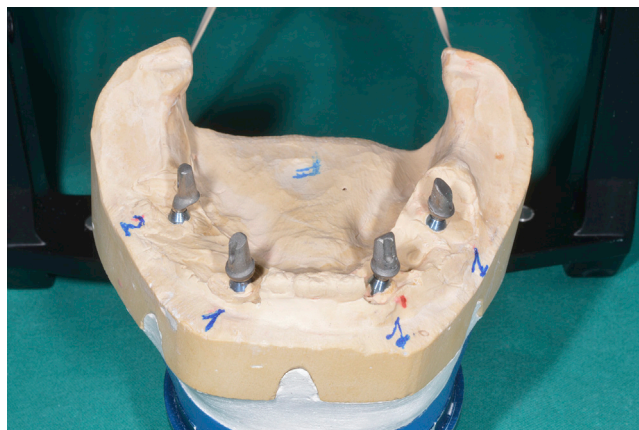


Fig. 2. Stone model with milled abutments. The parallel milling is necessary to achieve a passive fitting of prosthesis.

cantilever extension of 21.0 mm. The project is realized using a milling machine operating on five axes (Roland DWX-50). The machine uses diamond-hardened drills and works at 1 and 2 mm to 16,000 rpm for the roughing stage and up to 25,000 rpm in the finishing stage (Fig. 3).

After the milling, the bar is manually reduced and checked on the stone model with the abutments. Additionally, the sequence of insertion of the milled abutments is defined and the fitting is verified with the silicone mask. A denture resin is poured into the silicone mask to secure teeth to the bar. Final polymerization is achieved under hot water, with an air pressure of three bars. After polymerization, the prosthesis is removed from its silicone mask, and then finished and polished in a conventional manner.

The prosthesis itself is used to orient and place the abutments in the well of the implants following the pre-ordered sequence. The fitting of the framework is checked and the Morse taper connection is activated. Temporary cementation of framework is achieved (TempBond, Kerr). The occlusion is evaluated and adjusted (Figs. 4 and 5).

3. Difference from conventional methods

The first difference from conventional methods is that this procedure limits the indications for bone graft or regeneration, thus using the residual native bone. This is important because horizontal and vertical bone augmentation procedures are

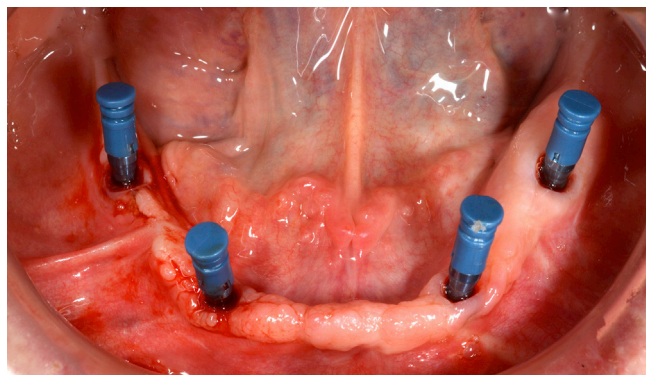


Fig. 1. Implants with transfers and copings in position ready for impression. The implants are placed at the position of canine and first molar, each side.

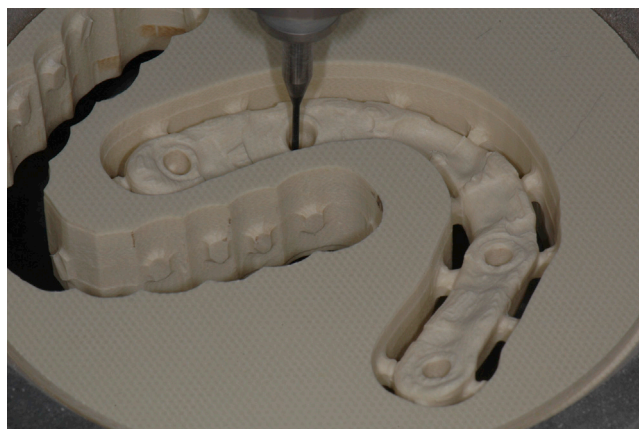

Fig. 3. Fiber-composit disk during milling process. After the digital design, the project is realized through a milling machine.

Download English Version:

<https://daneshyari.com/en/article/8706736>

Download Persian Version:

<https://daneshyari.com/article/8706736>

[Daneshyari.com](https://daneshyari.com)