Revista Odontológica Mexicana
Facultad de Odontología
Vol. 20, No. 4 ● October-December 2016
pp e252–e257
CASE REPORT

Giant pleomorphic adenoma of the palate. Case report and literature review

Adenoma pleomórfico gigante en paladar. Reporte de caso y revisión de la literatura

María Andrea Bordoy-Soto,* Henrique Jorge Vélez-Gimón,*
María Fernanda Hernández,* Wilmar Xavier-Briceño*

ABSTRACT

Pleomorphic adenoma is considered the most frequent benign tumor found in the salivary glands. Histologically it is characterized by presenting epithelial as well as mesenchymal elements. The present study targets the report of a clinical case of a large size pleomorphic adenoma found in a 45 year old patient. The patient was treated at the Oral and Maxillofacial Surgery Unit of the Eastern General Hospital «Dr. Domingo Luciani». The patient reported onset of the disease approximately 17 years before, with a progressive volume increase in the palate. A surgical Brown type II B maxillectomy was planned, with placement of a shutter plate. At a 10 month post-surgery control, tissue formation was observed in the region of the surgical bed, this formation exhibited similar appearance to the surrounding mucosa, with no signs of recurrence and presence of an oral-nasal fistula measuring approximately 2 cm in diameter. Presently, the patient is programmed to receive a fistula closure procedure by means of local flaps as well as subsequent prosthetic rehabilitation.

RESUMEN

El adenoma pleomórfico es considerado el tumor benigno más frecuente de las glándulas salivales y se caracteriza histológicamente por presentar tanto elementos epiteliales como mesenquimales. El presente estudio tiene como objetivo reportar un caso clínico de adenoma pleomórfico en paladar de grandes dimensiones de un paciente masculino de 45 años de edad, tratado en la Unidad de Cirugía Buco-Maxilofacial del Hospital General del Este «Dr. Domingo Luciani» quien inicia enfermedad actual, hace 17 años aproximadamente presentando un aumento de volumen progresivo en paladar. Se planificó quirúrgicamente para una maxilectomía de Brown tipo II B y colocación de placa obturadora. En un control postoperatorio de 10 meses se evidenció formación de tejido en la región del lecho quirúrgico de aspecto similar a la mucosa circundante sin señales de recidiva con presencia de fístula oro-nasal de aproximadamente 2 cm de diámetro. Actualmente se encuentra en programación de cierre de la misma con colgajos locales y posterior rehabilitación protésica.

Key words: Pleomorphic adenoma, benign mixed tumor, salivary gland tumor.
Palabras clave: Adenoma pleomórfico, tumor mixto benigno, tumor de glándulas salivales.

INTRODUCTION

Pleomorphic adenoma (PA) is considered the most frequent benign tumor of the salivary glands, representing 60% of all cases.[1-3] It is also known as mixed tumor, since it encompasses a wide mix of ductal and myoepithelial elements in one single tumor.[4] The term «pleomorphic» refers to the wide variability of the stromal and parenchymal differentiation shown by tumor cells.[2]

Approximately 80% of all PA develop in the parotid gland,[5] generally at the lower pole of the superficial lobe;[2,6] 10% appear at the submandibular gland, and 10% in minor salivary glands[5] in where the palate region represents 60%, followed by 20% in the upper lip and 10% in the oral mucosa.[4] The World Health Organization (WHO)[5] in 2005 reported that annual incidence of this lesion is from 2.4-3.05 per each 100,000 subjects, who are generally in their fourth and fifth decades of life,[1,2] with average age of 46 years.[5] From the clinical approach, PA appears as a painless, slow growing tumor, exhibiting firm consistency[7] and variable dimensions which

* «Dr. Domingo Luciani» General Hospital of the East, Caracas, Venezuela.

Received: December 2015. Accepted: March 2016.

See related content at doi:
http://dx.doi.org/10.1016/j.rodmex.2016.11.016

can fluctuate from 2 to 6 centimeters in diameter.[7,8] This type of tumor is generally associated to the superficial lobe of the parotid gland or the posterior palatal mucosa;[2,8] it is less frequently found in non-salivary glandular tissue of the external auditory meatus, breast tissue and tear duct.[1] In image studies taken with computerized tomography (CT), it generally appears as a circumscribed image with well-defined margins, with density similar to that of adjacent tissues and lacking homogeneous pattern.[1,9] In the parotid gland, it appears as an image with lobulated borders, differing from images taken from submandibular glands and minor salivary glands. The lesion's capsule is extremely difficult to detect as well as the resorption of adjoining bone.[9] In a magnetic resonance (MR) procedure, the lesion appears well circumscribed, of variable heterogeneity, being T1 or T2 depending on weight. The contrast between the lesion and surrounding tissue tends to be high in T1 (67%) and T2 (90%),[1,9] therefore, the capsule is very easy to detect in T2 weighing (87-90%) and hard to detect in T1 weighing (33%).[9] The lesion borders appear lobulated in the parotid gland and in the submandibular gland tumors, differing from tumors in the palate where smooth borders are normally found.[9]

With respect to microscopic characteristics, there is a wide spectrum of histological findings, due to the expression of variable epithelial and mesenchymal characteristics ; therefore giving rise to the term «pleomorphic».[1,4,5,10] PA appears as an encapsulated lesion when it develops in major salivary glands, differing from where it appears in minor salivary glands, where, normally, there is an incomplete capsule,[1,4,5] in most cases there are structures similar to a glove's finger which extend inward forming satellite nodules which are linked to the tumor by means of an isthmus.[5] Cells of epithelial origin result in ductal structures and are closely mixed with mesenchymal elements which might develop mixoid,[7] hyaline, cartilaginous or osseous changes.[1,5,10] Myoepithelial cells frequently represent a great percentage of tumor cells: they possess varied morphology, sometimes they appear in an angular or fusiform shape, in other instances they exhibit rounded shapes and show an eccentric nucleus with hyalinized eosinophilic cytoplasm resembling plasmatic cells.[4] These characteristic myoepithelial cells are predominant in tumors arising in minor salivary glands.[4]

Treatment of this type of lesions depends on their size and location, therefore, surgical excision is the preferred treatment.[1,3,4,5,7] Several authors[2,4,11] describe partial parotidectomy with identification and preservation of the facial nerve when treating PA located in the superficial lobe of the parotid gland. Conversely, total parotidectomy is necessary in tumors found in the deep lobe.[3,4]

Tumors of the hard palate are generally excised, including periosteum and adjacent mucosa.[3,4,7]

CLINICAL CASE PRESENTATION

A Caracas-born 45 year old male patient, attended the Oral and Maxillofacial Surgery Unit of the «Dr. Domingo Luciani» Eastern Hospital, complaining of a progressive volume increase in the palate; the lesion exhibited a 17 year evolution and the patient informed of dysphagia and dyspnea.

Physical examination revealed facial asymmetry at the expense of the facial middle third; with predominance in the right half of the face and presence of labial incompetence *(Figure 1)*. Endo-nasal exploration revealed total obstruction of both nasal fossae (nostrils) due to the presence of the tumor lesion.

Intraoral examination revealed bi-maxillary partial edentulism, poor oral hygiene with presence of multiple root remnants, and a tumor lesion measuring approximately 9 × 9 cm long, which appeared coated with a mucosa similar to the oral mucosa. The lesion exhibited smooth surface with vascular framework all over the lesion, and upon palpation was firm and

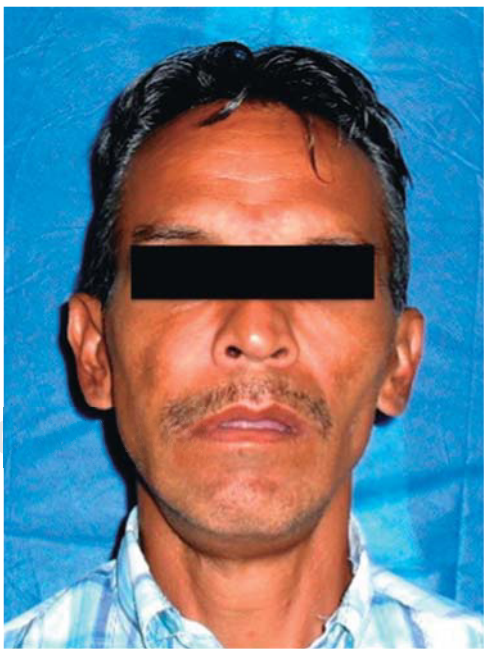

Figure 1. Frontal clinical photograph showing facial asymmetry, at the expense of the left half of the face, with presence of labial incompetence.