The Journal of Emergency Medicine, Vol. ■, No. ■, pp. 1–5, 2018
© 2018 Elsevier Inc. All rights reserved.
0736-4679/$ - see front matter

https://doi.org/10.1016/j.jemermed.2018.04.008

Clinical Communications: Adult

UNUSUAL ASPECT OF POSTERIOR REVERSIBLE ENCEPHALOPATHY SYNDROME IN AN ELDERLY ADULT

Benjamin Hebant, MD* and Omar Bennani, MD†

*Department of Neurology, Rouen University Hospital, France and †Department of Neurology, Le Havre General Hospital, Le Havre, France
Reprint Address: Benjamin Hebant, MD, Department of Neurology, Rouen University Hospital, 1 rue de Germont, Rouen 76031, France

☐ **Abstract—Background: Posterior reversible encephalopathy syndrome (PRES) classically occurs in patients presenting with a sudden increase of arterial pressure or eclampsia, but the range of etiologies is very wide. Although the mechanisms underlying PRES remain unclear, research suggests that when the extent of hypertension exceeds the threshold of cerebral blood flow autoregulation, this induces blood–brain barrier disruption that leads to brain edema. Unusual presentations on magnetic resonance imaging (MRI) are possible, including the involvement of frontal or temporal lobes, cerebellar hemispheres, basal ganglia, brainstem, or deep white matter. However, in these atypical locations, edema is mostly accompanied by the classical parieto-occipital region involvement. Case Report: We report the case of an elderly adult presenting with an unusual presentation of PRES with exclusive involvement of the frontal lobes, associated with severe hypertension. In our case, computed tomography and MRI abnormalities were exclusively localized in the frontal regions without involvement of the classical parieto-occipital regions. A favorable clinical course after hypertension management and complete clearance on an MRI scan at 3 months' follow-up confirmed the diagnosis. Why Should An Emergency Physician Be Aware of This?: PRES is a condition potentially encountered by many doctors, especially in the emergency department. However, atypical clinical or imaging presentations are possible and could delay the diagnosis. These must be known to begin adequate treatment as quickly as possible.** **© 2018 Elsevier Inc. All rights reserved.**

☐ **Keywords—elderly adult; hypertension; posterior reversible encephalopathy syndrome**

INTRODUCTION

Posterior reversible encephalopathy syndrome (PRES) was initially described in 1996 in patients presenting with sudden headache, altered mental functioning, seizures, and impaired vision associated with predominantly posterior leukoencephalopathy on imaging (1). PRES occurs classically in patients with a sudden increase of arterial pressure or eclampsia. However, the possible etiologies are numerous (2,3). Brain magnetic resonance imaging (MRI) is the cornerstone to confirm the diagnosis and rule out differential diagnoses. Indeed, vasogenic edema commonly involves the parieto-occipital region (98%). However, other locations are possible, but in these cases, edema is most of the time accompanied by the classical parieto-occipital region involvement (4,5). Diagnosis might be difficult, particularly when clinical or imaging presentation are unusual. MRI should be performed in emergency to confirm the diagnosis and rule out differential diagnoses. Partial or complete reversibility of these abnormalities on follow-up imaging performed after etiologic treatment is also important to reinforce the diagnosis (4). We report an elderly adult with an unusual presentation of PRES with exclusive involvement of the frontal lobes associated with severe hypertension. A favorable clinical course after hypertension management and complete clearance at 3 months' follow-up MRI confirmed the diagnosis.

Received: 20 September 2017; Final submission received: 1 January 2018;
Accepted: 10 April 2018

CASE REPORT

An 87-year-old man with a history of hypertension was referred to our emergency department for a generalized seizure followed by a postictal state. The initial examination revealed blood pressure (BP) of 215/80 mm Hg. The patient was in a coma (Glasgow Coma Scale score of 9). Brain computed tomography (CT) obtained in emergency showed a large area of edema involving the frontal lobes (Figure 1). Cerebrospinal fluid (CSF) examination showed no inflammation, and viral detection using polymerase chain reaction ruled out an infectious meningoencephalitis, in particular of herpetic origin. Intravenous antiepileptic treatment was introduced and acute hypertension was treated. The next day, an MRI scan of the brain was obtained that revealed bilateral frontal hyperintense signal on fluid-attenuated inversion recovery sequence (Figure 2A, B) without abnormalities on diffusion weighted imaging nor contrast enhancement after gadolinium injection. Clinical and imaging features suggested PRES. Antihypertensive medication was increased to achieve a BP goal <140/90 mm Hg. The clinical course was quickly favorable with full recovery after a few days. Three months later, brain MRI revealed a complete clearance of anterior abnormalities, confirming the diagnosis (Figure 2 C, D).

DISCUSSION

PRES is a condition that has been increasingly recognized after being initially described in 1996 (1). PRES occurs classically in patients with a sudden increase of arterial pressure or eclampsia. However, the possible etiologies are numerous, including autoimmune or inflammatory diseases, systemic inflammatory response syndrome, sepsis, renal failure, use of chemotherapy agents, vasoactive drugs, or monoclonal antibodies (2,3). In most cases, neurologic symptoms occur acutely or subacutely. Classical clinical features include encephalopathy in about 50–80% of cases (mild confusion to deep stupor) and generalized tonic–clonic seizures (60–75% of patients). Status epilepticus is much less common (5–15%). Headache is present in 50% of cases (diffuse and gradual in onset) and visual disturbance (such as decreased visual acuity, visual field deficits, cortical blindness or hallucinations) in 33%. Focal symptoms, such as hemiparesis or aphasia, can occur in 10–15% of patients. The combination of several symptoms is suggestive of the diagnosis (3,6–8). Although the physiopathologic mechanisms underlying PRES remain unclear, studies suggest that when the pressure rise is rapid and severe, cerebral blood flow autoregulation is exceeded, causing hyperperfusion and blood–brain barrier disruption and inducing interstitial extravasation of plasma and macromolecules (3). The posterior brain regions are particularly susceptible to hyperperfusion because of the little sympathetic innervation of the posterior fossa (3). However, PRES can also occur in normotensive or hypotensive patients, particularly in cases of eclampsia or toxic etiology. Indeed, in some patients, the extent of hypertension does not exceed the typical autoregulation range. In these cases,

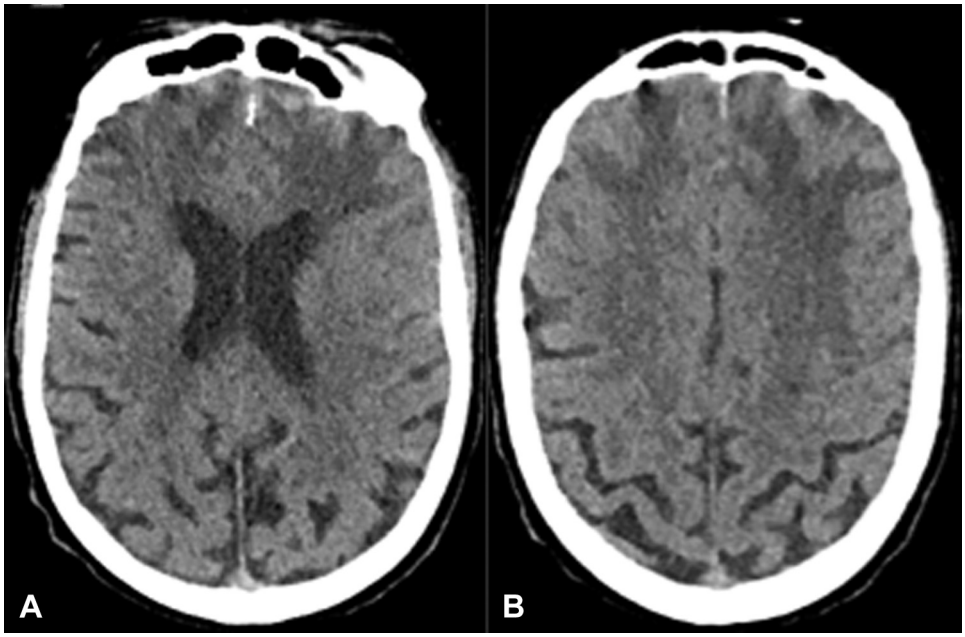

Figure 1. (A and B) Computed tomography scan of the brain obtained in the emergency department showed a large area of edema involving the frontal lobes.

Download English Version:

https://daneshyari.com/en/article/8719392

Download Persian Version:

https://daneshyari.com/article/8719392

Daneshyari.com