

Gastroenterology

www.gastrojournal.org

Vol. 153, No. 6

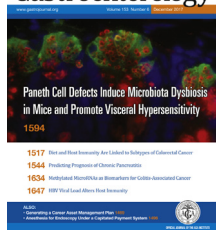
December 2017

Contents

ON THE COVER

Gastroenterology

See article by Riba et al, on page 1594 for further information.



COVERING THE COVER

1457 A. T. Chan and C. S. Williams

COMMENTARIES

1460 Will Computer-Aided Detection and Diagnosis Revolutionize Colonoscopy?



M. F. Byrne, N. Shahidi, and D. K. Rex

1465 Repeal and Replace? Repair or Despair? 2017 Health Care Reform and Clinical Gastroenterology

S. D. Dorn

MEETING SUMMARY

e1 AAA IBD 2017: Methodologies to Collect and Analyze Clinical Data to Support Quality Improvement Initiatives Designed to Optimize the Care of Patients With IBD

A. K. Waljee, Y. Yang, and G. D. Wu

MENTORING, EDUCATION, AND TRAINING CORNER

1469 "Spending Your Life Wisely": How to Create an Asset Management Plan

M. A. Adams and J. I. Allen

EDITORIALS

1473 Enteric Glia: The Origin of Duodenal Gastrinomas?

B. D. Gulbransen

See Sundaresan S et al on page 1555.



Video



Related article in CGH



CME quiz



Editorial accompanies this article



Additional online content available



Cover

- 1475 Human Intestinal Microbiota and Colorectal Cancer: Moving Beyond Associative Studies**
C. Jobin
See Liu X et al on page 1607 and Wong SH et al on page 1621.
- 1479 Smoking and Drinking Synergize in Pancreatitis: Multiple Hits on Multiple Targets**
M. Sahin-Tóth and P. Hegyi
See Lugea A et al on page 1674.

CLINICAL CHALLENGES AND IMAGES IN GI

- 1482 Striking Finding on Colonoscopy: Is This a Watermelon Colon?**
R. Mandaliya, T. Choden, and A. Thomas
- 1484 Not Your Ordinary Ulcer: A Cautionary Tale of an Uncommon Condition**
H. H. Nguyen and P. L. Beck
- 1486 An Unusual Finding During Evaluation of Iron Deficiency**
A. Rubio-Tapia, I. A. Hujoel, and T.-T. Wu
- 1488 Periduodenal Mass: A Rare Diagnosis Confirmed by Endoscopic Ultrasound–Guided Fine-Needle Aspiration**
Y. Tomizawa, G. H. Yu, and M. L. Kochman

ELECTRONIC CLINICAL CHALLENGES AND IMAGES IN GI


For a full list, please see the table of contents online at www.gastrojournal.org.

PRACTICAL TEACHING CASE

- 1490 A Rare Cause of Diarrhea and Polyposis**
 *N. J. Samadder, J. F. Valentine, and K. Affolter*

ORIGINAL RESEARCH



Brief Report

- 1492 Association of Aneuploidy and Flat Dysplasia With Development of High-Grade Dysplasia or Colorectal Cancer in Patients With Inflammatory Bowel Disease**
 *J.-H. Tsai, P. S. Rabinovitch, D. Huang, T. Small, A. N. Mattis, S. Kakar, and W.-T. Choi*

Aneuploidy is frequently detected in flat dysplastic lesions in patients with inflammatory bowel disease. This study reveals a significant association between aneuploidy and low-grade dysplasia in conjunction with the subsequent detection of high-grade dysplasia or colorectal cancer.

Full Reports

Clinical—Alimentary Tract

- 1496 Predictors of Use of Monitored Anesthesia Care for Outpatient Gastrointestinal Endoscopy in a Capitated Payment System**
  *M. A. Adams, K. M. Prenovost, J. A. Dominitz, R. G. Holleman, E. A. Kerr, S. L. Krein, S. D. Saini, and J. H. Rubenstein*

The use of monitored anesthesia care (MAC) has doubled in the VA system in the last decade, and is only weakly associated with clinically relevant patient-related factors. This suggests that addressing financial incentives may not be enough to facilitate high-value use of this costly resource outside the VA.

Download English Version:

<https://daneshyari.com/en/article/8727330>

Download Persian Version:

<https://daneshyari.com/article/8727330>

[Daneshyari.com](https://daneshyari.com)