IDCases 13 (2018) e00437

Contents lists available at ScienceDirect

IDCases

journal homepage: www.elsevier.com/locate/idcr

Case report

Occam's razor need not apply: Advanced HIV infection presenting with five simultaneous opportunistic infections and central nervous system lymphoma

Louis-Bassett Porter[a,1], Elena Kozakewich[a,1], Ryan Clouser[b], Colleen Kershaw[c], Andrew J. Hale[b,*]

[a] The University of Vermont Medical Center, United States
[b] The University of Vermont Medical Center, Larner College of Medicine at the University of Vermont, Burlington, VT, United States
[c] Beth Israel Deaconess Medical Center, Boston, MA, United States

ARTICLE INFO

Article history:
Received 18 June 2018
Received in revised form 6 August 2018
Accepted 6 August 2018

Keywords:
Human Immunodeficiency Virus
Acquired Immunodeficiency Disorder
Opportunistic infection

ABSTRACT

Patients with Human Immunodeficiency Virus (HIV) infection and Acquired Immunodeficiency Syndrome (AIDS) are at risk for multiple infectious and oncologic complications. In such cases, Occam's razor need not apply: multiple infections and malignancies are often present concurrently upon presentation to care. A patient off anti-retroviral therapy (ART) for several years developed advanced HIV infection (CD4 count 19 cells/uL) and presented with five simultaneous opportunistic infections including *Pneumocystis jiroveci* pneumonia (PJP), cytomegalovirus (CMV) retinitis, *Mycobacterium avium* complex (MAC) bloodstream infection, chronic hepatitis B virus (HBV), and Epstein-Barr virus (EBV) viremia. Simultaneously, he was found to have primary central nervous system (CNS) B-cell lymphoma.

Treatment decisions for such patients are often complex, as ideal therapy for one disease may directly counter or interact with therapy for another. For instance, methotrexate for primary CNS lymphoma and trimethoprim/sulfamethoxazole for PJP is a strictly contraindicated medication combination. It is important to understand not just the management of any single opportunistic disease in patients with advanced HIV, but how to balance management for patients with a variety of concurrent processes. In an era when HIV care is becoming increasingly simplified, patients presenting with advanced infection highlight the lack of data on how best to manage patients with multiple concurrent disease processes. Significant further research is needed to clarify ideal comparative therapy.

Introduction

For many clinicians practicing in the United States, especially young clinicians, treatment of the manifestations of untreated HIV with progression to AIDS may be evocative of a past era of medicine that seems disconnected from the present-day. While HIV and AIDS are recognized as major issues pertaining to global health, prevalence in the United States is perceived to be much lower. However, the Centers for Disease Control and Prevention (CDC) estimate that in 2014 over 1.1 million people in the United States were living with HIV, with 15% of those patients (approximately 165,000) unaware of their HIV-positive status. Furthermore, in 2014 HIV was the eighth leading cause of death in 25–34 year-olds and ninth in 35–44 year-olds in the United States [1]. The reality is that despite significant strides in HIV prevention and antiretroviral therapy, HIV, AIDS and associated opportunistic infections remain fundamentally important topics in clinical practice in the United States.

Case description

A 56-year-old man was found by his spouse unresponsive and demonstrating generalized tonic-clonic movements with bowel and bladder incontinence. Emergency medical services were called and he was intubated for airway protection. Preceding this event, the patient had reported upper respiratory illness symptoms for several weeks with intermittent fevers, as well as altered mental status described as slowed cognition and unusual affect. He took no medications prior to admission, though did have a history of

* Corresponding author at: University of Vermont Medical Center, Infectious Disease Unit. 111 Colchester Avenue, Mailstop 115 SM2., Burlington, VT, 05401, United States.
E-mail address: Andrew.Hale@UVMhealth.org (A.J. Hale).

[1] Dr. Porter and Dr. Kozakewich contributed equally to this manuscript.

https://doi.org/10.1016/j.idcr.2018.e00437

chronic HBV and HIV acquired in the 1980s, thought to be from MSM exposure. He had previously taken HIV and HBV medications for nearly 20 years, but had discontinued all medical therapy three years prior to admission due to side effects. His CD4 T-cell count at the time of discontinuation was 250 cells/μL.

On admission the patient's temperature was 38 °C, heart rate was 127 beats per minute, respiratory rate was 12 breaths per minute, blood pressure was 122/83 mmHg, and blood oxygen saturation was 100% on FiO2 30%. He was cachectic on examination. Lungs were clear to auscultation bilaterally. Notable initial laboratory values included a serum sodium of 114 mEq/L, lactic acid of 7.5 mmol/L, creatinine kinase of 1292 U/L, hemoglobin of 12.0 gm/dl, white blood cell count of 5.8 K/μL, and platelets of 143 K/μL. Absolute CD4 T-cell count was 19 cells/uL and HIV viral load was 468,999 copies/mL. A computed tomography scan of the head revealed a right basal ganglia edematous area measuring 20 × 24 mm, with mild mass effect. A brain magnetic resonance imaging study with gadolinium showed a rim-enhancing lesion involving the right caudate and basal ganglia with mass effect indenting the right lateral ventricle (Fig. 1). Lumbar puncture revealed atypical lymphocytes with cytopathology consistent with B-cell lymphoma. The patient's respiratory status improved and he was liberated from mechanical ventilation the day following admission, though remained somnolent afterwards.

Further work-up revealed positive hepatitis B surface antigen with HBV viral load 8.23 log IU/mL, *Mycobacterium avium* complex (MAC) growth in blood cultures, positive Epstein-Barr virus (EBV) polymerase chain reaction (PCR) in cerebrospinal fluid, and serum cytomegalovirus (CMV) viral load of 2770 IU/mL with findings on funduscopic exam of creamy exudates with associated dot-blot hemorrhages, consistent with CMV retinitis. Video electroencephalogram monitoring did not record further seizure activity. Positron emission tomography (PET) showed strong fludeoxyglucose (FDG) avidity primarily within the CNS lesion, consistent with HIV-associated primary CNS B-cell lymphoma (Fig. 2). Diffuse, though weak, FDG avidity was also noted in the lungs which prompted a subsequent bronchoalveolar lavage, which demonstrated *Pneumocystis jiroveci* pneumonia (PJP) via PCR. Thus, this patient's presentation was ultimately consistent with advanced HIV infection with CD4 count of 19 cells/uL, chronic HBV, HIV and EBV-associated primary CNS B-cell lymphoma, PJP, CMV retinitis, and MAC bloodstream infection.

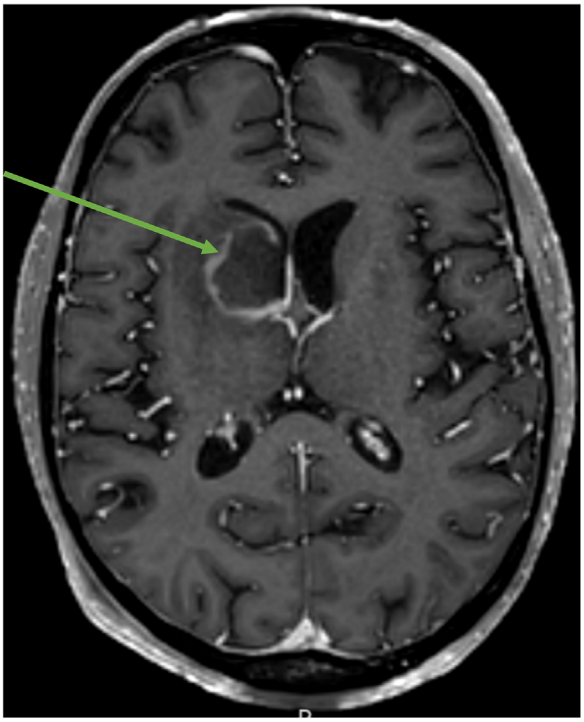

Fig. 1. Brain magnetic resonance imaging study with contrast demonstrates a single rim-enhancing lesion (green arrow) involving the right caudate and basal ganglia with mass effect indenting the right lateral ventricle. Lumbar puncture cytology demonstrated B-cell lymphoma.

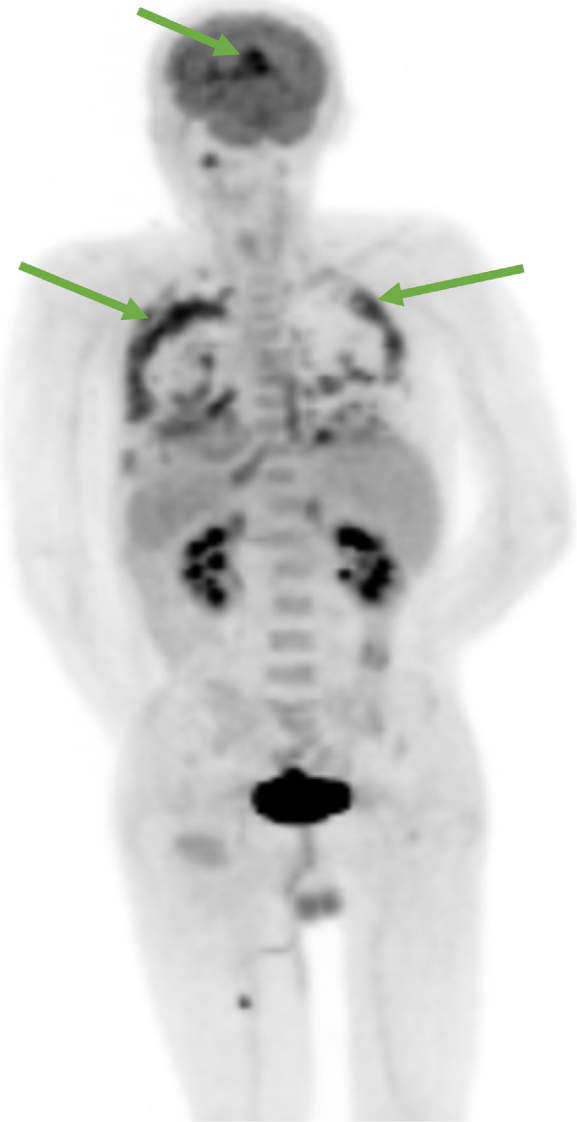

Fig. 2. Positron emission tomography study. Note the high fludeoxyglucose (FDG) avidity within the central nervous system lesion as well as uptake within lungs bilaterally (green arrows). Lumbar puncture cytology confirmed the solitary CNS lesion as HIV-associated primary CNS B-cell lymphoma, and bronchoscopy confirmed the pulmonary findings as *Pneumocystis jirovecii* pneumonia (PJP).

Initially, trimethoprim/sulfamethoxazole was started for treatment of PJP and was transitioned to atovaquone due to concern for interaction with methotrexate (planned therapy for primary B-cell lymphoma), unknown glucose-6-dehydrogenase deficiency (G6PD) status, and minimal hypoxia post-extubation. However, methotrexate was later deferred due to the patient's multiple comorbidities. CMV retinitis was initially treated with intravenous ganciclovir, though with developing marrow suppression he was transitioned to intravitreal ganciclovir injection. Anti-retroviral therapy and anti-HBV medications were initiated after seven days of CMV therapy, including tenofovir alafenamide, emtricitabine,