Auris Nasus Larynx xxx (2017) xxx–xxx

Contents lists available at ScienceDirect

Auris Nasus Larynx

journal homepage: www.elsevier.com/locate/anl

Case report

Undifferentiated sarcoma of the sphenoid sinus

Masaya Nagaishi *, Kensuke Suzuki, Yoshiki Sugiura, Issei Takano, Yoshihiro Tanaka, Akio Hyodo

Department of Neurosurgery, Dokkyo Medical University Koshigaya Hospital, 2-1-50 Minami-Koshigaya, Koshigaya-shi, Saitama 343-8555, Japan

ARTICLE INFO

Article history:
Received 3 February 2017
Accepted 29 May 2017
Available online xxx

Keywords:
Carbon-ion radiotherapy
Paranasal tumor
Sarcoma
Skull base
Undifferentiated tumor

ABSTRACT

Paranasal sinuses sarcomas are rare and no treatments have been established. We report a young-adult case of sphenoid sinus sarcoma treated by carbon-ion radiotherapy. The patient presented with progressive left-sided visual impairment. A tumor was then identified and partial resection by transnasal approach was performed. The resected mass showed typical morphology of mesenchymal tumor, and morphological and molecular analyses ruled out a predominant-differentiation phenotype. The pathological diagnosis was undifferentiated sarcoma. The residual lesion was treated with carbon-ion radiotherapy, and tumor progression was absent for one year. The patient died of the tumor regrowth 20 months after initial diagnosis. Although this case had a poorer outcome compared with cases of the more-common sarcoma types, our experience suggested that carbon-ion radiotherapy is potentially beneficial in unresectable undifferentiated sarcomas cases of sphenoid sinus.

© 2017 Elsevier B.V. All rights reserved.

1. Introduction

Paranasal sinus and sella turcica sarcomas are rare, and sphenoid sinus tumors comprise approximately 1%–2% of all paranasal sinus tumors [1–3]. Sarcomas are mesenchymal neoplasms commonly originating from lymphoid, muscular, fibrous, bony, or cartilaginous tissues, and comprise only 1% of head and neck tumors [4]. Common head and neck sarcomas include osteosarcomas, angiosarcomas, rhabdomyosarcomas, malignant fibrous histiocytomas, and fibrosarcomas [5–7]. Although head and neck sarcomas, especially bone and cartilage tumors, commonly show skull-base involvement, sphenoid-sinus involvement is rare [5,8–11]. Moreover, few reports of undifferentiated sphenoid sinus sarcomas exist.

Distant metastasis is rare in sarcomas, and the clinical symptoms, treatment, and outcomes are strongly related to surrounding structures of the primary site. Complete resection is reportedly the only good prognostic factor independent of tumor grade, and local recurrence is the most frequent cause of treatment failure [7,12]. The sphenoid sinus is close to vital structures, including cranial nerves, the pituitary gland, and vital blood vessels; thus, tumors of the sphenoid sinus pose surgical challenges. Although no established standard adjuvant treatments exist, several studies report potential benefits of carbon-ion radiotherapy for residual tumors of sarcomas which our patient opted for due to the desire to father a child. Herein, we report a young-adult case of undifferentiated sarcoma of the sphenoid sinus treated first by partial resection followed by carbon-ion radiotherapy.

2. Case report

2.1. Case history

A 29-year-old man presented to the neurological service with a one-month history of progressive left-sided visual

* Corresponding author. Fax: +81 48 965 8682.
E-mail address: nagaishi-nsu@umin.ac.jp (M. Nagaishi).

http://dx.doi.org/10.1016/j.anl.2017.05.018
0385-8146/© 2017 Elsevier B.V. All rights reserved.

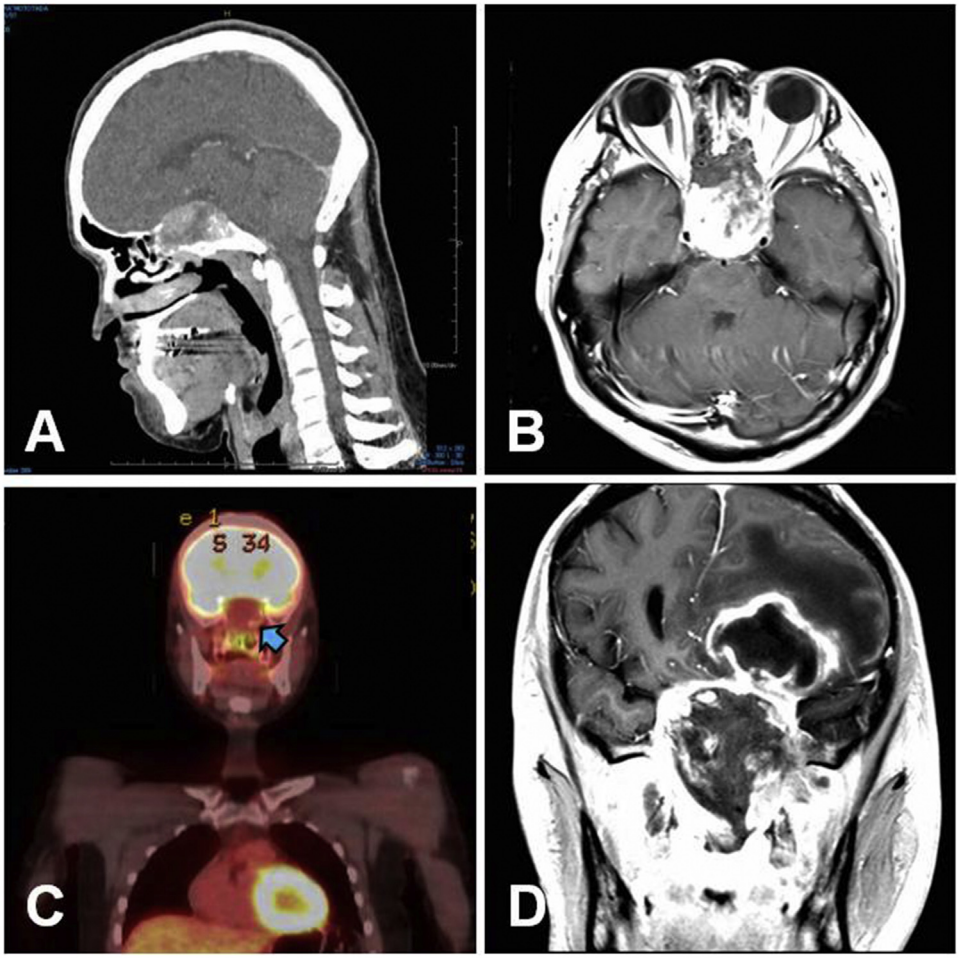

Fig. 1. Sagittal computed tomography with bone window showing widespread osteolysis of the middle skull base associated with a mass (A). Preoperative and gadolinium (Gd)-enhanced magnetic resonance imaging (MRI) demonstrating a heterogeneously enhancing mass in the sphenoid sinus and sella turcica (B). After radiotherapy, positron emission tomography demonstrating lower fluorodeoxyglucose (18F) uptake in the residual lesion (C, arrow). Gd-enhanced MRI at 12 months after surgery showing local tumor progression and a left-frontal-lobe abscess (D).

impairment and nasal snuffle. Physical examination confirmed severe left-sided visual acuity deterioration, and fundoscopy revealed ipsilateral papilledema. There were no other symptoms and objective signs. Computed tomography showed osteolysis involving the sellar floor, clivus, and clinoid processes, with a large (>4-cm maximal diameter) isodense mass filling the sella and paranasal sinuses (Fig. 1A). The mass was hypointense on T1- and T2-weighted magnetic resonance imaging, and was heterogeneously enhanced by gadolinium (Fig. 1B). The mass was located mainly in the sphenoid sinus and the sella turcica, extending into bilateral optic canals and cavernous sinuses. The compressed pituitary gland was displaced posterosuperiorly in the sella turcica. Laboratory tests revealed mildly increased triglycerides and HbA1c with normal pituitary hormone levels. These findings suggested the difficulty of total tumor removal and subsequent reconstruction of the skull base defect. He underwent surgery with suspected poorly differentiated squamous cell carcinomas, adenocarcinomas, neuroblastomas, sarcomas, or nasal-type natural killer (NK)/T-cell lymphoma, and the tumor was partially resected via a transnasal approach to temporarily release the compression on the optic nerve. Surgical decompression improved left-sided visual acuity deterioration. Postoperatively, the residual tumor was treated with carbon-ion radiotherapy using 16 fractions (total dose 64 Gy). Rapid tumor growth and progression was inhibited after radiotherapy, the patient was able to return to work with persistent visual disturbance 2 months after surgery. Contrast enhancements were temporarily attenuated, and the tumor center showed lower fluorodeoxyglucose (18F) uptake than the tumor periphery on positron emission tomography after radiotherapy (Fig. 1C). Local tumor regrowth was observed 12 months after radiotherapy, which was subsequently complicated by a left-frontal-lobe abscess (Fig. 1D). He became blind and was readmitted to the hospital 17 months after initial diagnosis. The brain abscess appeared to progress while the patient was receiving antibiotic therapy, and caused disturbance of consciousness. The tumor filled the nasal cavity and extended to the pharynx. The patient died of respiratory failure due to the disturbance of consciousness and the airway narrowing by tumor 20 months after initial diagnosis.

Please cite this article in press as: Nagaishi M, et al. Undifferentiated sarcoma of the sphenoid sinus. Auris Nasus Larynx (2017), http://dx.doi.org/10.1016/j.anl.2017.05.018

Download English Version:

https://daneshyari.com/en/article/8754827

Download Persian Version:

https://daneshyari.com/article/8754827

Daneshyari.com