ARTICLE IN PRESS

Journal of Taibah University Medical Sciences (2017) ■(■), 1–6

Taibah University

Journal of Taibah University Medical Sciences

www.sciencedirect.com

Case Report

Endovascular suction thrombectomy for severe cerebral venous sinus thrombosis: A report of two cases

Ahmed A. Najjar, MD [a], Jameel K. Rasheedi, MD [b], Khalil I. Kurdi, MD [c], Ahmed A. Hasan, MD [d], Mohammed A. Almekhlafi, FRCPC [b] and Saleh S. Baeesa, FRCSC [a,*]

[a] *Division of Neurosurgery, Faculty of Medicine, King Abdulaziz University, Jeddah, KSA*
[b] *Division of Neurology, Faculty of Medicine, King Abdulaziz University, Jeddah, KSA*
[c] *Department of Radiology, King Faisal Specialist Hospital and Research Centre, Jeddah, KSA*
[d] *Department of Neurosciences, King Faisal Specialist Hospital and Research Centre, Jeddah, KSA*

Received 13 January 2017; revised 16 June 2017; accepted 29 June 2017; Available online ■ ■ ■

الملخص

تخثر الجيوب الوريدية الدماغية هي حالة سريرية خطيرة، تتظاهر بأعراض مختلفة، يمكن أن تكون خفيفة على شكل صداع، أو يمكن أن تكون مهددة للحياة مع ارتفاع الضغط والفتق داخل الجمجمة. وحتى مع العلاج الوريدي بمضادات تخثر الدم، لا يزال تخثر الجيوب الوريدية الدماغية يحمل خطر الوفاة عند حوالي ١٠٪ بسبب فشل إعادة استقناء الوريد بمضادات التخثر لوحدها. نعرض هنا حالتين لتخثر واسع للجيوب الوريدية الدماغية، وعلى الرغم من العلاج الوريدي بمضادات تخثر الدم تدهورت حالتهما العصبية تدريجيا. عولج المريضان بنجاح بإزالة الجلطة من داخل الأوعية الدموية باستخدام تقنيات استئصال الخثرة بالشفط مع إعادة فورية لتروية الجيوب الوريدية وسرعة التحسن الشعاعي. العلاج الموصوف يبدو فاعلا وآمنا، ولكن هناك حاجة لدراسات أخرى للتحقق من فاعلية هذا العلاج.

الكلمات المفتاحية: منع تخثر الدم؛ تخثر الجيوب الوريدية الدماغية؛ داخل الأوعية الدموية؛ استئصال الخثرة؛ تحلل الجلطة؛ النتيجة

Abstract

Cerebral venous sinus thrombosis (CVST) is a severe clinical condition that manifests with diverse symptoms that can be mild, taking the form of a headache, or can be life-threatening, with raised intracranial pressure and herniation. Despite systemic anticoagulation treatment, CVST still carries a mortality risk of approximately 10% because of the failure of venous recanalization by anticoagulants alone. This paper describes two cases with extensive CVST who presented with progressive neurological deterioration despite adequate systemic anticoagulation treatment. Both patients were successfully treated with endovascular clot removal using suction thrombectomy techniques with immediate recanalization of the sinuses and rapid radiographic improvement. The described therapy appears effective and safe; however, further studies are needed to validate the effectiveness of this treatment.

Keywords: Anticoagulation; Cerebral venous sinus thrombosis; Endovascular; Outcome; Thrombectomy; Thrombolysis

© 2017 The Authors.
Production and hosting by Elsevier Ltd on behalf of Taibah University. This is an open access article under the CC BY-NC-ND license (http://creativecommons.org/licenses/by-nc-nd/4.0/).

Introduction

Traditionally, cerebral venous sinus thrombosis (CVST), previously considered a rare diagnosis, is increasingly detected owing to the advent of modern imaging techniques.[1] The treatment for this potentially fatal condition has largely been anticoagulation. However, in few refractory cases or those with contraindication to anticoagulation, endovascular thrombolysis has been used in experienced centres.

* Corresponding address: Department of Neurosurgery, Faculty of Medicine, King Abdulaziz University, P.O. Box 80215, Jeddah 21589, KSA.
E-mail: sbaeesa@kau.edu.sa (S.S. Baeesa)

Peer review under responsibility of Taibah University.

ELSEVIER Production and hosting by Elsevier

1658-3612 © 2017 The Authors.
Production and hosting by Elsevier Ltd on behalf of Taibah University. This is an open access article under the CC BY-NC-ND license (http://creativecommons.org/licenses/by-nc-nd/4.0/). http://dx.doi.org/10.1016/j.jtumed.2017.06.004

Please cite this article in press as: Najjar AA, et al., Endovascular suction thrombectomy for severe cerebral venous sinus thrombosis: A report of two cases, Journal of Taibah University Medical Sciences (2017), http://dx.doi.org/10.1016/j.jtumed.2017.06.004

Approved by the Food and Drug Administration since 2006, the Penumbra Stroke system, a clot retrieval technology, has been used for the revascularization of patients with acute ischaemic stroke.[2] Its use in the management of cerebral sinus thrombosis is limited to tertiary care centres.

We report 2 cases with CVST successfully treated using manually aspiration thrombectomy using the Penumbra System and resulting in rapid radiographic improvement associated with a complete clinical recovery.

Case reports

Case 1

A 32-year-old female, not known to have a chronic medical illness, presented with a thunderclap headache and progressive deterioration of her level of consciousness. She was not pregnant or on birth control pills and was not known to have a hypercoagulable state. There was no history of trauma or family history of coagulation disorders. When she was first evaluated at another hospital, her Glasgow coma scale (GCS) was 12/15, and she was vitally stable. A computed tomography (CT) scan of the brain revealed diffuse oedema, and a magnetic resonance imaging (MRI) scan showed tiny multiple infarctions in the subcortical frontal lobes bilaterally with extensive thrombosis involving the superior sagittal, left sigmoid, and left transverse sinuses. She was started immediately on intravenous heparin therapy with adequate therapeutic anticoagulation monitoring for three days without improvement. The patient was then referred to our hospital for interventional therapy. Upon admission, she was unconscious with a GCS of 8, and her vital signs were stable. A general physical examination was unremarkable, and her cranial nerves examination was within normal, apart from sluggish pupillary reaction to light and bilateral papilloedema. She had mild withdrawal to painful stimuli on the right side more than the left, and her deep tendon reflexes were exaggerated. Her routine laboratory tests were within normal with the therapeutic heparin effect. Specific haematological and serological tests for an underlying thrombophilia were all within normal limits. The patient was intubated and stabilized, and a repeat brain MRI scan demonstrated diffuse persistent cerebral venous sinus thrombosis (Figure 1A). Magnetic resonance venogram (MRV) scans demonstrated the extensive thrombosis of the sagittal, left transverse and sigmoid sinuses (Figure 1B). The patient was taken to the angiography suite, and cerebral angiography showed an occlusion of the posterior part of the superior sagittal sinus (Figure 2A, B). A 6-French Neuron guide catheter (Penumbra, Alameda, California, USA) was carefully placed into the right transverse sinus, and a 0.41-inch Penumbra thrombectomy catheter was introduced into the occluded sinuses. Thrombolysis using a total of 10 mg of recombinant tissue plasminogen activator (r-TPA) in conjunction with the aspiration of the thrombus was successfully performed over a total of 23 min. The cerebral venogram showed complete reopening of the sinuses (Figure 2C). Within 24 h after endovascular therapy, her level of consciousness almost reached a GCS of 14, and she was extubated. She was discharged home after five days with mild left hemiparesis and continued oral warfarin 4 mg daily with adequate therapeutic anticoagulation monitoring. At the 3-month outpatient follow-up, the residual neurological deficit was completely recovered, and brain MRI and MRV scans showed a significant recanalization of the thrombosed sinuses (Figure 3).

Case 2

A 35-year old female patient, a known case of sickle cell anaemia, presented with a history of gradual onset headache for a duration of approximately 3 weeks that grew worse and reached maximal intensity on the day of her presentation to the emergency room. It was associated with photophobia, vomiting, dizziness and blurry vision. The patient complained of right-sided weakness and an inability to walk without assistance that started on the day of her presentation. There was no history of fever or any other signs or symptoms suggestive of infectious focus. She was non-smoking with no history of using oral contraceptives, and her last blood transfusion was 20 years ago.

In the emergency room, she was lethargic and tachycardic; she had a heart rate of 109 bpm, with blood pressure of 156/88 but afebrile. She was initially communicating and opening her eyes spontaneously with right gaze preference. She then deteriorated clinically, and her GCS dropped to 9/15, opening her eyes to painful stimuli only, with no vocal response and localize to pain as the best motor response,

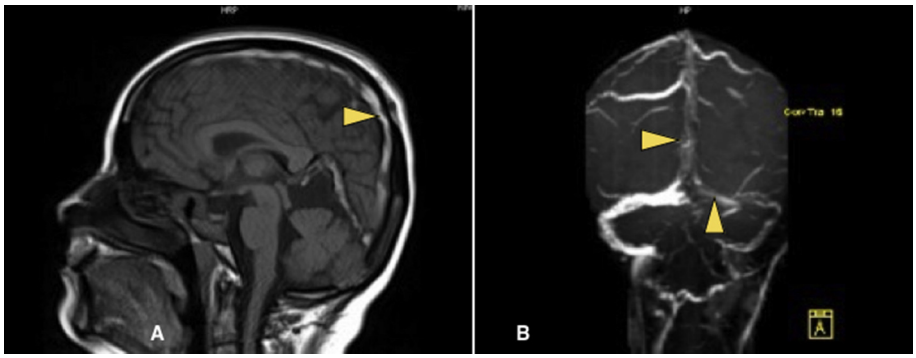

Figure 1: Sagittal T1-MRI (A) and MRV (B) scans demonstrating extensive filling defects in the superior sagittal and left transverse sinuses (arrowheads).

Please cite this article in press as: Najjar AA, et al., Endovascular suction thrombectomy for severe cerebral venous sinus thrombosis: A report of two cases, Journal of Taibah University Medical Sciences (2017), http://dx.doi.org/10.1016/j.jtumed.2017.06.004

Download English Version:

https://daneshyari.com/en/article/8759442

Download Persian Version:

https://daneshyari.com/article/8759442

Daneshyari.com