The Breast xxx (2016) 1–7

Contents lists available at ScienceDirect

The Breast

journal homepage: www.elsevier.com/brst

Original article

Radial scars diagnosed on breast core biopsy: Frequency of atypia and carcinoma on excision and implications for management

Alana R. Donaldson [a], Leah Sieck [b], Christine N. Booth [a], Benjamin C. Calhoun [a, *]

[a] Robert J. Tomsich Pathology and Laboratory Medicine Institute, Department of Pathology, Cleveland Clinic, Cleveland, OH, USA
[b] Imaging Institute, Department of Breast Imaging, Cleveland Clinic, Cleveland, OH, USA

ARTICLE INFO

Article history:
Received 22 March 2016
Received in revised form
3 June 2016
Accepted 4 June 2016
Available online xxx

Keywords:
Breast
Screening
Diagnosis
Core biopsy
Radial scar
Pathology

ABSTRACT

Aims: The risk of finding carcinoma in excisions following a core needle biopsy diagnosis of radial scar is not well defined and clinical management is variable.
The aim of this study is to determine the frequency of high-risk lesions, ductal carcinoma in situ, and invasive carcinoma in excisions following a core biopsy diagnosis of radial scar.
Methods and results: Dedicated breast pathologists and radiologists correlated the histologic and radiologic findings and categorized radial scars as the target lesion or an incidental finding. High-risk lesions were defined as atypical hyperplasia or classical lobular carcinoma in situ.
Of the 79 radial scars identified over a 14-year period, 22 were associated with atypia or carcinoma in the core biopsy. Thirty-seven (37) of the 57 benign radial scars underwent excision with benign findings in 30 (81%), high-risk lesions in six (16%), and flat epithelial atypia in one (3%). There were no upgrades to carcinoma. One patient with a benign radial scar developed a 3-mm focus of intermediate-grade estrogen receptor-positive ductal carcinoma in situ in the same quadrant of the ipsilateral breast 72 months after excision. One patient with an incidental un-excised benign radial scar was diagnosed with ductal carcinoma in situ at a separate site of suspicious calcifications.
Conclusions: In this series, none of the benign radial scars was upgraded to carcinoma. Radial scar was the targeted lesion in all cases with high-risk lesions on excision. Surgical excision may not be mandatory for patients with benign incidental radial scars on core biopsy.
© 2016 Elsevier Ltd. All rights reserved.

Introduction

Radial scars of the breast are uncommon findings in breast biopsies and are characterized by a central focus of fibroelastotic stroma with adenotic epithelial elements radiating outward [1]. The stellate appearance of radial scars may mimic carcinoma mammographically and histologically [2,3]. Some early studies suggested that radial scars were more common in women with breast cancer [4], while subsequent studies found no significant difference in the frequency of radial scars in women with and without breast cancer [5,6]. The observation that radial scars may contain carcinoma also suggested a relationship between radial scars and breast cancer [7–10].

An initial report from the Nurses' Health Study provided evidence that radial scars were an independent risk factor for the development of carcinoma [11]. Subsequent studies from the Nashville (Sanders et al. [12]) and Mayo cohorts (Berg et al. [13]) failed to confirm this finding. In an updated analysis of the Nurses' Health Study, the risk associated with radial scars in proliferative disease categories was attenuated but remained statistically significant [14]. In the Nashville cohort, the risk of developing invasive carcinoma after a diagnosis of radial scars was 3.4% in the first 10 years, compared with 1.6% for patients without a radial scar [12].

The long-term follow-up studies of the Nashville cohort, the Mayo cohort, and the Nurse's Health Study included patients with open biopsies, many of which were performed in the pre-mammographic era. With the widespread use of percutaneous core needle biopsy (CNB) of the breast, attention has shifted to the risk of finding carcinoma in an excision specimen following a core biopsy diagnosis of radial scar. Studies correlating core biopsy

* Corresponding author. Robert J. Tomsich Pathology and Laboratory Medicine Institute, Department of Pathology, Cleveland Clinic, 9500 Euclid Avenue, Mail Code L25, Cleveland, OH 44195, USA. Tel.: +1 (216) 636 9914; fax: +1 (216) 445 3707.
E-mail addresses: donalda@ccf.org (A.R. Donaldson), sieckl@ccf.org (L. Sieck), boothc1@ccf.org (C.N. Booth), calhoub@ccf.org (B.C. Calhoun).

http://dx.doi.org/10.1016/j.breast.2016.06.007
0960-9776/© 2016 Elsevier Ltd. All rights reserved.

diagnoses of radial scar with final pathology after surgery have shown variable results with the frequency of invasive mammary carcinoma and ductal carcinoma in situ on excision ranging from 0% to 40% [8,15–23]. However, recent studies with careful radiology–pathology correlation suggest that upgrade to carcinoma occurs in ≤2% of cases with radial scars on core biopsy [24,25]. The objective of this study was to determine the frequency of high-risk lesions (defined as atypical ductal hyperplasia or atypical lobular hyperplasia/classical lobular carcinoma in situ) and carcinoma in a series of excision specimens following a diagnosis of radial scar on core biopsy.

Materials and methods

This study was approved by the Cleveland Clinic Institutional Review Board. Breast core biopsies with a diagnosis of radial scar or complex sclerosing lesion from January 1, 2000, to March 26, 2014, were retrieved from the Anatomic Pathology information system CoPathPlus (Cerner Corporation, Kansas City, MO) using the search terms "radial scar," "complex sclerosing lesion," and "breast." For the purposes of this study, radial scars and complex sclerosing lesions were combined and referred to as radial scar. At low power, lesions were characterized by a stellate appearance (Fig. 1A) with a central focus of fibroelastotic stroma containing entrapped benign epithelial elements apparent at higher magnification (Fig. 1B). A total of 79 core biopsies with radial scars were initially identified. Thirty-five (35) of the 79 cases had no excision/no correlation with the site of core biopsy (19), missing slides (11), or missing core biopsy slides and were not excised (5). The data were analyzed for the entire group of 79 patients as well as for the 44 patients with excisions and available slides for both the core biopsy and the corresponding excision. Statistical analysis (Fischer's exact test and Pearson's correlation coefficient) was performed using JMP® software version 10.0.2 (SAS Statistical Institute, Inc., Cary, NC, USA).

The indications for core biopsy and patient age at biopsy were recorded for all cases. Biopsies of mammographic findings such as asymmetry (a finding only seen on one mammographic projection), calcifications, or architectural distortion without a corresponding sonographic finding were performed with a stereotactic technique using a dedicated prone stereotactic biopsy table and a Suros ATEC (Hologic, Inc., Marlborough, MA) or an Eviva (Hologic, Inc., Marlborough, MA, USA) 12-gauge core biopsy device. Routinely, at least six to 12 core specimens were obtained, with additional specimens obtained at the discretion of the radiologist. Biopsies of sonographic findings such as masses were performed free hand with a 14-gauge core biopsy device (C. R. Bard, Inc., Tempe, AZ). Biopsy specimens of magnetic resonance imaging (MRI) findings were obtained using a nine-gauge vacuum assisted core biopsy device (Suros ATEC, Hologic, Inc., Marlborough, MA, USA) with a 1.5-T magnet (Siemens Symphony, Siemens Medical Solutions, Malvern, PA, USA). Specimen radiography was completed on all CNBs performed for calcifications. Clips were placed after the core specimens were obtained and post-clip mammography was performed for all biopsies.

Radial scars were classified as incidental if they were not a part of the targeted lesion as determined from the radiology report or patient's imaging. Radial scars were considered the targeted lesion if pre-biopsy imaging showed a spiculated mass or architectural distortion and there was no separate coexisting mass-forming lesion in the core biopsy or excision specimen. If the targeted lesion was a calcification and the radial scar was not reported to contain calcification, the radial scar was regarded as incidental. According to the protocol at our institution, all radial scars found on core biopsy, whether they were the targeted lesion or incidental, were referred for evaluation by a surgeon. The patients who underwent surgery had a wire localization of the biopsy site prior to surgery and the biopsy site was identified in the excision specimens. The surgical pathology findings were correlated with the imaging findings and the largest size of the radial scar in either the core biopsy or the excision specimen was recorded.

All available surgical pathology reports for excision specimens following a core biopsy diagnosis of radial scar alone were reviewed. The presence and location of calcifications were included in the pathology reports for the core biopsy and the excisions. The submitted sections for all of the excision specimens included biopsy sites. Each core biopsy was individually correlated with a corresponding excision specimen when possible. The presence of atypical ductal hyperplasia, atypical lobular hyperplasia, classical lobular carcinoma in situ, flat epithelial atypia, ductal carcinoma in situ, and invasive mammary carcinoma in the core biopsy and excisions was recorded. For all cases, the presence and type of coexisting (in the same core) or concurrent (in a concurrent ipsilateral core biopsy) atypia or carcinoma was recorded. High-risk lesions were defined as atypical ductal hyperplasia or atypical lobular hyperplasia/classical lobular carcinoma in situ. An upgrade to carcinoma was defined as invasive mammary carcinoma or ductal carcinoma in situ in the excision specimen.

Clinical follow-up and chemoprevention data were obtained from the electronic medical record. For patients who underwent immediate surgical excision, the follow-up interval was calculated from the date of excision to the date of the most recent mammogram or progress note from a breast oncologist or primary care physician. For patients who did not have surgery, the follow-up interval was calculated from the date of core biopsy to the date of

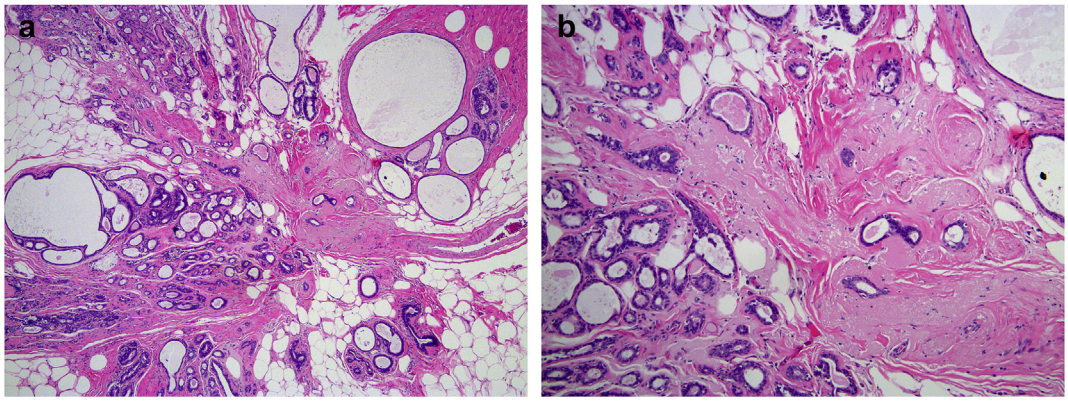

Fig. 1. Representative images of a radial scar diagnosed on core biopsy, hematoxylin and eosin stain (a and b at ×40 and ×100 magnification, respectively).

Please cite this article in press as: Donaldson AR, et al., Radial scars diagnosed on breast core biopsy: Frequency of atypia and carcinoma on excision and implications for management, The Breast (2016), http://dx.doi.org/10.1016/j.breast.2016.06.007

Download English Version:

https://daneshyari.com/en/article/8777226

Download Persian Version:

https://daneshyari.com/article/8777226

Daneshyari.com