



Contents lists available at ScienceDirect

Gynecology and Minimally Invasive Therapy

journal homepage: www.e-gmit.com

Original article

Initial closed trocar entry for laparoscopic surgery: Technique, umbilical cosmesis, and patient satisfaction

Aiko Sakamoto ^a, Iwaho Kikuchi ^{b,*}, Hiroto Shimanuki ^c, Kaoru Tejima ^a, Juichiro Saito ^a, Kano Sakai ^c, Jun Kumakiri ^c, Mari Kitade ^c, Satoru Takeda ^c^a Department of Gynecology, Juntendo Tokyo Koto Geriatric Medical Center, Japan^b Department of Obstetrics and Gynecology, Juntendo University Urayasu Hospital, Japan^c Department of Obstetrics and Gynecology, Juntendo University Faculty of Medicine, Japan

ARTICLE INFO

Article history:

Received 20 December 2016

Received in revised form

11 April 2017

Accepted 27 April 2017

Available online xxx

Keywords:

Closed laparoscopy

Laparoscopic myomectomy

Major vascular injury

Umbilical deformity

ABSTRACT

Background/Aims: Despite the benefits of laparoscopic surgery, which is being performed with increasing frequency, complications that do not occur during laparotomy are sometimes encountered. Such complications commonly occur during the initial trocar insertion, making this a procedural step of critical importance.

Methods: In 2002, we experienced, upon initial trocar insertion, a serious major vascular injury (MVI) that led to hemorrhagic shock, and we thus modified the conventional closed entry method to an approach that we have found to be safe. We began developing the method by first measuring, in a patient undergoing laparoscopic cystectomy, the distance between the inner surface of the abdominal wall and the anterior spine when the abdominal wall was lifted manually for trocar insertion and when it was lifted by other methods, and we determined which method provided the greatest distance. We then devised a new approach, summarized as follows: The umbilical ring is elevated with Kocher forceps. The umbilicus is everted, and the base is incised longitudinally. This allows penetration of the abdominal wall at its thinnest point, and it shortens the distance to the abdominal cavity. A bladeless trocar (Step trocar) is used to allow insertion of the Veress needle. We began applying the new entry technique in July 2002, and by December 2014, we had applied it to 9676 patients undergoing laparoscopic gynecology surgery. **Results:** All entries were performed successfully, and no MVI occurred. The umbilical incision often resulted in an umbilical deformity, but in a questionnaire-based survey, patients generally reported satisfaction with the cosmetic outcome.

Conclusion: A current new approach provides safe outcome with a minor cosmetic problem.

Copyright © 2017, The Asia-Pacific Association for Gynecologic Endoscopy and Minimally Invasive Therapy. Published by Elsevier Taiwan LLC. This is an open access article under the CC BY-NC-ND license (<http://creativecommons.org/licenses/by-nc-nd/4.0/>).

Introduction

With the development of peripheral devices and new laparoscopic techniques, the indications for laparoscopic surgery continue to expand. It is no longer an exaggeration to say that laparoscopic surgery has become the gold standard for many surgical procedures. However, complications that do not occur during laparotomy

are being encountered with increasing frequency,¹ and effective measures for avoiding these complications are being devised.

Complications associated with laparoscopic surgery commonly occur during the initial trocar insertion,^{2,3} making this a procedural step that requires maximum caution. Accordingly, various measures and medical devices have been developed to facilitate the initial trocar insertion. The closed entry method, during which a Veress needle is used and the primary trocar is inserted blindly, is reported to confer a high risk of major vascular injury (MVI) in the retroperitoneum.^{3,4} Such MVIs can be life-threatening and should be prevented by all possible means.

Laparoscopic surgery was introduced at our hospital in July 1993, and over the next 9 years, we applied the closed insertion method in a total of 2440 patients undergoing laparoscopic

Conflicts of interest statement: The authors have no conflicts of interest relevant to this article.

* Corresponding author: Department of Obstetrics and Gynecology, Juntendo University Urayasu Hospital, Tomioka 2-1-1, Urayasu City, Chiba 279-0021, Japan. Fax: +81 47 352 0187.

E-mail address: kikuchiban@hotmail.com (I. Kikuchi).

<http://dx.doi.org/10.1016/j.gmit.2017.04.001>

2213-3070/Copyright © 2017, The Asia-Pacific Association for Gynecologic Endoscopy and Minimally Invasive Therapy. Published by Elsevier Taiwan LLC. This is an open access article under the CC BY-NC-ND license (<http://creativecommons.org/licenses/by-nc-nd/4.0/>).

Please cite this article in press as: Sakamoto A, et al., Initial closed trocar entry for laparoscopic surgery: Technique, umbilical cosmesis, and patient satisfaction, Gynecology and Minimally Invasive Therapy (2017), <http://dx.doi.org/10.1016/j.gmit.2017.04.001>

gynecologic surgery. In July 2002, however, we experienced a serious MVI that led to hemorrhagic shock, and consequently, we modified the conventional closed entry method to an approach that we believe is safer. Herein, we describe the investigation we undertook to develop the modified method, the method itself, and results we have obtained thus far. In addition, because use of our new method resulted in umbilical deformities in some cases, we also investigated, by means of a questionnaire, patients' satisfaction with the resulting umbilical irregularity, and we report our findings herein.

Methods and results

Preliminary investigation

As noted above, we used the conventional trocar insertion method (Fig. 1A and B) in all cases of laparoscopic gynecologic surgery performed between July 1993 and June 2002. MVI occurred in 5 (0.02%) of the 2440 patients. The 5 patients were all relatively slim (mean body mass index [BMI] = 19.3 ± 0.8). Despite the fact that all 5 MVIs resolved spontaneously during the post-surgical follow-up period, their occurrence, especially the MVI leading to hemorrhagic shock, prompted us to find a means by which the first trocar can be inserted more safely, even in slim patients and regardless of the surgeon's level of experience.

Toward the development of a safe initial trocar insertion method, we first looked into ensuring an adequate space between the inner surface of the abdominal wall and the anterior surface of the lumbar spine where the retroperitoneal vessels reside. In a patient with a body mass index (BMI) of 19.9 and undergoing laparoscopic ovarian cystectomy and who provided informed consent, we measured the distance between the inner surface of

the abdominal wall and the anterior surface of the lumbar spine when the abdominal wall was lifted manually for trocar insertion and also when the abdominal wall was lifted by other methods, and in so doing, we determined which method provides the greatest distance. We applied the 4-trocar method described by Roy et al,⁵ and we created a sterilized measuring device by attaching 1-cm-wide strips of vinyl tape at intervals of 1 cm to a cherry-tip dissector (Ethicon Co. Ltd., New Brunswick, NJ, USA). This device was inserted perpendicularly so that we could measure two distances: that between the upper surface of the abdominal wall and the anterior surface of the lumbar spine, and that between the inner surface of the abdominal wall and the anterior surface of the lumbar spine. After measuring the distance between the skin at the point of highest elevation and the surface of the lumbar spine before abdominal insufflation, we elevated the abdominal wall by 3 different methods (Fig. 2), and after each elevation, we performed an endoscopic examination via another trocar and measured the distance between the inner surface of the abdominal wall and the lumbar spine.

Results of our preliminary investigation

As shown in Table 1, by pinching the skin around the umbilicus for insertion of the insufflation needle or by compressing the skin on either side of the umbilicus for insertion of the trocar, we found that the abdominal wall is elevated very little. However, by grasping and elevating the umbilical ring with Kocher forceps, a distance of 13 cm between the inner surface of the abdominal wall and anterior surface of the lumbar spine is obtained, and the skin is elevated approximately 2 cm further. We also found that everting the umbilicus completely and incising the base of the umbilicus vertically allowed us to penetrate the abdominal wall at

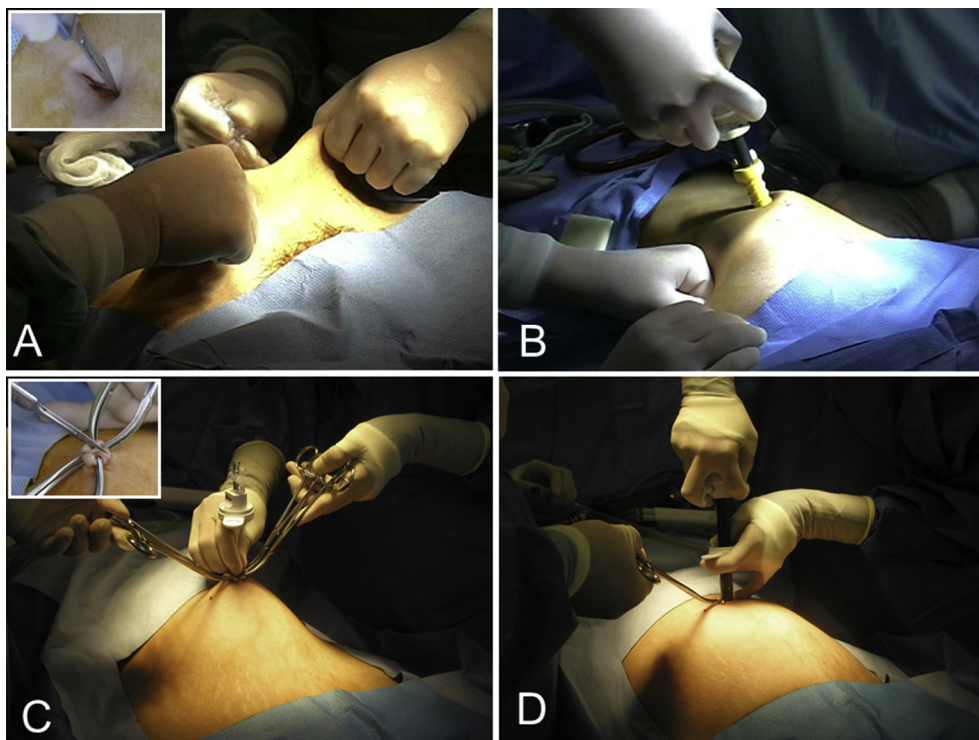


Fig. 1. Conventional trocar insertion method and newly developed trocar insertion method. (A) When the conventional method is used, the skin is lifted manually, a Veress needle is inserted into the horizontal incision that has been made along the lower margin of the umbilical ring, and the abdomen is insufflated; (B) After removal of the Veress needle, the abdominal wall is pressed against from the left and right, and a “safety shielded trocar” is inserted. (C) When our new entry method is used, the umbilicus is lifted with Kocher forceps, and a Step Veress needle is inserted into the vertical incision that has been made at the base of the umbilicus; (D) After insufflation, the inner needle is removed, an 11-mm blunt-tip dilator is inserted to dilate the expandable sleeve, and the trocar is set in place.

Download English Version:

<https://daneshyari.com/en/article/8781173>

Download Persian Version:

<https://daneshyari.com/article/8781173>

[Daneshyari.com](https://daneshyari.com)