



Case report

Combined bilateral ophthalmic artery occlusion & central retinal vein occlusion from presumed giant cell arteritis

Mark Hankins, Sarina Amin, Andres Gonzalez, Hazem Samy*

University of Florida College of Medicine, Department of Ophthalmology, Gainesville, FL, United States

ARTICLE INFO

Keywords:

Giant cell arteritis
Temporal arteritis
Intravenous
Bilateral
Ophthalmic artery occlusion
Central retinal artery occlusion
Central retinal vein occlusion
Biopsy negative

ABSTRACT

Purpose: To report on a severe case of presumed giant cell arteritis (GCA) presenting with partial and complete ophthalmic artery occlusion along with bilateral central retinal vein occlusions (CRVO).

Observations: A 73-year-old female presented with bilateral complete vision loss of sudden onset. The patient also experienced a mild frontal headache prior to onset of vision loss. Fundus examination revealed bilateral central retinal artery occlusion (CRAO) and CRVO. Subsequent fluorescein angiography indicated partial right ophthalmic artery occlusion and complete left ophthalmic artery occlusion. Acute phase reactants were elevated. The patient was clinically diagnosed with GCA and intravenous (IV) steroids were initiated. Four days later, a temporal artery biopsy (TAB) was performed and resulted as negative for granulomatous inflammation. The patient did not regain vision and remained with no light perception (NLP) in both eyes.

Conclusions: and **Importance:** This case highlights the discrepancy between clinical diagnosis and pathologic tissue diagnosis in a patient that presented with such extensive ocular vasculitic disease. Such extensive bilateral disease has not been reported. In addition, there are few studies regarding the effect of pulse-dosed IV steroids on TAB results. This case report suggests that the gradual histologic changes that occur over one or two weeks while on oral steroids may occur over three to four days while on high dose IV steroids, necessitating early biopsy.

1. Introduction

Giant cell arteritis (GCA) is a large-vessel vasculitis of unknown etiology that has a predilection for elderly females. It can result in a variety of systemic complications, but loss of vision is one of its most significant morbidities. Permanent vision loss may occur in as many as 20% of patients with GCA and can even lead to bilateral blindness if prompt treatment with corticosteroids is not initiated.^{1,2} The ocular complications are usually the result of ischemia to the region of the ophthalmic circulation.³ A central retinal artery occlusion may be the only manifestation of GCA.⁴ Bilateral retinal artery occlusion due to GCA has been reported,^{5,6} along with a case of a central retinal artery occlusion (CRAO) combined with a central retinal vein occlusion (CRVO) in one eye.⁷ In this report, we describe a patient who presented with bilateral CRVOs along with a partial ophthalmic artery occlusion in one eye and complete ophthalmic artery occlusion in the other eye due to presumed GCA. To our knowledge, there are no reports of such extreme vascular compromise due to GCA.

This case highlights the discrepancy between clinical diagnosis and pathologic tissue diagnosis in a patient that presented with such extensive ocular vasculitic disease. In addition, there are few studies

regarding the effect of pulse-dosed intravenous (IV) steroids on TAB results. This case report suggests that the gradual histologic changes that occur over one or two weeks while on oral steroids may occur over three to four days while on high dose IV steroids, necessitating early biopsy.

2. Case report

A 73-year-old Caucasian female with a history of hypertension, remote history of HSV encephalitis, osteoarthritis, and atrial fibrillation presented to the emergency department for bilateral acute, painless vision loss of three-day duration. The patient developed complete vision loss in the left eye and approximately 48 h later developed complete vision loss in the right eye. Ten days prior to onset of vision loss, she reported experiencing new-onset of frontal headaches. Steady weight decline was also noted on review of systems, which was otherwise negative. At the time of initial presentation, the patient noted right eye soreness that was more evident with eye movement. Past ocular history included bilateral uncomplicated cataract extraction two years prior to presentation. Treatment regimen for atrial fibrillation included anti-arrhythmic control with verapamil, rate control with

* Corresponding author. University of Florida School of Medicine, Department of Ophthalmology, 1600 SW Archer Rd., Gainesville, FL, 32610, United States.
E-mail address: hsamyuf@gmail.com (H. Samy).

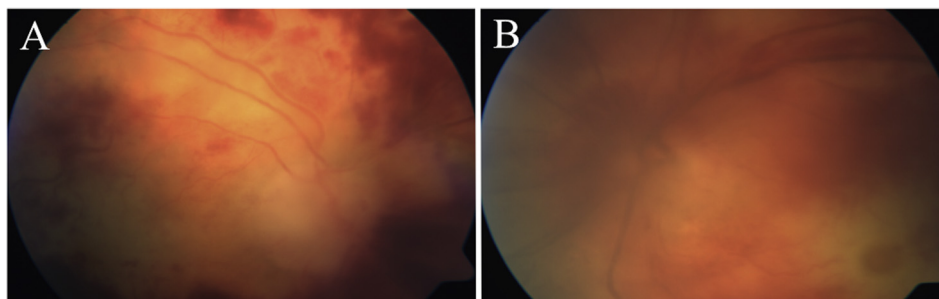


Fig. 1. Fundus photo of the right (A) and left (B) eyes demonstrating diffuse intraretinal hemorrhages, pallid retina, with optic disc edema in both eyes. A cherry red spot is visible in the left eye. (For interpretation of the references to colour in this figure legend, the reader is referred to the Web version of this article.)

metoprolol, and anticoagulation with warfarin with a therapeutic international normalized ratio (INR).

Exam showed bilateral no light perception (NLP) vision, normal intraocular pressures in each eye, bilateral amaurotic pupils, and full ocular motility. Slit lamp exam revealed 1 + cell in the anterior chamber of the right eye. The left eye was found to have corneal edema, Descemet folds, keratic precipitates, and 2 + cell in the anterior chamber. Dilated exam revealed diffuse intraretinal hemorrhages, diffuse pallor with a cherry red spot in the macula, and optic disc edema in both eyes. However, the view in the left eye was limited due to corneal edema (Fig. 1).

Lab work revealed elevated acute phase reactants (estimated sedimentation rate: 130 mm/h, C-reactive protein: 17.9 mg/L, fibrinogen: 493 mg/dL), therapeutic INR of 2.5, and anemia with a hemoglobin of 9.1 g/dL. Hypercoagulability work up was negative. Evaluation for lupus, anti-neutrophil cytoplasmic antibody-associated vasculitides, and multiple myeloma were also negative. Anterior chamber paracentesis with aqueous sampling was performed for cytomegalovirus polymerase chain reaction (PCR) and herpes simplex virus PCR. Cytomegalovirus PCR was negative and herpes simplex PCR was equivocal. Fluorescein angiogram showed no choroidal filling, a complete lack of central retinal artery filling in the left eye, and only partial central retinal artery filling in the right eye (Fig. 2). Computed tomography angiogram of the head and neck was performed to rule out carotid stenosis and was negative.

With a clinical diagnosis of GCA, the patient was admitted to the hospital for thorough evaluation and pulse-dose IV steroids, methylprednisolone 250 mg every 6 h, for three days (a total dose of 3 g). After completion of IV corticosteroids, transition to oral prednisone taper was initiated, starting with a dose of 60 mg daily. The following day, a unilateral temporal artery biopsy (TAB) was performed. The biopsy specimen was 2.7 cm in length and revealed no evidence of arteritis. Immunohistochemical analysis for Varicella Zoster Virus (VZV) antigen was found to be negative. Despite aggressive therapy, the patient did not regain any vision.

3. Discussion

The case described in this report has several clinical findings that are suggestive of GCA. These findings include: female over the age of 55, sudden onset of painless visual loss, progression to bilateral involvement, antecedent frontal headache, and elevation of acute phase reactant inflammatory markers. Although the TAB was negative, the diagnosis of GCA can still be made with confidence according to the American College of Rheumatology's (ACR) diagnostic criteria which states that three or more of the following yields a diagnostic specificity of 91.2%: 50 years or older, new-onset headache or localized pain, temporal artery tenderness to palpation or decreased pulsation, ESR of 50 mm/h or higher, and positive TAB results.⁸

This case represents a unique and extreme presentation of presumed GCA with extensive ocular involvement with negative TAB five days

after initiation of IV steroids. Combined partial ophthalmic artery occlusion and CRVO in one eye with concurrent ophthalmic artery occlusion and CRVO in the contralateral eye with rapidly progressive deterioration of vision suggests GCA as the diagnosis. There are no known reports of such an extreme presentation of GCA in the literature, and the acute onset further highlights the need for prompt treatment of GCA. In addition, recent reports of VZV antigen positivity in skip lesions of TAB specimens of presumed GCA cases may suggest the importance of VZV pathogenicity in GCA.⁹

The role of IV steroids on the histologic results of the TAB are not known. Several studies have been performed regarding the impact of oral steroids on the TAB,^{10–12} and current standard of care consists of initiating steroids at a dose of 80–100 mg of prednisone and performing biopsy within shortly after starting steroids, as histological changes from GCA are seen for a few weeks after initiation of treatment.¹³ Review of the current literature did not reveal any studies examining the histologic changes of TAB specimens following IV steroid treatment in comparison with oral steroid therapy. We hypothesize that the gradual histologic changes that occur over weeks and months while on oral steroids can occur over days while on high dose IV steroids. The current standard oral prednisone dose is comparatively smaller than the bolus of 3 g of IV methylprednisolone that our patient received over the course of three days. Thus, we recommend that if the diagnosis of GCA hinges on a positive biopsy, then the TAB should be performed within hours of IV steroid initiation. However, further study is warranted to establish causality between high-dose IV steroids and a negative TAB because a negative biopsy in this case could also be accounted for by the small, unilateral temporal artery sample that was obtained which may not have included the involved portion of the vessel. Indeed, the reported sensitivity of TAB has ranged widely, from as low as 15% to as high as 87%.¹⁴ On the other hand, the ACR clinical criteria for GCA diagnosis yields a specificity of 91.2%. Therefore, if the patient meets such criteria then we suggest that biopsy can be foregone and prompt treatment should be initiated to prevent potential severe vision loss and morbidity.

4. Patient consent

Informed consent for this case report was not obtained, although no identifying information is included. The study was carried out without approval from our Institutional Review Board, as none is needed from our institution for case reports (<http://irb.ufl.edu/index/humanrsch.html>).

Acknowledgements and disclosures

Funding

The work has been supported by an unrestricted grant from the Research to Prevent Blindness (RPB) group, which has no conflicts of interest with this work.

Download English Version:

<https://daneshyari.com/en/article/8790881>

Download Persian Version:

<https://daneshyari.com/article/8790881>

[Daneshyari.com](https://daneshyari.com)