



Case report

Conservative management of penetrating ocular trauma caused by a nail gun



Carral-Santander Irving Enrique^{a,*}, Acón-Ramírez Dhariana^a, Soberón-Ventura Vidal^a, Peñaranda-Henao Carlos Felipe^a, Wheelock-Gutiérrez Lorena^b, García-Aguirre Gerardo^a

^a Retina Department, Asociación para Evitar la Ceguera en México, Hospital “Dr. Luis Sánchez Bulnes” IAP, Mexico City, Mexico

^b Ophthalmology, Asociación para Evitar la Ceguera en México, Hospital “Dr. Luis Sánchez Bulnes” IAP, Mexico City, Mexico

ARTICLE INFO

Keywords:

Penetrating ocular trauma
Intraocular foreign body
Pars plana vitrectomy
Scleral wound
Nail gun

ABSTRACT

Purpose: To report the conservative management of a penetrating ocular trauma caused by a nail gun with a six-month follow up.

Observations: A 21 year-old healthy female suffered an ocular penetrating trauma with a nail gun. She presented with a metallic foreign body that partially entered her left eye through the nasal sclera via pars plana, 3 mm posterior to the limbus, but did not reach the retina. Surgical removal of the foreign body and closure of the scleral wound, without vitrectomy, was performed 16 h after the injury. Intravitreal prophylactic antibiotic was administered. Retinal atrophy developed in the areas that had *commotio retinae* at presentation, but no further complications were observed.

Conclusions: and Importance: Pars plana vitrectomy may not be necessary in all penetrating ocular traumas with intraocular foreign body, as long as the foreign body is accessible from the exterior of the eye and there are no other conditions (such as vitreous hemorrhage, retinal detachment, endophthalmitis, etc) that are an indication for vitrectomy.

1. Introduction

Penetrating globe injuries can cause severe visual loss as well as devastating consequences to the eye. These are more frequent in men than in women and can be caused by sharp objects or high velocity objects.¹ Since 1950, when the use nail guns became popular, several reports regarding various kinds of injuries to different organs have been published.² The eye is not the most common place of injury, but when it is affected, damage can be severe; nails can reach speeds up to 90 miles per hour. Nowadays there is no evidence on the incidence of accidents with nail guns globally; but Burger et al., published that in a center in South Carolina it represented approximately 14% of penetrating ocular trauma cases.³

We report a case of a young female who suffered an eye-penetrating injury caused by a nail gun at work. The nail was retained, but did not compromise the integrity of the lens or the cornea. Conservative surgical management (i.e. removal of IOFB without pars plana vitrectomy) was performed, with a satisfactory anatomical outcome.

1.1. Case report

A 21 year-old healthy Mexican female that worked as a carpenter assistant presented to our Retina Department with a history of ocular trauma when handling a nail gun that was pointing towards her face, causing a penetrating injury on her left eye. The patient was examined 4 h after the incident. Visual acuity was 20/20 right eye and 20/100 on her left eye. Slit lamp biomicroscopy showed a metallic foreign body that had entered partially through the nasal sclera via pars plana 3 mm posterior to the limbus, without apparent damage to the lens or cornea (Fig. 1A). Fundoscopy showed the body of the nail pointing toward the optic nerve without touching the retina. Vitreous hemorrhage was absent and the retina remained attached, with significant areas of *commotio retinae* on the nasal, inferior and temporal quadrants (Fig. 1B).

B-scan ultrasound and an ultrasound biomicroscopy (UBM) were performed as part of the initial work up, revealing the presence of a foreign body that measured 13.4 mm in length and confirming the absence of retinal rupture (Fig. 2A). The disruption of the sclera at the site of entrance was evidenced by UBM (Fig. 2B).

The patient underwent surgery under general anesthesia 16 h after trauma, which consisted on performing a 180° peritomy, pre-placing of

* Corresponding author. Vicente García Torres #46. Col. San Lucas Coyoacán, Mexico City, Mexico
E-mail address: ics13@hotmail.com (C.-S. Irving Enrique).

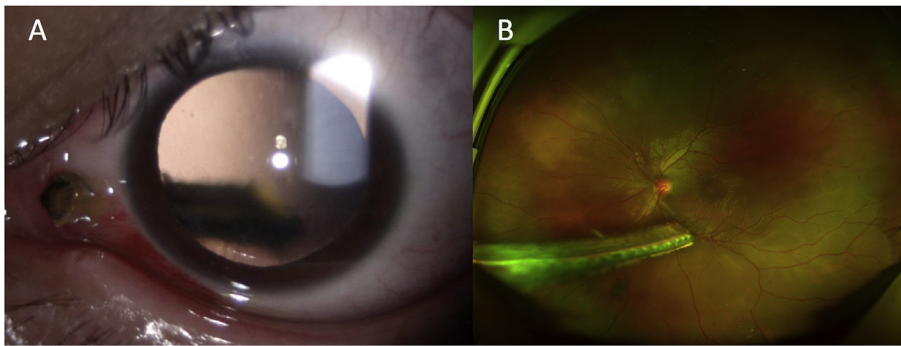


Fig. 1. A. Slit-lamp photograph of the anterior segment showing a metallic foreign body that entered through the nasal sclera via pars plana, 3 mm posterior to the limbus; other anterior segment structures were undamaged. B. Ultra-wide field fundus image showing an intraocular metallic foreign body in the vitreous cavity that was not in contact with the retina. A large area of commotio retinae is apparent throughout the retina. Secondary traumatic vasculitis areas are seen in the inferotemporal arcade.

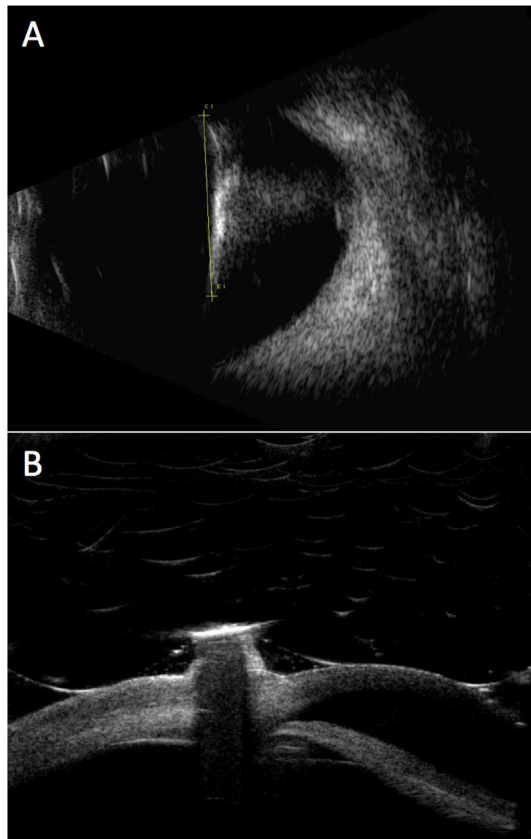


Fig. 2. A. B-scan Ultrasound of left eye showing a hyperechoic foreign body in the vitreous cavity without touching the retina and a reverberation artifact. B. Ultrasound biomicroscopy of left eye showing a foreign body penetrating the sclera and ciliary body without touching the lens.

an 8-0 nylon cross-suture on the wound and carefully removing the nail through the entrance wound with a curved dressing forceps, with immediate tightening of the pre-placed suture. Protruding vitreous was removed externally with Vannas scissors, and two additional sutures were placed in order to completely close the scleral wound. Subsequently, the retina was carefully examined using indirect ophthalmoscopy and a 20-Diopter lens to verify the absence of retinal tears, holes or detachment. Finally, an intravitreal injection of 0.5 mg moxifloxacin and 0.1 mg dexamethasone was performed, and the conjunctiva was closed using 7-0 polyglactin suture (Fig. 3, Video 1).

Supplementary video related to this article can be found at <http://dx.doi.org/10.1016/j.ajoc.2018.06.010>.

On the first postoperative day, the left eye had visual acuity of counting fingers, and the retina remained attached with areas of contusion inferiorly and in the foveal and parafoveal area that appeared hyperautofluorescent on fundus autofluorescence (FAF). Optical

coherence tomography (OCT) of the macula showed hyperreflectivity of the outer retina, presence of subretinal fluid and disruption of the ellipsoid zone. One week after surgery, visual acuity improved to 20/800 and subtle pigmentary changes were present on the areas of contusion. Hyperautofluorescence was still evident on FAF and the damage to the photoreceptor layers was clearer on OCT. Forty days later, pigmentary epitheliopathy and central outer retinal atrophy was evident. At 6 months of follow-up, visual acuity improved to 20/250, the retina remained attached and a pigment epitheliopathy was established on the contusion areas. On FAF, a mottled hyper/hypo autofluorescent pattern was observed, with complete loss of subfoveal photoreceptors evidenced by OCT (Fig. 4).

2. Discussion

We present a case of an open globe injury with a retained metallic foreign body that was managed with conservative surgery that included removal of the foreign body through the entrance wound and scleral closure without performing pars plana vitrectomy or any other additional maneuver. The anatomic outcome was satisfactory, without subsequent retinal tears or detachment, but the functional outcome was poor, mainly due to atrophy of the outer retinal layers in the areas that had commotio retinae preoperatively.

Kolomeyer et al. have reported that from patients suffering nail gun open globe injuries, 14% of them had retained intraocular foreign bodies, 40% developed traumatic cataracts and 23% developed retinal detachment during follow up visits. Vitreous hemorrhage and hyphema were two of the most common presentations.⁴

Intraocular foreign bodies account for 18%–41% of all the open globe injuries, and most of them (58%–88%) reside in the posterior segment. Visual prognosis depends on many factors such as the size of the foreign body, the zone and extent of injury and subsequent complications such as retinal detachment of endophthalmitis; pars plana vitrectomy is the most common technique used to treat these eyes.⁵ Yeh et al. reported that timing is important to reduce the incidence of post traumatic endophthalmitis.⁶ Early treatment can also be beneficial to control inflammation and decrease the rate of proliferative vitreoretinopathy, although it might not be associated to significantly larger improvement in visual acuity.⁷

Previous case reports discuss the best management of ocular trauma with retained nails. In such cases, visual acuity outcomes are variable, ranging from 20/40 to light perception. In our case, the poor final visual acuity was due to retinal atrophy that resulted from commotio retinae. The decision to perform or not a pars plana vitrectomy is made based on the initial clinical findings such as the presence of vitreous hemorrhage, vitreous traction, tears, retinal detachment or cataract.^{2,3,8} In our case, IOFB compromised the posterior segment but the retina was attached with no vitreous hemorrhage, and part of the foreign body was protruding externally. Early surgery was performed with only removal of the foreign body, closure of the wound and injection of prophylactic antibiotics. Patient did not develop endophthalmitis, retinal

Download English Version:

<https://daneshyari.com/en/article/8790930>

Download Persian Version:

<https://daneshyari.com/article/8790930>

[Daneshyari.com](https://daneshyari.com)