

Brief Report

Acute primary angle-closure in Sturge-Weber syndrome

Wei-Wen Su^{a,b,*}^a Department of Ophthalmology, Chang Gung Memorial Hospital Linkou Branch, Taoyuan Taiwan, ROC^b Chang Gung University College of Medicine, Taoyuan, Taiwan, ROC

ARTICLE INFO

Keywords:

Sturge-Weber syndrome
Acute primary angle-closure glaucoma
Phacoemulsification
Intra-ocular lens implantation
Laser iridotomy

ABSTRACT

Purpose: Sturge-Weber syndrome (SWS) is a neurocutaneous disorder characterized by facial cutaneous venous dilatation (port-wine stain), leptomeningeal angioma, and ocular abnormalities. Here we report a case of SWS who experienced acute primary angle-closure in the same side of the nevus flammeus.

Observations: A 64-years-old female patient with SWS port wine stain on the left side of her face was referred to our ER for acute primary angle-closure (PAC). The IOP was 64 mmHg in the left eye (12 mmHg in OD) and the visual acuity was 20/100. The acute PAC was aborted after medical treatment with intravenous Mannitol and oral Acetazolamide, but laser iridotomy (LI) was not performed because of the risk of bleeding. After the acute episode, her IOP remained stable in midteen under 3 topical medications. However, the patient reported several subacute attacks in the following month. We arranged phacoemulsification and intraocular lens (IOL) implantation two months after the initial PAC attack. The post-op condition was smooth with 20/20 visual acuity, and the angle opened dramatically on anterior segment optical coherence tomography (AS-OCT). Her IOP was around 13 mmHg without medication and there was no more acute PAC attack.

Conclusions: SWS with ipsilateral acute PAC has seldom been reported. Lens extraction and IOL implantation can be an option in treating such patients since conventional laser iridotomy may cause bleeding.

1. Introduction

Sturge-Weber syndrome is a neurocutaneous disorder characterized by unilateral facial cutaneous venous dilation often called port-wine stain, leptomeningeal capillary-venous malformation, and vascular abnormalities of the eye. Vascular abnormalities can affect any portion of the eye, including eyelid, orbit, conjunctiva, episclera, ciliary body, retina, and choroid. Choroidal hemangiomas occur in 20–70% of patients with SWS¹ which may cause vision loss from choroidal thickening or retinal detachment. Glaucoma occurs in 30%–70% of individual of SWS,² usually unilateral and often diagnosed in infancy, though it can also develop later. Theories regarding the mechanism of glaucoma in eyes with SWS are developmental anomaly of the anterior chamber angle and elevated episcleral venous pressure, each lead to aqueous outflow obstruction. Here we report an unusual case of acute primary angle-closure in a 64-years-old woman with ipsilateral SWS who received phacoemulsification and intraocular lens (IOL) implantation as an initial treatment instead of conventional laser iridotomy.

2. Case report

A 64-years-old female patient with SWS port wine stain on the left

side of her face (Fig. 1), who never had elevated IOP before, was referred to our ER for acute eye pain, blurred vision, headache and nausea. The patient presented as typical acute primary angle-closure (PAC) in the left eye with microcystic edema of the cornea, fixed mid-dilated pupil, and very shallow angle. The IOP was 64 mmHg in the left eye (12 mmHg in OD) and the visual acuity was 20/100. After medical treatment with intravenous Mannitol and oral Acetazolamide, her IOP lowered to midteen, and was maintained under three topical anti-glaucoma medications. When the IOP was normalized and the cornea cleared up, there was no vascular abnormalities of the anterior segment on slit lamp examination except dense episcleral venous plexus and dilatations of the conjunctival vessels (Fig. 2). Both of her eyes were phakic, with mild cataract as her age. Her best corrected visual acuity improved to 20/25 in the left eye (20/20 in the right eye). The refraction was +1.00/-0.75 × 90 in the right eye and +0.75/-0.50 × 5 in the left eye. Gonioscopy showed a Schaffer grade III angle opening in the right eye and grade 0 in the left eye. The cup-to-disc ratio was 0.6 × 0.6 with intact neural rim OU, though diffuse choroidal hemangioma was observed in the left fundus, which was also presented in spectral domain OCT (SD-OCT) as increased choroidal thickness (Fig. 3). The SD-OCT showed similar peripapillary retinal nerve fiber layer (RNFL) thickness in both eyes and diminished ganglion cell

* Department of Ophthalmology, Chang Gung Memorial Hospital Linkou Branch, No. 5, Fuhsing Street, Kweishan, Taoyuan 333 Taiwan, ROC.
E-mail address: vickysuweiwen@gmail.com.

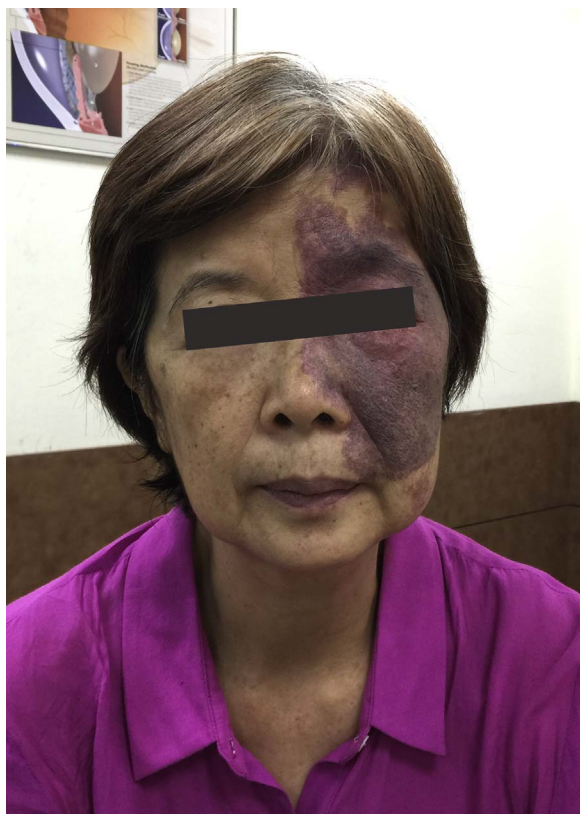

Fig. 1. Patient with Sturge-Weber syndrome presents with port wine stain on the left side of her face.

complex (GCC) thickness in the left eye (Fig. 4). The anterior chamber depth/axial length (ACD/AL) were 2.77 mm/23.99 mm in the right eye and 2.03 mm/23.35 mm in the left eye. The anterior segment optical coherence tomography (AS-OCT) showed the AOD500/TISA500 were 185 μm /0.085 mm^2 in the right eye and 95 μm /0.054 mm^2 in the left eye (Fig. 5). Because of the risk of bleeding, laser iridotomy (LI) was not performed. Although the IOP remained stable in midteen under three topical anti-glaucoma medications, the patient reported several sub-acute attacks in the following month. After discussing with the patient, phacoemulsification and IOL implantation was arranged two months after the initial PAC attack. There was no lens subluxation during the surgery. The post-op condition was smooth with 20/20 visual acuity. The postoperative ACD/AL in the left eye was 3.85 mm/23.27 mm, and the AS-OCT showed a marked angle widening, the AOD500/TISA500 increased to 587 μm /0.229 mm^2 (Fig. 5). Her IOP was around 13 mmHg without medication, and there was no more acute PAC attack.

3. Discussion

Glaucoma is one of the most common ocular manifestations in SWS,

occurring in 30–70% patients² and is typically congenital. The mechanism of glaucoma in SWS involves developmental anomaly of the anterior chamber angle and elevated episcleral venous pressure, each lead to aqueous outflow obstruction. Angle-closure glaucoma is a rare presentation in SWS, which has been reported as a consequence of ectopia lentis and posterior scleritis.^{3,4} Our patient had good vision and no optic atrophy in the affected eye, indicating there was no IOP elevation before this event. The gonioscopy did not show a corresponding angle narrowing in the right eye, implying that the angle closure in the left eye might possibly be related to the alteration of the ciliary body configuration, secondary to the diffuse choroidal hemangioma of SWS. It has been hypothesized that choroidal hemangioma can lead to shallow anterior chamber and subsequent angle closure.^{5,6} A pre-operative UBM would be crucial to clarify whether there was annular choroidal effusion, ciliary body swelling, anterior rotation of the ciliary process, and a forward shift of the lens-iris diaphragm, unfortunately not available in this report.

Conventional laser iridotomy may relieve pupillary block in such condition but there is risk of bleeding since the vascular abnormalities can affect any portion of the eye. Early phacoemulsification with IOL implantation was reported to be more effective than laser iridotomy in lowering IOP, reducing recurrence, improving visual acuity, and diminishing the need for antiglaucoma medication in eyes with acute PAC and coexisting cataract.⁷ Our patient had mild cataract since her pre-operative best corrected visual acuity was 20/25, but still benefited from the surgery. However, while cataract extraction can be an option in a 64-year-old patient, this might not be the case for children who present glaucoma at an early age.

4. Conclusions

SWS with ipsilateral acute PAC has rarely been reported clinically. Since the vascular abnormalities can affect the iris, laser iridotomy may increase the risk of bleeding. Phacoemulsification and IOL implantation reduces recurrence, improves vision, and diminishes the need of anti-glaucoma medication, thus can be considered an initial treatment for patients with SWS and acute PAC.

5. Patient consent

Informed consent was obtained from this patient in writing for publication of her case details.

Funding

No funding or grant support.

Conflicts of interest

The author has no financial disclosures.

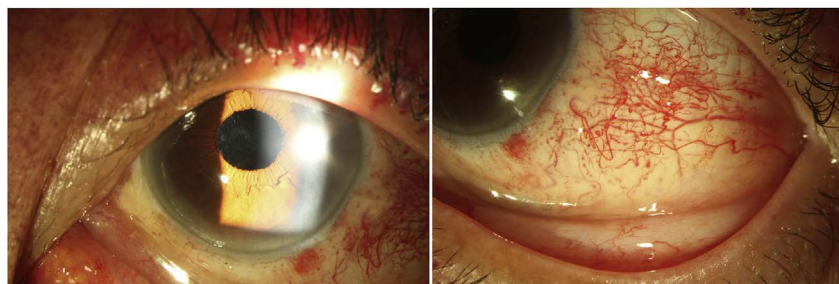


Fig. 2. Slit lamp examination shows dense episcleral venous plexus and dilations of the conjunctival vessels, but no iris vascular abnormality.

Download English Version:

<https://daneshyari.com/en/article/8790977>

Download Persian Version:

<https://daneshyari.com/article/8790977>

[Daneshyari.com](https://daneshyari.com)