

Case report

Spectral optical coherence tomography findings in an elderly patient with syphilitic bilateral chronic panuveitis

Ariel Schlaen^{a,b,*}, Mariana Ingolotti^a, Cristobal Couto^b, Mario Saravia^a^a Department of Ophthalmology, Hospital Universitario Austral, Argentina^b Department of Ophthalmology, University of Buenos Aires, Argentina

ARTICLE INFO

Keywords:

Ocular syphilis
Elderly patient
HIV infection
Retinitis
Panuveitis
Optical coherence tomography

ABSTRACT

Purpose: To report the spectral domain optical coherence tomography (SD-OCT) features of a focal retinitis in an elderly male patient with bilateral syphilitic panuveitis.

Observations: In the left eye (LE), spectral domain SD-OCT images during the active period revealed hyperreflectivity extending through the full thickness of the retina with no individualization of the layers, except for the retinal pigment epithelium. Once the lesion healed, SD-OCT imaging revealed an inner retinal atrophy and a mild disruption of the retinal pigment epithelium.

Conclusions and importance: In our patient, treponemal infection seemed to produce full-thickness retinal damage with partial involvement of the retinal pigment epithelium. The severe retinal damage, in this case, led to a poorer visual outcome than in other forms of syphilitic retinal involvement.

1. Introduction

Syphilis is a sexually transmitted systemic disease caused by the spirochete *Treponema pallidum*.¹ It remains a relevant cause of uveitis.² Since the year 2000, there has been an increase in the incidence of the disease, likely related to unprotected sexual intercourse in the era of highly active antiretroviral therapy for human immunodeficiency virus (HIV).³

Posterior segment manifestations of ocular syphilis are diverse and include, among others, superficial retinal precipitates, exudative retinal detachment, acute syphilitic placoid posterior chorioretinopathy, papillitis, vasculitis, neuroretinitis, chorioretinitis, and retinitis.^{4,5}

In this case, we describe the features from spectral domain optical coherence tomography (SD-OCT) of a case of focal macular retinitis in a patient with bilateral syphilitic panuveitis.

2. Case report

An 80-year-old male patient was admitted to our service with a diagnosis of a one-year duration chronic bilateral panuveitis. He had a history of bladder carcinoma diagnosed 3 years prior—treated with Bacillus Calmette Guerin immunotherapy—decreased hearing for the past 2 years, and seborrheic dermatitis. He denied having oral or genital ulcers. He complained of asthenia, arthralgia, and matinal stiffness of the hands and feet. He had lost 24 kg of weight over the previous year.

He carried laboratory tests conducted in another service, with normal results for complete blood count, liver function test (LFT), and blood urea nitrogen (BUN) test. Negative results include IgG and IgM for toxoplasma, Venereal Disease Research Laboratory (VDRL), antinuclear antibodies, and rheumatoid factor. He had a positive C reactive protein (CRP), an erythrocyte sedimentation rate (ESR) of 54 mm/h and a positive PPD. His chest radiography was normal. He was operated on for cataracts in both eyes two years ago. He underwent a diagnostic vitrectomy in the left eye (LE) two months ago, with a diagnosis of reactive inflammatory cytopathology. Brain MRI did not reveal any noteworthy signs.

At examination, best corrected visual acuity (BCVA) was light projection and hand movement in the right eye (RE) and the LE, respectively. At slit lamp examination, fine keratic precipitates were observed in both eyes, while 4+ and 2+ anterior chamber inflammatory cells were present in the RE and the LE, respectively. Intraocular pressure was 25 mmHg in the RE and 23 mmHg in the LE. At fundus examination, 4+ vitreous haze precluding the observation of the fundus details was observed in the RE, while 1+ vitreous haze and a whitish macular retinal lesion were noted in the LE (Fig. 1).

During the initial visit to our service, an SD-OCT (Spectralis, Heidelberg) was performed on the LE. At the level of the whitish lesion, the SD-OCT revealed hyperreflectivity extending through the full thickness of the retina with no individualization of the layers, with the exception of the retinal pigment epithelium (RPE) layer. A significant

* Corresponding author. Arenales 981 2P C1061AAE, Buenos Aires, Argentina.

E-mail address: ariel.schlaen@gmail.com (A. Schlaen).

<https://doi.org/10.1016/j.ajoc.2018.01.012>

Received 11 February 2017; Received in revised form 2 January 2018; Accepted 3 January 2018

Available online 08 January 2018

2451-9936/© 2018 The Authors. Published by Elsevier Inc. This is an open access article under the CC BY-NC-ND license (<http://creativecommons.org/licenses/by-nc-nd/4.0/>).

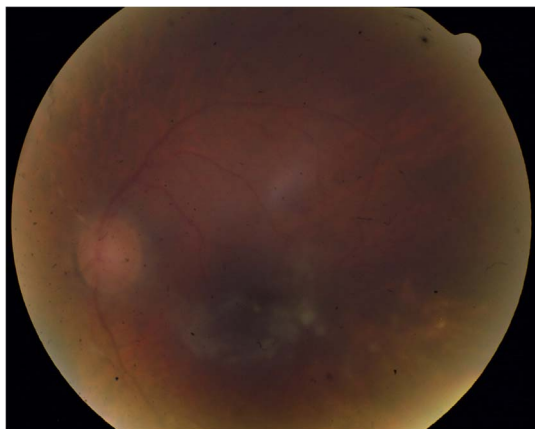


Fig. 1. LE color fundus photograph. A whitish lesion involving part of the fovea can be seen. (For interpretation of the references to color in this figure legend, the reader is referred to the Web version of this article.)

loss of the ellipsoid zone was also observed (Fig. 2). At the level of the fovea, a serous neuroepithelial detachment was observed, with a hyperreflectivity of the nasal inner perifoveal layers and a temporal full-thickness perifoveal hyperreflectivity with no individualization of the retinal layers, with some degree of atrophy, and with relative preservation of the retinal pigment epithelium. A significant loss of the ellipsoid zone was also noted (Fig. 3). At both locations, an epiretinal membrane was observed.

Lab tests, including HIV, VDRL, Fluorescent Treponemal Antibody Absorption test (FTA ABS), ESR, CRP, complete blood count, BUN, and LFT were ordered. Serologic results yielded a positive VDRL with very low titers, a positive FTA ABS, and a positive HIV test. The patient underwent a lumbar puncture with a negative VDRL in the cerebrospinal fluid. He was treated with 4 million units of intravenous penicillin G every 4 hours for 2 weeks. He did not receive any corticosteroid as part of his treatment regime.

Posttreatment BCVA improved to 20/50 in the RE while the LE persisted on HM. At slit lamp examination, 0.5+ anterior chamber

inflammatory cells were present in both eyes. Intraocular pressure was 15 mmHg in the RE and 13 mmHg in the LE. At fundus examination, vitreous haze improved significantly in both eyes (Figs. 4 and 5). In the RE, SD-OCT revealed a cystoid macular edema (Fig. 6). In the LE, a retinal atrophy with mild disruption of the RPE in the temporal hemimacula was observed (Fig. 7). At the level of the focal retinitis, an atrophy of the retinal layers with mild disruption of the RPE was observed (Fig. 8). A lack of recovery of the ellipsoid zone was found at both locations.

The patient was lost to follow-up for 8 months. When he came back to our consultation, the macular edema in the RE had persisted (Fig. 9). His BCVA was 20/60 and HM in the RE and the LE, respectively. A posterior sub-Tenon injection of 40 mg triamcinolone acetonide was administered to the RE. BCVA in the RE at 1 month improved to 20/30, with a significant reduction of macular edema at OCT (Fig. 10).

3. Discussion

Uveitis is the most common manifestation of syphilis in the eye.¹ Ocular involvement may depend on the stage of the disease. The incidence of ocular syphilis seems to be 100 times less frequent than the incidence of early syphilis,³ while a published series of syphilitic patients ill enough to be hospitalized recorded that 11 out of 36 cases (30.6%) had uveitis.³ Currently, syphilis is a rare cause of uveitis, accounting for 0.7–4.5% of cases.³ The predominant type of syphilitic uveitis varies in different case series. In a series of 24 patients, Barile and Flynn reported that granulomatous iridocyclitis was present in 46% of cases.⁶ Amaratunge et al. reported in their series of 143 patients that 55.2% of the cases were of posterior uveitis and 25.2% were of panuveitis.⁷ Our case consisted of chronic bilateral panuveitis, with retinal involvement.

There are several published articles describing the features of acute syphilitic posterior placoid chorioretinitis (ASPPC) from SD-OCT.^{8–10} In ASPPC, choroidal infiltration and transient loss of signal of the inner/outer segment junction and external limiting membrane layers were shown,² which were almost completely reverted with treatment.⁹ However, there are only two brief reports showing information about features of syphilitic retinitis in SD-OCT.^{5,11} Curi et al.⁵ were the first to show the intraretinal location of syphilitic multifocal retinitis in two

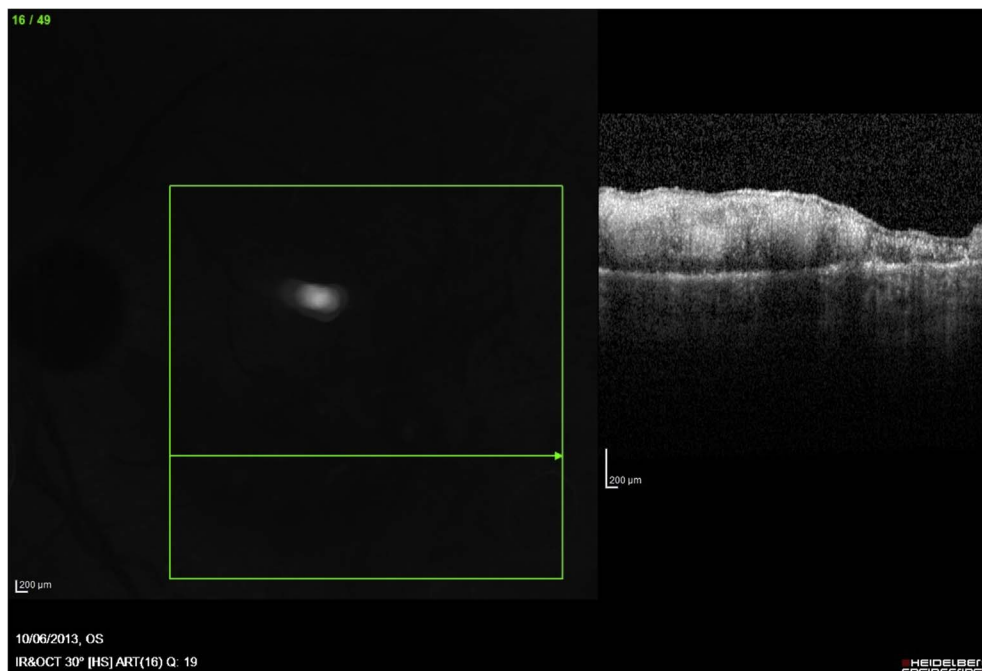


Fig. 2. SD-OCT of the lesion. Note the full-thickness hyperreflectivity of the retina without individualization of the layers, except for the RPE layer. There is a significant loss of the ellipsoid zone. An epiretinal membrane can be observed.

Download English Version:

<https://daneshyari.com/en/article/8791104>

Download Persian Version:

<https://daneshyari.com/article/8791104>

[Daneshyari.com](https://daneshyari.com)