



Case report

Lagophthalmos caused by cicatricial adhesion of orbital adipose tissue to orbital roof: A case report

Yoshiyuki Kitaguchi, Jacqueline Mupas-Uy, Yasuhiro Takahashi, Hirohiko Kakizaki*

Department of Oculoplastic, Orbital & Lacrimal Surgery, Aichi Medical University Hospital, Aichi, Japan

ARTICLE INFO

Keywords:

Lagophthalmos
Cicatricial adhesion
Orbital adipose tissue
Orbital roof
Dermis-fat graft

ABSTRACT

Purpose: To report a case of lagophthalmos caused by cicatricial adhesion of orbital adipose tissue to the orbital roof.

Observations: A 23-year-old female was presented with right lagophthalmos. Five months prior to consult at our clinic, she suffered from a penetrating trauma to the frontal lobe of the brain through the right orbital roof with cerebrospinal fluid leakage. Decompressive craniectomy was performed immediately after the injury using a coronal incision, which was followed by reconstruction with an artificial bone 1 month later. On examination at our clinic, she showed right exposure keratopathy with best corrected visual acuity of 20/100 due to corneal opacity. The palpebral contracted scar was first elongated using Z-plasty technique but excursion of the upper eyelid under a finger force assistance was insufficient to eliminate lagophthalmos. However, complete eyelid closure under a finger force assistance was achieved after sharp dissection of the cicatrized adipose tissue from the orbital roof. An autogenous dermis-fat was grafted on the orbital roof and superior orbital rim to avoid adhesion of orbital adipose tissue onto the bone again.

Conclusion and importance: Cicatricial adhesion of an orbital adipose tissue to the orbital roof is one of the possible causes of posttraumatic lagophthalmos in patients with an orbital roof fracture. Surgeons need to be aware of this condition in planning of surgical repair when such a fracture is encountered.

1. Introduction

Lagophthalmos caused by cicatricial adhesion is one of the most challenging conditions for oculoplastic surgeons.¹ It is not easy to obtain optimal functional and aesthetic results. Insufficient treatment potentially causes vision loss due to severe corneal damage.¹

The total excision of the scar tissue and fat grafting are the core treatment to cicatricial tissue revision.² Contracted scars in the skin, orbicularis oculi muscle, tarsal plate and levator muscle are well-known causes of lagophthalmos.¹ An orbital roof fracture has also been reported to be an infrequent cause of lagophthalmos,³ but its clinical characteristics have not been well documented. We report a case of lagophthalmos after a penetrating trauma to the frontal lobe of the brain including the orbital roof.

2. Case report

Institutional review board approval and written patient consent to publish case details such as photographs in the case report have been obtained.

A 23-year-old woman underwent a traffic accident 5 months ago. A 5 cm long glass fragment stuck into the frontal lobe of the brain through the right orbital roof with cerebrospinal fluid leakage (Fig. 1A and B). This was removed, and a decompressive craniectomy was performed using a coronal incision (Fig. 1C). She also had corneal and scleral lacerations, which were concurrently repaired by sutures. The frontal bone defect was reconstructed using a custom-designed porous hydroxyapatite plate (Apaceram®, HOYA Technosurgical Inc., Tokyo, Japan) and a calcium phosphate cement (BIOPEX®-R, HOYA Technosurgical Inc., Tokyo, Japan) one month later (Fig. 1D).

She was referred to our hospital for treatment of the right lagophthalmos (Fig. 2A and B). At the initial visit, she showed a right exposure keratopathy with best corrected visual acuity of 20/100 due to corneal opacity. Upper eyelid scar extended to the glabellar area longitudinally along the fracture line of the frontal bone. On physical examination, infraorbital subcutaneous tissue was firmly cicatrized to the superior orbital rim, which interfered with closure of the upper eyelid. The distance from the upper eyelid margin to the lower border of the brow was 20 mm on the mid-pupillary line, whereas it was 28 mm on the contralateral side. She also had a notch of the upper eyelid margin

* Corresponding author. Department of Oculoplastic, Orbital, and Lacrimal Surgery, Aichi Medical University Hospital, 1-1 Yazakokarimata, Nagakute, Aichi 480-1195, Japan.
E-mail address: cosme@d1.dion.ne.jp (H. Kakizaki).

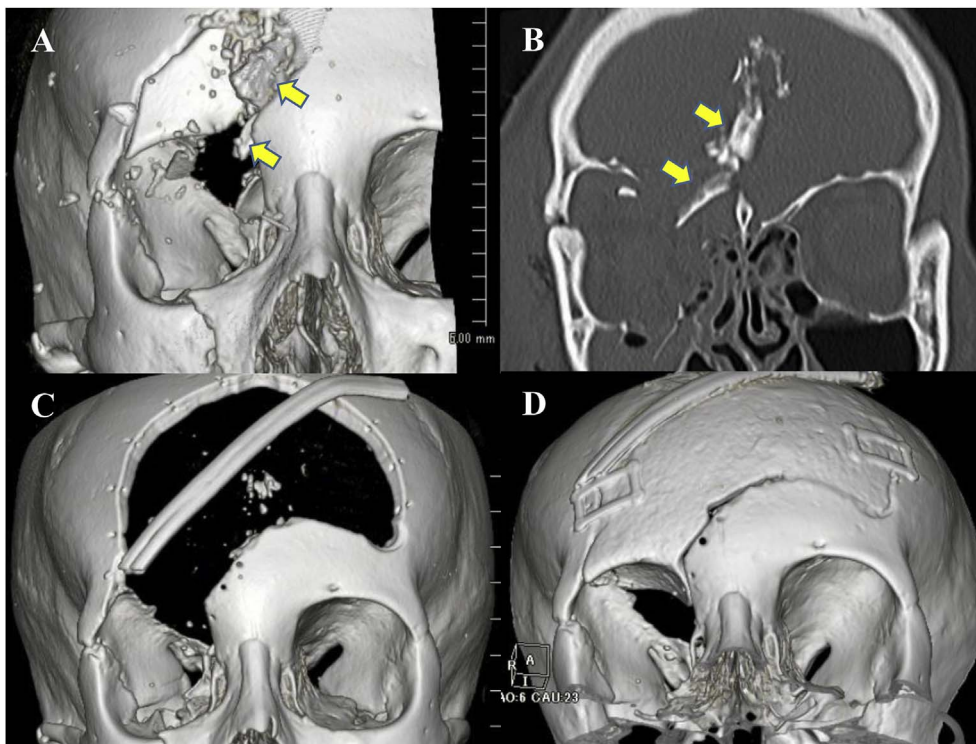


Fig. 1. Injury of the skull base assessed by computed tomography. (A, B) A shard of glass (arrows) getting stuck in the frontal through the right orbital roof. (C) After decompressive craniectomy. (D) Reconstructed orbital roof with an artificial bone.

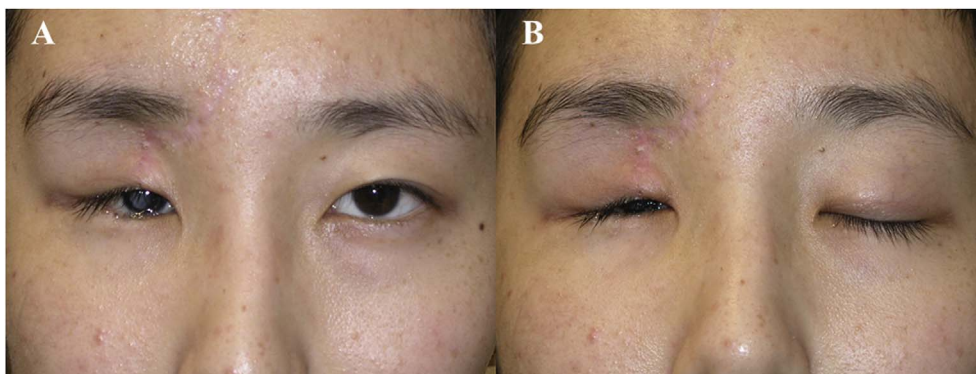


Fig. 2. Pre-operative face photos. (A) Eye opening. (B) Eye closing.

with a symblepharon in the superior fornix.

Surgery was performed under general anesthesia with local anesthetic injection (1% lidocaine and epinephrine diluted to 1:100000). The palpebral contracted scar was first elongated using Z-plasty technique (Fig. 3A). However, excursion of the upper eyelid under a finger force assistance⁴ was insufficient to eliminate lagophthalmos. After undermining the suborbicularis plane to the superior orbital rim, the scar extended deep to the orbital roof along the interface of the artificial bone. The scar was sharply dissected leaving thin tissue on the surface of the artificial bone (Fig. 3B). There was no exposure of the levator palpebrae superioris (LPS) muscle or leakage of cerebrospinal fluid during this procedure. After lysis of the scar, the upper eyelid completely closed with a finger force assistance.⁴

An autogenous abdominal dermis-fat graft was harvested and divided into two pieces; one graft was put beneath the orbital roof; and the other one was set on the superior orbital rim and was fixed with the skin orbicularis layer.

After an excision of the symblepharon, a lamellar pentagonal wedge resection was done to excise the eyelid margin notch (Fig. 3C).⁵

Five months postoperatively, although lagophthalmos slightly recurred (Fig. 4A and B), exposure keratopathy improved. The distance between the upper eyelid margin and the lower border of the brow hair

was extended to 27 mm, which was sufficient for eyelid closure.

3. Discussion

We report a case of lagophthalmos caused by a cicatricial adhesion of an orbital adipose tissue to the orbital roof. Lagophthalmos is a rare complication in cases with orbital roof fracture,^{3,6} in which impingement of bone fragments usually causes upward movement restriction of the LPS and/or the superior rectus muscle.⁶ A downward movement is rarely restricted except in cases with muscle incarceration.⁷ In addition, as we intraoperatively obtained complete eyelid closure without exposure of the LPS muscle, possible scarring in the LPS muscle may not largely influence development of lagophthalmos in this case.

Pre- and intraoperative considerations to surgical plan are essential to the improvement of lagophthalmos in cases with an extensively traumatized orbit. Contracted eyelid scars strongly draw attention as the cause of lagophthalmos. However, the previous history of penetrating foreign body injury, neurosurgical reconstruction, and the use of a porous artificial bone allows preoperative speculation of the cicatricial adhesion extended deeply in the reconstructed orbital roof, leading to appropriate surgical management.

The intraoperative quantification by finger force was helpful to

Download English Version:

<https://daneshyari.com/en/article/8791119>

Download Persian Version:

<https://daneshyari.com/article/8791119>

[Daneshyari.com](https://daneshyari.com)