

# Cost analysis of remote telemedicine screening for retinopathy of prematurity

Maram Isaac, MBBS, MHA,\* Wanrudee Isaranuwachai, PhD,<sup>†,‡</sup>  
Nasrin Tehrani, MBBCh, FRCSC\*<sup>§</sup>

## ABSTRACT •

**Objective:** To compare costs of 2 screening modalities for retinopathy of prematurity (ROP): telemedicine imaging with remote interpretation versus in-person binocular indirect ophthalmoscopy (BIO).

**Design:** Retrospective chart review.

**Participants:** Infants from an existing telemedicine screening program at 2 cities in Ontario, Canada.

**Methods:** We conducted a cost analysis comparison from the perspective of the Ministry of Health. Patient level data was used for the telemedicine group. A hypothetical control group consisted of the minimum number of BIO and interhospital transfers if the existing patients were screened in person. Costs included in-person examinations, transfers, setting up, and ongoing costs of telemedicine screening. Costs were compared using the Mann–Whitney *U* test and are reported in 2014 Canadian dollars.

**Results:** A total of 102 and 72 infants were screened from Sudbury and Barrie, respectively; 3% and 2% of infants in the telemedicine group were transferred for BIO from Sudbury and Barrie, respectively. All infants in the control group would have required at least one transfer for BIO. The average total cost per eye examination was \$4855 ± \$5616 and \$4540 ± \$3129 for the telemedicine group and \$19 834 ± \$13 814 and \$2429 ± \$1664 for the control group from Sudbury and Barrie, respectively ( $p < 0.001$ ). Interhospital transfer cost for the control group was \$19 489 ± \$13 605 and \$2055 ± \$1471 compared to \$635 ± \$3968 and \$30 ± \$197 for the telemedicine group ( $p < 0.001$ ) in Sudbury and Barrie, respectively.

**Conclusions:** Telemedicine appears to be an economically attractive option depending on the location and number of infants screened. This information is useful for planning similar ROP screening programs.

Retinopathy of prematurity (ROP) is a vasoproliferative disorder of the developing retina that occurs primarily in low-birth-weight premature infants. Severe ROP may lead to blindness. It is estimated that 50 000 children are blind as a result of ROP worldwide.<sup>1</sup> Timely screening is critical for early detection of severe ROP that requires treatment.<sup>2,3</sup> The Cryotherapy for Retinopathy of Prematurity (CRYO-ROP) trial reported beneficial treatment effects for severe ROP.<sup>4</sup> Furthermore, the Early Treatment for Retinopathy of Prematurity (ETROP) study showed that earlier treatment with laser photocoagulation before diagnosis of threshold disease for high-risk infants resulted in significantly lower unfavourable structural and visual acuity outcomes.<sup>4,5</sup> Therefore, the increasing need for appropriate ROP screening in many countries has resulted in the emergence of application of telemedicine in combination with digital fundus cameras that can capture wide-field retinal images. Experts at a central reading site review and interpret images obtained by nurses or technicians, thus bringing ROP screening to remote and/or underserved areas around the world. This allows highly accurate detection of disease that requires treatment.<sup>6–11</sup>

In view of growing health care expenses and limited resources, it is important to identify costs associated with telemedicine screening programs for ROP. Despite the scarcity of evidence, the available studies support the

economic value of telemedicine screening for ROP.<sup>7,12,13</sup>

The purpose of this study is to compare the costs of 2 screening modalities: digital fundus images obtained by nonophthalmic personnel with remote interpretation by an ophthalmologist using telemedicine versus in-person binocular indirect ophthalmoscopy (BIO). Cost analysis is performed separately for 2 remote cities in Ontario, Canada: Health Sciences North (HSN) in Sudbury and Royal Victoria Hospital (RVH) in Barrie. The Hospital for Sick Children (SickKids) in Toronto is the central reading site.

## METHODS

### Description of Ontario Telemedicine for Retinopathy of Prematurity (ONTROP) Network

HSN is located approximately 400 km from SickKids in Sudbury. RVH is located 90 km north of Toronto in Barrie. Both HSN and RVH operate advanced modified level III neonatal intensive care units (NICUs).<sup>14</sup> Both NICUs have no access to ophthalmologists with expertise in ROP screening locally. To improve access to ophthalmic care, a pilot program for remote screening of ROP using a live 2-way audio-video connection with digital fundus imaging was set up in Ontario in 2009 using the Ontario Telemedicine Network, a secure internet-based

© 2017 Canadian Ophthalmological Society.

Published by Elsevier Inc. All rights reserved.

<http://dx.doi.org/10.1016/j.jcjo.2017.08.018>

ISSN 0008-4182/17



connection.<sup>9</sup> HSN was identified as the neonatal unit with the greatest need. The program expanded in 2010 to include RVH. An imaging teaching program was devised to train nurses without prior expertise in ophthalmic imaging on the use of the digital fundus camera, RetCam (Clarity Medical Systems [CMS]), Pleasanton, Calif.). The training schedule included an online training module on RetCam, on-site training by a CMS specialist, and hands-on training onsite using mannequin infant eyes. A day of teaching at SickKids' NICU and ROP outpatient clinic was also provided. Subsequently, telemedicine examinations were started at each site with ongoing supervision of the process through the video connection by the ophthalmologist at SickKids for the first 6 months.

Before each telemedicine examination, infants were bundled and received topical anaesthesia, oral sucrose, and non-nutritive sucking. Monitoring was performed by pulse-oximetry. Video camera on mobile video teleconferencing unit was positioned to allow direct guidance from SickKids' ophthalmologist for adjustment of light and focusing parameters to ensure adequate imaging of retina. Nurses then selected images from saved video following the PHOTO-ROP study imaging protocol.<sup>15</sup> Images were uploaded to a secure server at SickKids and evaluated using reviewing software (Clarity Medical Systems) that allows image processing to facilitate image analysis. In cases of inadequate image quality, repeat imaging was requested within a week. A final report and management plan was faxed back to remote sites within 24 hours. Screening and follow-up imaging were planned according to current guidelines.<sup>2,3</sup> Figure 1 shows the screening schedule with telemedicine.

If no ROP was detected, imaging was repeated every 2 weeks. If stage 1 or 2 ROP was diagnosed, repeat imaging was performed every week. Transfer to SickKids for BIO within a week was arranged for referral-warranted ROP (RW-ROP) defined as any ROP in zone I, diagnosis of plus disease, or stage 3 or worse.<sup>16</sup> Final discharge from ROP screening is dependent on confirmation of vascularization into zone III and absence of severe ROP. Because there were no local ophthalmologists who could provide ROP screening, these infants had to be brought by their families to the SickKids outpatient ophthalmology clinic after being discharged home from the NICU. A final in-person BIO examination with scleral depression would allow safe discontinuation of ROP screening as it is difficult to image zone III with RetCam.

### Description of Patients

The telemedicine group included retrospective patient-level data from ONTROP records of all infants screened between 2009 and 2014 for Sudbury and between 2010 and 2014 for Barrie. The study was approved by SickKids' research ethics board. The analysis time frame was from first screening until discharge from the ROP screening

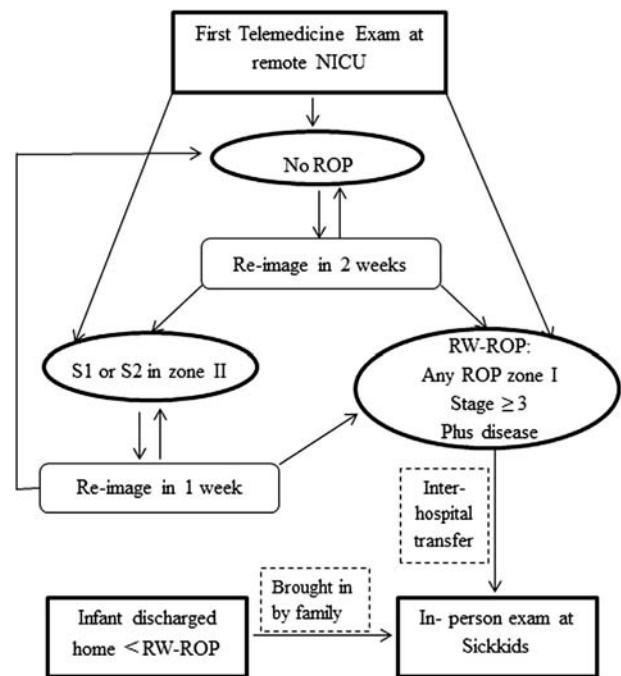


Fig. 1—Retinopathy of prematurity (ROP) screening schedule via telemedicine while in neonatal care unit and after discharge home. Three possible pathways are described below depending on severity of ROP on the first telemedicine examination. S1, stage 1; S2, stage 2; RW-ROP, referral warranted retinopathy of prematurity.

program or until diagnosis of RW-ROP. Data on severity of ROP at each examination and at final BIO were collected for each infant. Demographic data on birth weight, gestational age, and sex were recorded.

To compare the 2 screening modalities, we created a *hypothetical* control group for in-person BIO screening using current screening guidelines and expert opinion.<sup>2</sup> The hypothetical control group consisted of only BIO examinations for the same group of patients if there was no telemedicine screening. An estimate of the minimum number of BIO examinations each patient would have undergone if screened in person and not through ONTROP was generated, with a corresponding number of transfers from the remote site to SickKids hospital. For example, if we had 102 infants who were screened by telemedicine, we would create 102 infants for the hypothetical control group who could be screened only in person. The estimated number of BIO examinations was based on review of each patient's data on disease severity and progression by 2 ophthalmologists (M.I. and N.T.) at each examination.

In constructing the hypothetical group, we followed a conservative approach; we used the absolute minimum number of required in-person visits rather than substituting an in-person examination for every telemedicine examination. This would help to minimize any possibility of overestimation of the number of in-person examinations and the number of transfers in the hypothetical

Download English Version:

<https://daneshyari.com/en/article/8791697>

Download Persian Version:

<https://daneshyari.com/article/8791697>

[Daneshyari.com](https://daneshyari.com)