



Case report

Fungal keratitis caused by rare organisms

Seyed Ali Tabatabaei^a, Mehdi Tabatabaei^a, Mohammad Soleimani^{a,*}, Zahra Fallah Tafti^b^a Eye Research Center, Farabi Eye Hospital, Tehran University of Medical Sciences, Tehran, Iran^b Razi Eye Clinic, Tehran, Iran

Received 26 December 2016; revised 2 August 2017; accepted 4 August 2017

Available online ■ ■ ■

Abstract

Purpose: To report two rare cases of filamentous fungal keratitis.**Methods:** Two non-consecutive patients presented with suspicious fungal keratitis. After performing the smear and culture, medical therapy was started for them. They underwent slit photography and in vivo confocal microscopy (IVCM) in their follow-up visits.**Results:** The patients were 33-year-old and 56-year-old farmer men. They both mentioned a history of ocular trauma by plants. During their follow-up visits, corneal infiltration density and fungal hyphae density decreased in slit-lamp biomicroscopy and IVCM, respectively. The corresponding organisms were *Pseudallescheria boydii* (*P. boydii*) and *Colletotrichum coccodes*.**Conclusions:** It is important to be aware of these rare organisms and their antibiotic susceptibility. There was not any specific confocal feature for the presented fungal keratitis that was different from other filamentous fungal hyphae; however, confocal scan is a good choice to follow the response to the treatment.Copyright © 2017, Iranian Society of Ophthalmology. Production and hosting by Elsevier B.V. This is an open access article under the CC BY-NC-ND license (<http://creativecommons.org/licenses/by-nc-nd/4.0/>).**Keywords:** Fungal keratitis; *Pseudallescheria boydii*; *Colletotrichum coccodes*

Introduction

Microbial keratitis is one of the major causes of ocular morbidity and a potentially leading cause of blindness. It is reported that in warm, tropical climates, 30–62% of all microbial keratitis cases are caused by fungi,^{1–3} but they are rare in regions with temperate climates.⁴ Trauma with plants is one of the main predisposing factors in fungal keratitis.^{1–4} Common causes include *Candida* spp., *Fusarium* spp., and *Aspergillus* spp.⁵

The standard diagnostic methods for infectious keratitis, including fungal keratitis, are corneal smear and culture. However, it may take several days to obtain the result of a corneal culture from a patient with suspicious fungal keratitis. On the other hand, the result could be negative in cases with deep infiltrates.⁶ It is obvious that the sooner diagnosis of causative agent, the better the prognosis.

Conflicts of interest and source of funding: None.

* Corresponding author.

E-mail address: Soleimani_md@yahoo.com (M. Soleimani).

Peer review under responsibility of the Iranian Society of Ophthalmology.

In clinical examination, they are usually determined by gray-white infiltrates and satellite lesions with feathery borders, but it is not a perennial finding.

Considering long time to obtain culture results and variable clinical pictures, it is wise to use other diagnostic methods such as in vivo confocal microscopy (IVCM) with the resolution of 1 μm.^{7,8} This resolution is enough to show fungal hyphae that are larger than a micrometer. IVCM is useful in diagnosis, management, and follow-up of patients with fungal keratitis.⁹

In this report, we want to report two patients with fungal keratitis caused by rare molds.

Case reports

Case 1

A 33-year-old male farmer was referred to our emergency department with the impression of microbial keratitis. He mentioned a history of ocular trauma with herbal material 5 days earlier.

<http://dx.doi.org/10.1016/j.joco.2017.08.004>2452-2325/Copyright © 2017, Iranian Society of Ophthalmology. Production and hosting by Elsevier B.V. This is an open access article under the CC BY-NC-ND license (<http://creativecommons.org/licenses/by-nc-nd/4.0/>).Please cite this article in press as: Tabatabaei SA, et al., Fungal keratitis caused by rare organisms, Journal of Current Ophthalmology (2017), <http://dx.doi.org/10.1016/j.joco.2017.08.004>

On clinical examination, his best corrected visual acuity without any glasses was counting fingers from 50 cm. On slit-lamp biomicroscopy, he had a superficial corneal infiltration with epithelial defect and feathery border. Its diameter was 5 mm, and there was a deeper infiltration with 6.5 mm diameters of infiltration (Fig. 1). Corneal scraping was done with a surgical blade, and mycelium was seen. Samples were taken on sabouraud agar, blood agar, and chocolate agar media and were sent to laboratory for culture and defining the organism.

Based on clinical picture and the result of corneal scraping fortified topical voriconazole, topical levofloxacin and oral itraconazole 100 mg were started hourly, every 4 hours and every 12 hours for the patient, respectively. Clinical signs and symptoms of the patients improved with medical therapy. Considering clinical improvement, the anti-microbial therapy was tapered down, and non-preserved lubricating agents were added.

20 days after initiating medication, the patient developed a 1.5 mm hypopyon, but the corneal infiltration was reducing. Despite formation of the hypopyon, medical regimen did not change. The patient underwent IVCM (Heidelberg engineering, Heidelberg, Germany) weekly. He had hyper-reflective linear, branching and interlocking structures typical of fungal hyphae in IVCM that reduced in density with therapy

(Fig. 2). When the patient developed hypopyon, the density of hyphae in IVCM was just reducing. Seven days after corneal sampling, the organism was defined by culture, and it was *Pseudallescheria boydii* (*P. boydii*). The topical voriconazole was tapered from hourly in the first week to every six hours in the fifth week, when it was discontinued because of resolving the infiltration and scar formation. Systemic itraconazole were discontinued after two weeks.

Case 2

A 56-year-old male farmer came to our emergency department with chief complaint of ocular pain and burning. He had minimal ocular trauma with rice plant one week earlier. He was not a contact lens user.

His best corrected visual acuity was 20/40 without glasses. On slit-lamp biomicroscopy he had conjunctival injection, and there was an area of corneal infiltration in infranasal quadrant with gritty appearance and feathery border. The diameter of infiltration was 3.5*2 mm (Fig. 3). In corneal scraping samples that were obtained with surgical blade, mycelium was seen. Topical natamycin every 1 hour and topical levofloxacin every 4 hours were started for the patient with the impression of fungal keratitis. Clinical signs and symptoms were improved

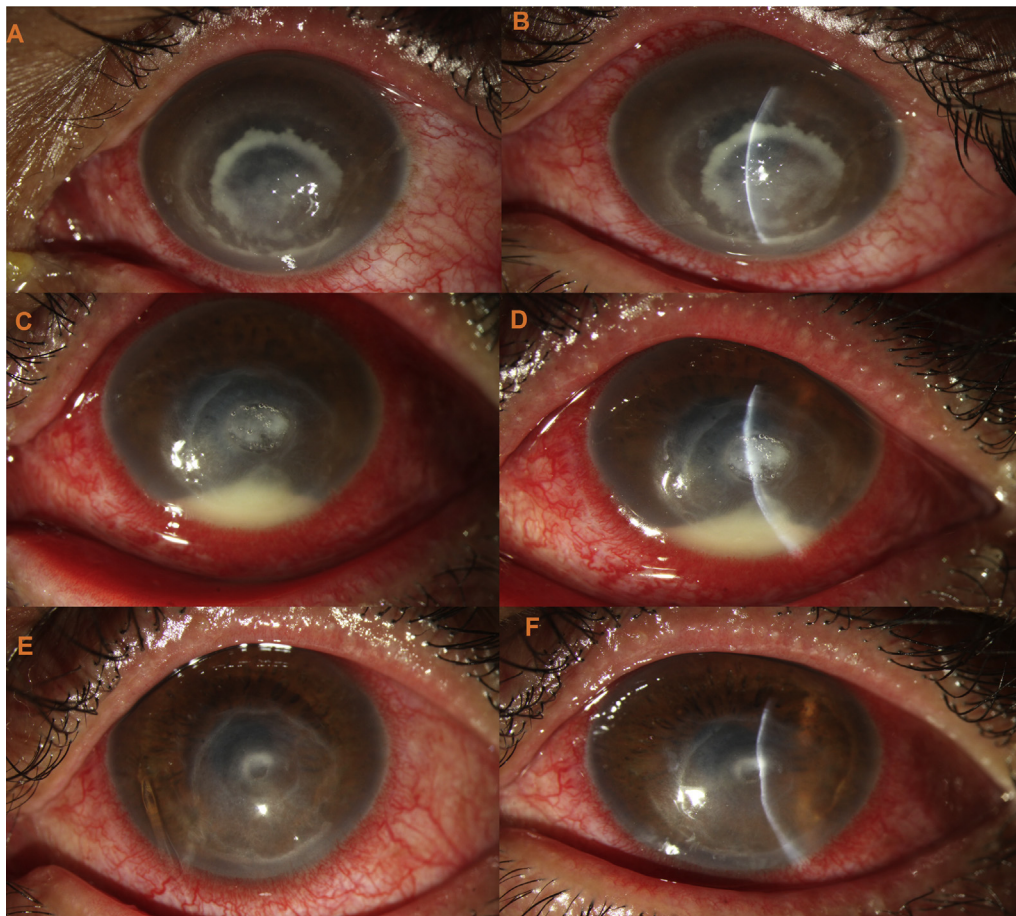


Fig. 1. Clinical picture of the case 1. A, B: clinical picture of the patient at presentation. C, D: the patient developed hypopyon 20 days after initiating medication, but the density of infiltration was reducing. E, F: the infiltration is almost cleared with a central thinning.

Download English Version:

<https://daneshyari.com/en/article/8793201>

Download Persian Version:

<https://daneshyari.com/article/8793201>

[Daneshyari.com](https://daneshyari.com)