

Case report

Optic nerve glioma with complete intraocular extension

Masoomeh Eghtedari^a, Seyede Fariba Fattahi^{a,*}, Naser Owji^a, Mohammad Javad Ashraf^b,
 Mohammad Reza Khalili^a, Bita Geramizadeh^c

^a Poostchi Eye Research Center, Department of Ophthalmology, Shiraz University of Medical Sciences, Shiraz, Iran

^b Pathology Department, Khalili Hospital, Shiraz University of Medical Sciences, Shiraz, Iran

^c Pathology Department, Namazi Hospital, Shiraz University of Medical Sciences, Shiraz, Iran

Received 11 April 2016; revised 2 July 2016; accepted 2 July 2016

Available online ■■■

Abstract

Purpose: To present a rare presentation of optic nerve glioma (ONG) with total intraocular extension.

Methods: A 44-year-old man with a history of loss of vision since childhood and recent development of progressive disfiguring proptosis was referred.

Results: The vision in the affected eye was no light perception, and a proptosis of about 2–3 mm was present. Computed tomography and Magnetic Resonance Imaging (MRI) of brain/orbit showed a fusiform enlargement of the left optic nerve and total filling of vitreous cavity by a mass with high signal intensity in T2-weighted MRI. There was no extension into the intracranial cavity. The patient also had no signs of neurofibromatosis. Histopathology confirmed the diagnosis of ONG of the left orbit with extension into the globe and filling vitreous cavity.

Conclusion: ONG may extend to the vitreous cavity with no simultaneous intracranial involvement.

Copyright © 2016, Iranian Society of Ophthalmology. Production and hosting by Elsevier B.V. This is an open access article under the CC BY-NC-ND license (<http://creativecommons.org/licenses/by-nc-nd/4.0/>).

Keywords: Optic nerve; Glioma; Intraocular tumor

Introduction

Optic nerve glioma (ONG) is the most common primary tumor of the optic nerve and is usually detected during the first decade of life. The characteristic of ONG is indolent growth with alternating periods of inactivity and growth with rare cases of spontaneous tumor regression.¹ It usually occurs in the extra-ocular region of the optic nerve.² ONG arises predominantly between the globe and the orbital apex. The tumor usually remains confined to the orbit or occasionally extends toward the orbital apex with subsequent involvement of the

chiasm and other parts of brain such as the hypothalamus. To the best of our knowledge, only a handful of cases of ONG with intraocular extension have been reported.^{3–5}

Herein, we present a 44-year-old man with an ONG extended into the globe filling the vitreous cavity.

Case report

The patient was a 44-year-old man with a history of loss of vision since childhood. He did not seek medical assistance until the age of 44, when he developed proptosis and eye disfigurement progressively (Fig. 1A). The affected eye had no light perception. In ophthalmologic examination, the right eye had no remarkable pathology, but the left eye had about 2–3 mm proptosis measured by exophthalmometer. In slit lamp examination, he had whitish opacification of the cornea. Scleral thinning and blue hue from uveal tissue were also seen. However, details of anterior chamber, lens, and posterior

No Conflict of interest was declared. No financial support received for this submission.

* Corresponding author. Poostchi Eye Research Center, Zand St, Shiraz, Iran.

E-mail address: fariba.fatahi@gmail.com (S.F. Fattahi).

Peer review under responsibility of the Iranian Society of Ophthalmology.

<http://dx.doi.org/10.1016/j.joco.2016.07.001>

2452-2325/Copyright © 2016, Iranian Society of Ophthalmology. Production and hosting by Elsevier B.V. This is an open access article under the CC BY-NC-ND license (<http://creativecommons.org/licenses/by-nc-nd/4.0/>).

Please cite this article in press as: Eghtedari M, et al., Optic nerve glioma with complete intraocular extension, Journal of Current Ophthalmology (2016), <http://dx.doi.org/10.1016/j.joco.2016.07.001>

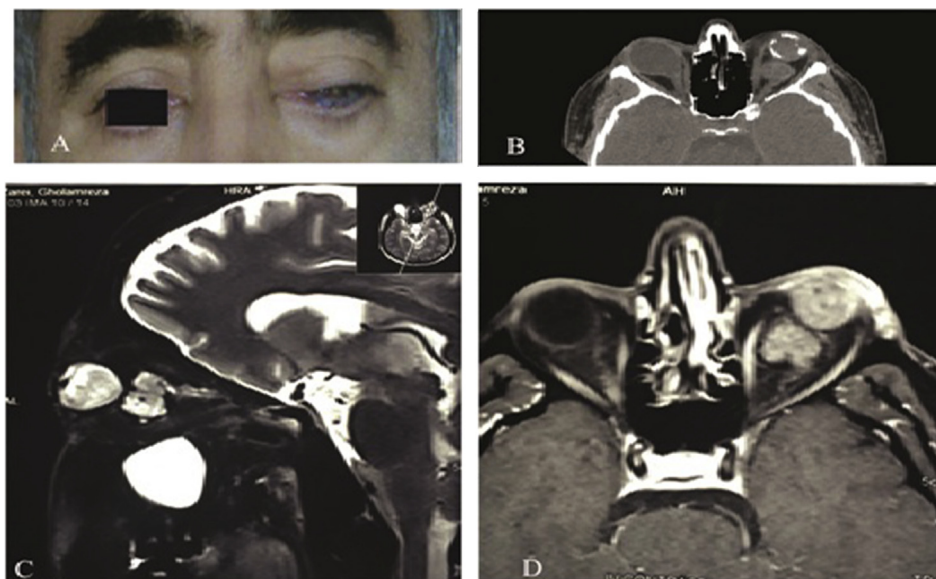


Fig. 1. A: Left eye disfigurement. B: Orbital CT scan shows fusiform enlargement of optic nerve and tumor occupying vitreous cavity with calcification. C: sagittal brain MRI T2 weighted. D: Axial post-contrast T1 weighted MRI with fat suppression. C and D show extent of the tumor and absence of intracranial extension.

segment were not visible due to severe corneal opacification. Computerized tomography (CT) scan and Magnetic Resonance Imaging (MRI) showed a fusiform mass behind the globe with high intensity signal in T2 weighted images (Fig. 1, B–D) which is characteristic of ONG.³

Enucleation was performed. The globe and retrobulbar mass were excised and underwent histopathological evaluation. Gross evaluation of the specimen revealed smooth and fusiform enlargement of the optic nerve as well as a homogeneous solid mass filling almost all of the vitreous cavity (Fig. 2).

Microscopic examination of the Hematoxylin & Eosin slides of the tumor under light microscope (Olympus, Model BX51) showed a coarsely reticulated and myxomatous pattern of spindle-shaped cells, some of which contained cytoplasmic eosinophilic structures compatible with Rosenthal fibers (Fig. 3A, B) as well as areas of mucinous material accumulation (Fig. 3C) and presence of focal calcification that is a sign of long-lasting tumor (Fig. 3D). The tumor was juvenile pilocytic astrocytomas, grade I, according to the World Health Organization [WHO] classification. Complete effacement of

the optic nerve and vitreous cavity by the tumor was noted (Fig. 2). Furthermore, there was atrophy of iris and absence of normal retina which was completely replaced by the tumor, even though the choroidal tissue was present somewhere (Fig. 3D). Immunostaining demonstrated that the tumor cells were positive for Glial fibrillary acidic protein (GFAP), S100 (focal), and vimentin, negative for cytokeratin, HMB 45, and synaptophysin, and the Ki67 index was low (Fig. 3, E–F).

The patient was evaluated for signs of neurofibromatosis such as cutaneous pigmented macules (cafe-au-lait spots), neurofibromas, iris (Lisch) nodules, and osseous defects involving the orbit. However, no sign was found. There was no sign of recurrence during 9 months of follow-up examinations, and prosthetic eye was successfully fitted. Written informed consent was obtained from the patient.

Discussion

Our patient was a neglected case of ONG with intraocular involvement. Sporadic optic pathway gliomas (OPGs) typically present before age 8. Onset can also occur in the second decade. Presentation of new symptomatic sporadic OPGs in older adults up to the fifth decade have been reported occasionally.⁶ In contrast, malignant optic gliomas of adulthood usually presented with sudden acute visual loss may be associated with neurological symptoms, and it is rare for them to result in proptosis.¹ Our patient had a history of loss of vision since childhood without seeking medical assistance until the age of 44, when he developed progressive proptosis and eye disfigurement. We think this patient may be a neglected childhood benign ONG. However, presentation of a new benign ONG in an older adult is another possibility. The remarkable feature of our case is the rare complete intraocular involvement of the ONG. ONG presenting with

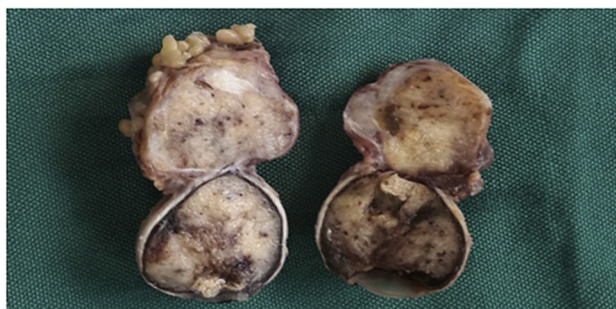


Fig. 2. Complete filling of vitreous cavity by tumor.

Download English Version:

<https://daneshyari.com/en/article/8793323>

Download Persian Version:

<https://daneshyari.com/article/8793323>

[Daneshyari.com](https://daneshyari.com)