

Contents lists available at [ScienceDirect](http://www.elsevier.com/locate/aott)

Acta Orthopaedica et Traumatologica Turcica

journal homepage: <https://www.elsevier.com/locate/aott>

Malignant triton tumor of the gluteal region in a patient unaffected by neurofibromatosis: A case report

Abdullah Merter^{a,*}, Kerem Başarır^b, Yusuf Yıldız^b, Yener Sağlık^b

^a Afsin State Hospital, Orthopedic Clinic, Kahramanmaraş, Turkey

^b Ankara University, School of Medicine, Ibn-i Sina Hospital, Department of Orthopedics, Oncology Section, Ankara, Turkey

ARTICLE INFO

Article history:

Received 8 February 2017

Received in revised form

31 May 2017

Accepted 30 July 2017

Available online xxx

Keywords:

Malignant peripheral nerve sheath tumor

Gluteal region

Triton tumor

ABSTRACT

Malignant triton tumor (MTT) is a rare variant of malignant peripheral nerve sheath tumor (MPNST) made up of both malignant schwannoma cells and malignant rhabdomyoblasts.

A 26-years-old male patient was admitted with an asymptomatic gluteal mass. Magnetic resonance imaging showed heterogeneous soft tissue mass and he underwent open biopsy. Malignant peripheral nerve sheath tumor was diagnosed. He was given adjuvant chemotherapy following the removal of the tumor with hip disarticulation. The tumor was diagnosed as “malignant triton tumor” based on pathological examination including immunohistochemical studies. There were no signs of metastasis but recurrence was observed at 9 months follow up.

MTT is usually associated with Neurofibromatosis 1 and located in head, neck region. In this case sporadic involvement of gluteal region and aggressive behavior of the lesion despite radical surgery was demonstrated.

© 2017 Turkish Association of Orthopaedics and Traumatology. Publishing services by Elsevier B.V. This is an open access article under the CC BY-NC-ND license (<http://creativecommons.org/licenses/by-nc-nd/4.0/>).

Introduction

Malignant “Triton” tumor (MTT) is a rare subtype of malignant peripheral nerve sheath tumor (MPNST) characterized by malignant schwannoma with rhabdomyosarcoma. This composite neoplasm was initially introduced by Masson and Martin in 1938 and this tumor is extremely rare, with fewer than 100 cases reported to date.¹ It occurs predominantly in the head, neck and trunk. The diagnosis based on the presence of rhabdomyoblasts and malignant Schwann cells.² Head and neck region is the most frequent site of involvement with one third of the lesions, followed by trunk and lower extremities respectively.³ Head and neck localization seem to have an infrequent association with Neurofibromatosis-1 (NF1) when compared to other localizations. It is usually seen in individuals younger than 35 years of age MTT carries a much worse prognosis than MPNST with an expected 5-year survival rate of 12.5%.^{4,5} Sporadic involvement of the gluteal region without NF1 hasn't been described yet in the literature.

In this article, we report a case of a Malignant “Triton” tumor in the gluteal region of a male without Neurofibromatosis-1 with 57 months follow up.

Case presentation

A 26-year-old male patient was presented with a 6 months history of right buttock pain that was exacerbated with movement. There was no history of preceding trauma or accident. There was no family history of central nervous system neoplasia or of neurofibromatosis types 1 or 2. The physical examination revealed that a painful limp and pain with deep palpation. His neurologic examination was normal. A radiographic image of the pelvis demonstrated an increase in soft tissue density adjacent to right iliac wing. Magnetic resonance imaging of pelvis demonstrated a large soft tissue mass in the right gluteal region close to the sciatic nerve (Fig. 1). The 5 × 6 × 7 cm mass had low signal intensity on T1, primarily high signal on T2, and diffuse enhancement with gadolinium. There was a central focus of low signal intensity on the T2 and gadolinium-enhanced images (Fig. 2). Open biopsy was performed and histological examination demonstrated a lesion consisted of cells showing either rhabdomyoblastic or neuronal differentiation which was characteristic for malignant triton tumor. Investigations including computerized tomography of thorax ruled out a

* Corresponding author. Yesilyurt Mh. Afsin Devlet Hastanesi, Afsin, Kahramanmaraş, Turkey.

E-mail address: dr.merter@gmail.com (A. Merter).

Peer review under responsibility of Turkish Association of Orthopaedics and Traumatology.

<http://dx.doi.org/10.1016/j.aott.2017.07.005>

1017-995X/© 2017 Turkish Association of Orthopaedics and Traumatology. Publishing services by Elsevier B.V. This is an open access article under the CC BY-NC-ND license (<http://creativecommons.org/licenses/by-nc-nd/4.0/>).

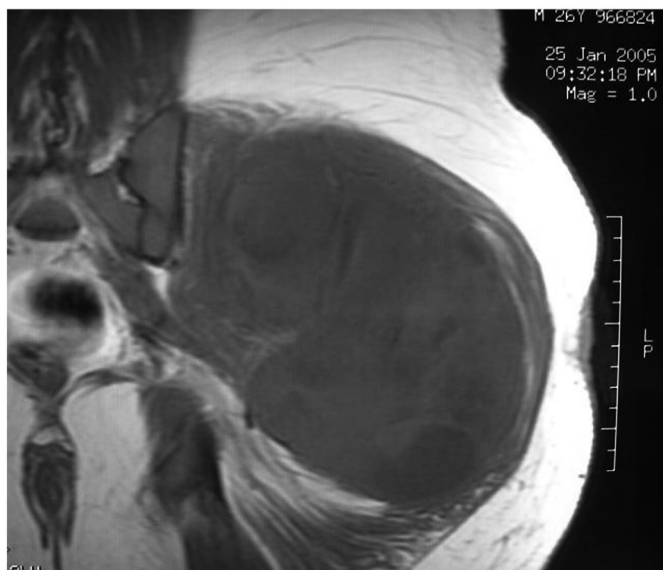


Fig. 1. A large soft tissue mass in the right gluteal region close to the sciatic nerve on T1 sequence.

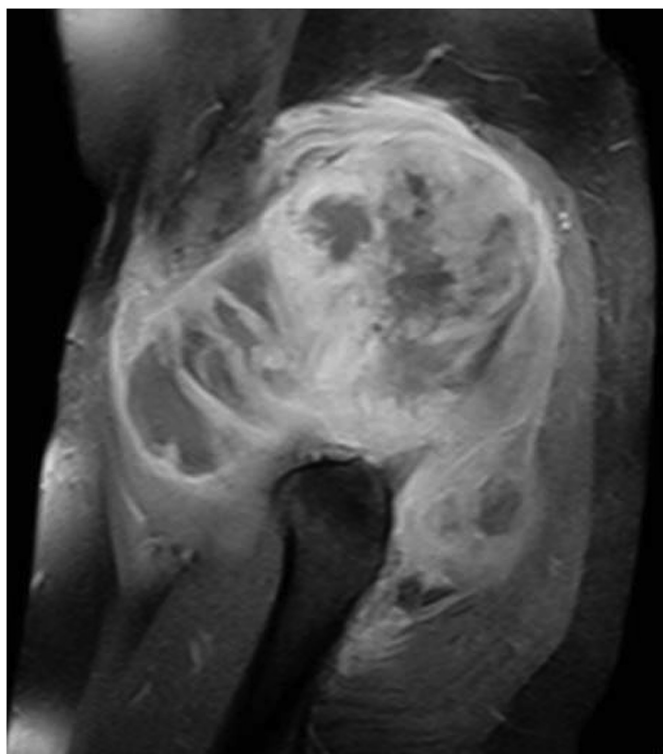


Fig. 2. Central focus of low signal intensity on sagittal T2 sequence.

metastatic disease. The patient subsequently underwent further surgery to ensure full excision of the tumor. A wide resection was performed via hip disarticulation with anterior flap. Postsurgical recovery was uneventful. Microscopical examination revealed numerous large pleomorphic cells with abundant cytoplasm contrasting with the pale staining cytoplasm of the Schwann cells. Immunohistochemical analysis showed S-100, Leu-7, CD57, desmin positivity which was also consistent with the diagnosis of MTT. Surgical margins were clear. Pathological examination including immunohistochemical analysis confirmed the diagnosis of MTT (Fig. 3). He was started on combination chemotherapy of ifosfamide

2 g/m² with mesna 2 g/m² alternating with adriamycin 75 g/m² every other week for first two cycles 4 weeks apart and then continued with ifosfamide and mesna for the rest of the two cycles without adriamycin. The patient was followed up by 6 weekly periods and the surgical field checked with MRI every 3 months. Nine months after initial wide resection, the patient presented with continuing pain. The follow-up MRI demonstrated a 3 × 4 × 1 cm recurrent mass nearby the operative bed of the previously resected lesion. The mass had similar signal characteristics with low signal intensity on T1 and high signal intensity on T2 (Fig. 4). PET/CT scan also demonstrated a recurrent mass in the gluteal region (Fig. 5). Radiation therapy was applied with a total dose of 65.4 Gy, with initial photon fields, followed by shrinking fields with electrons with 33 dose fractions during the course of 2 months. He was underwent second wide resection after radiotherapy. The pathological investigation was the same as the first one and surgical margins were clear. He has followed up in our department and has no evidence of disease recurrence 4 years after his treatment.

Discussion

Malignant peripheral nerve sheath tumor is a neoplasm that arises primarily in the peripheral nerves and accounts for 5–10% of all soft tissue sarcomas.¹ The term Malignant Triton Tumor is used for tumors exhibiting the features of an MPNST and containing rhabdomyoblastic elements.⁴ The disorder was named for the Triton salamander, which is capable of regenerating limbs consisting of both muscle and nerve tissue after the cut end of the sciatic nerve is implanted into the soft tissue of its back.³ The pathogenesis of MTT is unknown, the presence of both neural cells and rhabdomyoblasts have led some to hypothesize that both cellular components derive from less differentiated neural crest cells that have both mesodermal and ectodermal potential and others point out direct evidence for the potential of schwannoma cells to exhibit myogenic differentiation.⁶ Masson and Martin initially postulated that divergent myoid differentiation could occur in neoplastic neuroectodermal cells but there are it seems likely that both cell lines originate from less well-differentiated neural crest cells.^{7,8} Cytogenetic studies reveal certain abnormalities in these tumors including common breakpoints in Chr 7, 11 and loss of Chr 22.^{5,8}

Almost seventy percent of these tumors were diagnosed in patients with von Recklinghausen's disease (NF1) displayed a marked male predominance, young age, and infrequent head and neck presentation, whereas the remaining sporadic 30% were older and

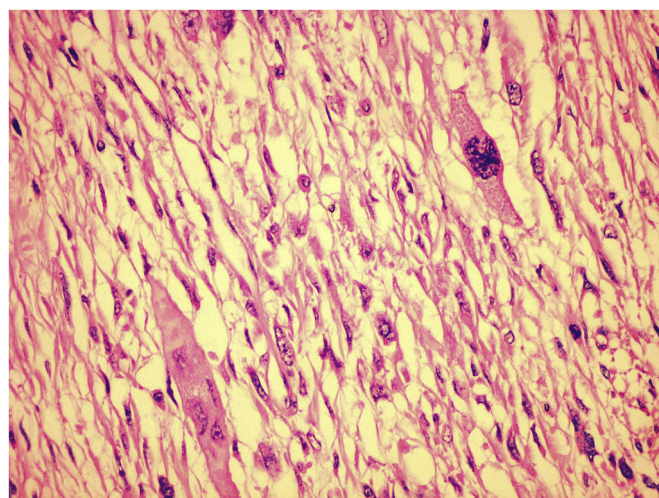


Fig. 3. Microscopic view of excision material.

Download English Version:

<https://daneshyari.com/en/article/8795428>

Download Persian Version:

<https://daneshyari.com/article/8795428>

[Daneshyari.com](https://daneshyari.com)