

Contents lists available at [ScienceDirect](https://www.elsevier.com/locate/aott)

## Acta Orthopaedica et Traumatologica Turcica

journal homepage: <https://www.elsevier.com/locate/aott>

## Anatomic implications of lesser trochanterplasty

Onur Hapa<sup>a</sup>, Nihat Demirhan Demirkıran<sup>a,\*</sup>, Buğra Hüsemoğlu<sup>b</sup>, Mete Edizer<sup>c</sup>, Hasan Havitçioğlu<sup>a</sup><sup>a</sup> Department of Orthopedics, Dokuz Eylul University Hospital, Izmir, Turkey<sup>b</sup> Department of Biomechanics, Dokuz Eylul University Hospital, Izmir, Turkey<sup>c</sup> Department of Anatomy, Dokuz Eylul University Hospital, Izmir, Turkey

## ARTICLE INFO

## Article history:

Received 19 December 2016

Received in revised form

6 October 2017

Accepted 12 November 2017

Available online xxx

## Keywords:

Hip arthroscopy

Iliopsoas muscle

Lesser trochanter

## ABSTRACT

**Objective:** The aim of this study was to measure the area of iliopsoas tendon attachment and the distance of sciatic nerve, medial circumflex femoral artery (MCFA) and quadratus muscle to lesser trochanter tip, before and after 5, 10, 15 mm depth excision of lesser trochanter.

**Methods:** A total 15 hips of 8 adult male cadavers were evaluated. Distances between lesser trochanter tip, sciatic nerve, the lower edge of quadratus muscle and MCFA; length and width of quadratus muscle insertion; area of iliopsoas muscle and quadratus muscle insertion was measured before and after sequential 5,10 and 15 mm depth trochanterplasties using 5 mm wide burr parallel to the posterior cortex.

**Results:** Each incremental 5 mm depth bone removal led to significant decrease of tendon area ( $p=0.001$ ) at each stage. Mean decreases of iliopsoas tendon attachment area with incremental 5 mm burring were  $22\% \pm 10$  with 5 mm,  $50\% \pm 13$  with 10 mm, and  $76\% \pm 13$  with 15 mm of burring.

**Conclusion:** Up to 15 mm lesser trochanter removal did not result in complete detachment of the iliopsoas tendon. Lesser trochanter tip was detected at least 20 mm away from important anatomic structures including quadratus tendon, sciatic nerve, and the medial circumflex femoral artery.

© 2017 Publishing services by Elsevier B.V. on behalf of Turkish Association of Orthopaedics and Traumatology. This is an open access article under the CC BY-NC-ND license (<http://creativecommons.org/licenses/by-nc-nd/4.0/>).

## Introduction

Ischiofemoral impingement (IFI) syndrome is one of the etiologies of hip pain, caused by narrowing between the ischial tuberosity and the lesser trochanter.<sup>1</sup> Two endoscopic techniques of decompression of the lesser trochanter have been described: anterior and posterior.<sup>1,2</sup> Each has advantages and disadvantages. The main structures at risk are the sciatic nerve (SN), the medial circumflex femoral artery (MCFA), the quadratus muscle, and the iliopsoas tendon.<sup>1</sup>

Several recommendations exist in the literature for the quantity of the lesser trochanter to be excised: 5–10 mm or the posterior one-third of the lesser trochanter, or decide according to oblique views.<sup>2,3</sup>

Recently, Gomes-Hoyos et al<sup>4</sup> described the insertional anatomy of the iliopsoas tendon on the lesser trochanter, and they reported that the lesser trochanter had a bald anterior cortical area with no tendinous attachment; they concluded that resection of more than 50% of the tip would partially or completely detach the tendon.

The purpose of the present study was to quantify the area of the iliopsoas tendon attachment before and after a 5-mm, 10-mm, and 15-mm deep excision using a 5-mm wide burr parallel to the posterior cortex and to measure the distance of the SN and MCFA to the lesser trochanter tip, and the dimensions of the quadratus muscle.

The hypothesis was that 5-mm, 10-mm, and 15-mm burring of the lesser trochanter would result in a proportional decrease in the area of the iliopsoas tendon attachment with the tendon still attached after 15 mm of burring.

## Materials and methods

A total of 15 hips of 8 adult, male, formalin-fixed cadavers were evaluated. Study exclusion criteria were any macroscopic evidence

\* Corresponding author. Department of Orthopedics, Dokuz Eylul University Hospital 35340, Balçova, Izmir, Turkey. Fax: +90 232 422 67 70.

E-mail address: [drdemirhandemirkiran@hotmail.com](mailto:drdemirhandemirkiran@hotmail.com) (N.D. Demirkıran).

Peer review under responsibility of Turkish Association of Orthopaedics and Traumatology.

<https://doi.org/10.1016/j.aott.2017.11.006>

1017-995X/© 2017 Publishing services by Elsevier B.V. on behalf of Turkish Association of Orthopaedics and Traumatology. This is an open access article under the CC BY-NC-ND license (<http://creativecommons.org/licenses/by-nc-nd/4.0/>).

of trauma to the hip region. All muscular attachments around the hip region were dissected. The hip capsule was incised. The hip was rotated internally until the entire lesser trochanter was exposed and the tip was vertical to the ground. Next, the quadratus femoris muscle insertion at the trochanteric area was dissected off and the insertion area was marked with a pen. The MCFA was then clarified at the undersurface of the quadratus muscle. The insertion of the iliopsoas muscle at the lesser trochanter was then cut with a surgical blade and the area was marked with a pen. The distance of the lesser trochanter tip to the SN, the lower edge of the quadratus muscle, the MCFA, the length and width of the quadratus muscle insertion, the surface area of the iliopsoas muscle, and the quadratus muscle insertion were measured using Image J, version 1.46, software (National Institutes of Health, Bethesda, MD, USA)<sup>5</sup> (Fig. 1).

A burr, 5 mm in width (Depuy Mitek, Inc., Raynham, MA, USA) was placed on the tip of the lesser trochanter (Fig. 2) and sequential 5-mm, 10-mm, and 15-mm deep trochanterplasties (using the width of the burr as guide for the depth) were performed parallel to the posterior cortex of the femur, and the iliopsoas insertion area was measured at each stage of bone removal (Fig. 3).

### Statistical analysis

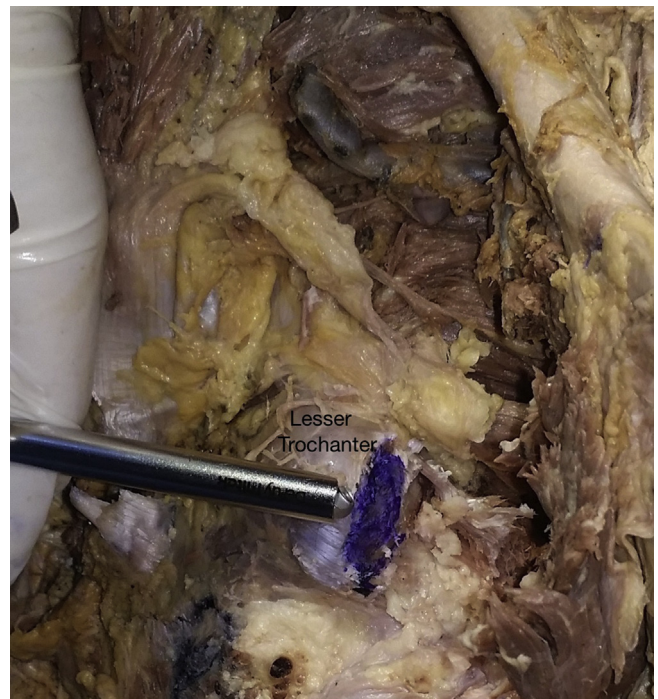
Data analysis was performed using SPSS for Windows, Version 11.5 (SPSS Inc., Chicago, IL, USA). The Wilcoxon signed-rank test was used to detect a side-to-side difference between each cadaver for each variable ( $n = 7$ ), and to determine any difference in the insertion area of the iliopsoas muscle between no burring and 5-mm burring, 5-mm and 10 mm-burring, and 10-mm and 15-mm burring ( $n = 15$ ).

### Results

The results are presented in Tables 1 and 2. The lesser trochanter tip was consistently located posterior-inferior to the inferior attachment site of the quadratus. There were no side-to-side differences in the variables tested, except for the distance of the trochanter to the quadratus tendon ( $p = 0.04$ ) ( $27 \pm 4$  mm vs  $30 \pm 5$  mm). Each incremental 5 mm in depth of bone removal resulted in a significant decrease of tendon area ( $p = 0.001$ ) at each stage.



**Fig. 1.** The iliopsoas and quadratus muscles are elevated and the insertions are marked. (Arrow: medial circumflex femoral artery at the undersurface of the quadratus muscle).



**Fig. 2.** The burr on the tip of the lesser trochanter.

The mean decrease in iliopsoas tendon attachment area with incremental 5 mm of burring was  $22 \pm 10\%$  at 5 mm,  $50 \pm 13\%$  at 10 mm, and  $76 \pm 13\%$  at 15 mm.

### Discussion

The primary findings of this study were that at each 5-mm increase in depth of bone removal, there was a significant proportional decrease in iliopsoas tendon attachment area, with as much as 11% of the tendon still attached at 15-mm burring depth.

Endoscopic or open lesser trochanter excisions are proposed treatment modalities for ischiofemoral excision. Two endoscopic techniques, anterior and posterior, have been described as having the risk of detachment of the iliopsoas tendon and injury to the MCFA, the SN, and the quadratus tendon.<sup>2,3</sup>

In the present study, the mean distance of the lesser trochanter to the MCFA was  $22 \pm 2$  mm. Gautier et al<sup>6</sup> reported a distance of  $18.2 \pm 4$  mm in fresh cadavers (5 male, 7 female). In another study, McCormick et al<sup>7</sup> reported a distance of  $22.9 \pm 5$  mm observed in magnetic resonance arthrograms.

The distance between the SN and the lesser trochanter tip was  $21 \pm 1$  mm in the present study, similar to the results of a study of computed tomography (CT) images conducted by Liu et al,<sup>8</sup> reporting a distance of  $21.2 \pm 5$  mm. The authors noted that CT analysis was performed with the pelvis in the neutral position, with the lower limb placed in internal rotation. However, the distance to the lesser trochanter would probably change according to the rotation of the thigh.<sup>9</sup>

Most recently, Gomes-Hoyos et al<sup>4</sup> described the insertional anatomy of the iliopsoas tendon on the lesser trochanter. In that study, up to 70% of the specimens had a double tendinous footprint (i.e., two separate tendons for the iliacus and the psoas). Our cadavers were observed to be single tendinous, but we did not specifically distinguish or define the 2 tendons with histological studies, as the aim of the study was not to describe the footprint location of the iliopsoas tendon, which has previously been published.<sup>4</sup> In the same study by Gomes-Hoyos et al, the height of the

Download English Version:

<https://daneshyari.com/en/article/8795464>

Download Persian Version:

<https://daneshyari.com/article/8795464>

[Daneshyari.com](https://daneshyari.com)