

Contents lists available at [ScienceDirect](#)

## Acta Orthopaedica et Traumatologica Turcica

journal homepage: <https://www.elsevier.com/locate/aott>

## Results of endoscopically-assisted cubital tunnel release without using any specific instrument

Çağatay Zengin<sup>a, \*</sup>, Mesut Tahta<sup>a</sup>, Özgür Güntürk<sup>a</sup>, Cihan Aslan<sup>a</sup>, Ufuk Şener<sup>b</sup>, Muhittin Şener<sup>a</sup>

<sup>a</sup> Department of Orthopaedics and Traumatology, Izmir Katip Celebi University, Izmir, Turkey

<sup>b</sup> Department of Neurology, Izmir Katip Celebi University, Izmir, Turkey

### ARTICLE INFO

#### Article history:

Received 5 May 2016

Received in revised form

17 July 2016

Accepted 28 August 2016

Available online xxx

#### Keywords:

Cubital tunnel syndrome

Ulnar nerve

Endoscopic decompression

Minimal invasive

### ABSTRACT

**Background:** We aimed to report the clinical and electrophysiological results of patients who were treated with an endoscopically assisted in situ release technique for cubital tunnel syndrome and to show safety and efficacy of this procedure.

**Materials and methods:** Twenty nine patients were included into the study. 13 patients (44.8%) were female, 16 patients (55.2%) were male. The mean age was 44.4 years (range; 22–66 years). Mean follow up period was 16.0 months (range; 7–42 months). We used Dellon classification for preoperative staging, and modified Bishop rating system for the evaluation of postoperative clinical results. Dynamometric and electromyographic measurements were obtained preoperatively and at final control.

**Results:** Preoperative Dellon's classification revealed 3 patients grade 1, 14 grade 2, and 12 grade 3. Modified Bishop score was very good for 21 patients (72.4%), good for 4 patients (13.8%), fair for 3 patient (10.3%), and poor for 1 patient (3.4%). At final control; the mean proportion of grip power and pinch strength of the affected hand to the contralateral normal hand was improved, and also nerve conduction velocity were improved in all patients. As complication, hematoma formation developed in two cases.

**Conclusion:** Our study showed that endoscopically assisted decompression technique without using any special instruments can be performed successfully with a low complication rate. It is a safe and effective method in the treatment of cubital tunnel syndrome.

**Level of evidence:** Level IV, Therapeutic study

© 2017 Turkish Association of Orthopaedics and Traumatology. Publishing services by Elsevier B.V. This is an open access article under the CC BY-NC-ND license (<http://creativecommons.org/licenses/by-nc-nd/4.0/>).

### Introduction

Cubital tunnel syndrome is the second most common entrapment neuropathy and occurs as a result of entrapment of the ulnar nerve at the level of the elbow.<sup>1</sup> It is manifested by pain in the elbow medial condyle area, numbness in the sensory area of the ulnar nerve, weakness in the intrinsic muscles and a loss of grip strength.<sup>2</sup> Both conservative and surgical approaches are used in treatment. In conservative treatment, NSAID and brace may be applied and activities modified.<sup>3</sup> In surgical treatment, in situ decompression of the ulnar nerve or anterior transposition are

widely applied.<sup>3</sup> Although no difference has been found between the results of both surgical techniques, in cases unresponsive to conservative treatment, in situ decompression is preferred because of low morbidity and the small incision made.<sup>4</sup> Endoscopic or endoscopic-assisted in situ decompression has come into widespread use in recent years.<sup>5,6</sup> The use of specific instruments is necessary in both surgical techniques.<sup>5,6</sup>

The aim of this study was to evaluate the efficacy and safety of endoscopic-assisted in situ release made without the use of any specific instruments.

### Material and method

A retrospective evaluation was made of patients who underwent endoscopic-assisted cubital tunnel release surgery for a diagnosis of cubital tunnel syndrome between May 2012 and June

\* Corresponding author.

E-mail address: [zengincagatay@hotmail.com](mailto:zengincagatay@hotmail.com) (Ç. Zengin).

Peer review under responsibility of Turkish Association of Orthopaedics and Traumatology.

<http://dx.doi.org/10.1016/j.aott.2017.02.012>

1017-995X/© 2017 Turkish Association of Orthopaedics and Traumatology. Publishing services by Elsevier B.V. This is an open access article under the CC BY-NC-ND license (<http://creativecommons.org/licenses/by-nc-nd/4.0/>).

2015. Patients were excluded from the study if they had cubitus valgus deformity, degenerative arthritis in the elbow joint, advanced cervical disc problems, preoperative findings of ulnar nerve subluxation, and those receiving anticoagulant treatment or with <6 months postoperative follow-up.

Of 34 patients who underwent surgery and could be contacted by telephone, 29 agreed to participate in the study. These were 16 males and 13 females with a mean age of 44.4 years (range, 22–66 years) and a mean follow-up period of 16 months (range, 7–42 months). In 27 patients, the dominant right hand was involved and in 2 patients, the left hand. All patients were evaluated in respect of systemic additional diseases (diabetes, cardiac diseases, thyroid or kidney disorders). Pre and postoperatively, the patients were questioned about the presence of paresthesia and whether it was continuous, intermittent or absent.

In the preoperative classification of patient symptoms, the Dellon classification was used and postoperatively, the Bishop classification.<sup>7,8</sup> Hand grip strength was measured with a Jamar hand dynamometer (model SH 5001, Saehan Corporation Masan, South Korea) and palmar pinch, key pinch and tip pinch with a Pinchmeter (model SH 5005, Saehan Corporation Masan, South Korea). The values measured were evaluated by comparison with the values of the contralateral healthy hand. Electromyography (EMG) was taken of all patients both preoperatively and at the final follow-up. Patients with nerve conduction velocity (NCV) < 50 m/s in the segment below the elbow were evaluated as cubital tunnel syndrome.<sup>9</sup> The length of the surgical incision was measured with a ruler at the end of the operation in all patients.

The research protocol was approved by the local ethical committee of Izmir Katip Celebi University, Turkey.

#### Surgical technique

All the operations were performed by the same surgeon (MS). A standard 30°, 4 mm endoscope, a 10 cm grooved retractor and 20 cm blunt-tip Metzenbaum surgical scissors were used in the operation. Surgery was applied to the patients under general anesthesia or axillary block. Under tourniquet, the shoulder was taken into external rotation and the elbow joint brought into 90° flexion. An incision of approximately 2.5–3 cm was made posterior to the medial epicondyle so as to be the central point between the olecranon and the medial epicondyle. Subcutaneous tissue was dissected taking care not to damage the medial antebrachial cutaneous nerve. The Osborne ligament was opened longitudinally and the ulnar nerve was released.

A space was made to work between the subcutaneous tissue and the fascia and the grooved retractor was placed in this space. The endoscope was gently placed below the retractor. Under endoscope guidance which was extended as far as 10–12 cm proximally, fascial structures which could create compression on the ulnar nerve, the intermuscular septum and Struthers arch were released with the blunt-tip scissors longitudinally (Fig. 1). In the same way, release was made up to 8–10 cm distally. After release of all potential structural sources of nerve compression, the subluxation/dislocation of the ulnar nerve was tested by flexion and extension of elbow. The tourniquet was opened. After applying strong compression for up to 10 min, the incision was closed. A compressive bandage was applied. On postoperative Day 1, the compressive bandage was removed, elbow range of motion exercises were started and the patient was discharged.

#### Statistical evaluation

All statistical analyses were performed using SPSS version 15.0 (IBM, Armonk, NY). Categorical data are presented as frequencies

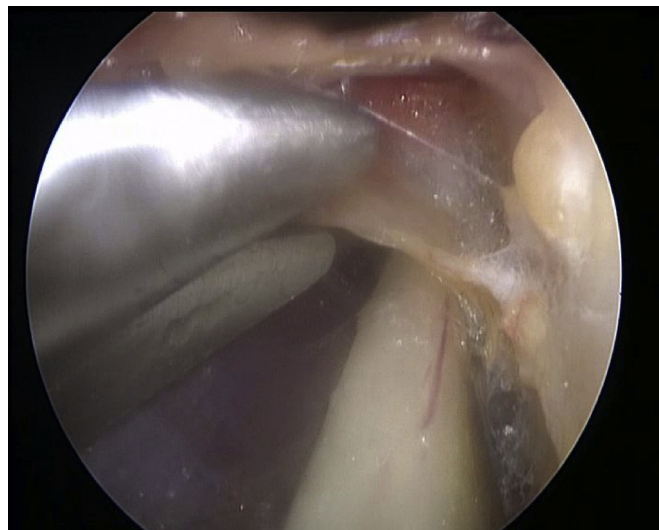


Fig. 1. Endoscopic image of decompression.

and percentages; normally distributed continuous data, as the mean with minimum and maximum values. Wilcoxon signed rank test was used for the comparison of preoperative and postoperative values. Kruskal Wallis test was used for comparison of preoperative Dellon stage and preoperative NCV values. The relation between postoperative Bishop score and postoperative NCV values was assessed by Pearson correlation analysis. In all analysis,  $p < 0.05$  was set as statistically significant with 95% confidence intervals.

#### Results

Paresthesia was present in all patients preoperatively, in a continuous form in 17 (58.6%) and intermittently in 12 (41.4%). At the final follow-up examination, the paresthesia was determined to have persisted in 8 patients (6 intermittent, 2 continuous). Additional diseases such as diabetes mellitus, cardiac and thyroid diseases, were determined in 12 (41.4%) patients. In intraoperative ulnar nerve evaluation none of the patients have findings of subluxation/dislocation.

According to the preoperative Dellon classification, 3 (10.3%) patients were evaluated as Grade 1, 14 (48.3%) as Grade 2, and 12 (41.4%) as Grade 3. In the postoperative Bishop scoring, the results obtained were very good in 21 (72.4%) patients, good in 4 (13.8%), fair in 3 (10.3%) and poor in 1 (3.4%) (Table 1). Hand grip strength was 67.9 preoperatively and 85.5 postoperatively ( $p < 0.01$ ). Palmar pinch increased from 63.4 to 87.4 ( $p < 0.01$ ), key pinch from 65.7 to 86.7 ( $p < 0.01$ ) and tip pinch from 59.5 to 86.2 ( $p < 0.01$ ). The incision length was measured as mean 2.8 cm (range, 2.5–3.4).

In the preoperative electrophysiological examination, the NCV values were <50 m/s below the elbow in all the patients. The NCV value was measured as mean 35.9 m/s (range, 17.2–48.8) preoperatively and mean 45.7 m/s (range, 7.4–66.7) at the final follow-up examination. Although an increase was seen in the postoperative period in all but 2 patients, the values of 13 patients remained below 50 m/s. No relationship was determined between preoperative clinical grading and preoperative electrophysiological values ( $p = 0.293$ ). When the relationship between the postoperative clinical scores and the postoperative electrophysiological values was examined, while a statistically significant relationship was found only in patients with a very good Bishop score. No statistically significant relationship was determined between the postoperative NCV values and other results ( $p = 0.593$ ) (Table 2).

Download English Version:

<https://daneshyari.com/en/article/8795573>

Download Persian Version:

<https://daneshyari.com/article/8795573>

[Daneshyari.com](https://daneshyari.com)