




Contents lists available at ScienceDirect

Arthroplasty Today

journal homepage: <http://www.orthoplastytoday.org/>

Case report

Severe heterotopic ossification and stiffness after revision knee surgery for a periprosthetic fracture

Maher Baroudi, MD^{*}, Pascale Derome, MD, Michel Malo, MD, FRCS(c)

Department of Orthopedic Surgery, Hôpital du Sacré-Coeur, Université de Montréal, Montréal, Québec, Canada

ARTICLE INFO

Article history:

Received 13 August 2016

Received in revised form

24 October 2016

Accepted 6 November 2016

Available online xxx

Keywords:

Total knee arthroplasty

Heterotopic ossification

Ankylosis

Hinged prosthesis

ABSTRACT

Although heterotopic ossification (HO) after total hip arthroplasty has been very well described as a cause of disability, much less was written on clinical dysfunction of HO after total knee arthroplasty (TKA). To the extent of our knowledge, there has been no published case of complete bony ankylosis, secondary to severe generalized HO, after a TKA. We present the case of a 67-year-old female treated successfully, with surgical excision of ossification and TKA revision surgery, using a rotating hinge system.

© 2016 The Authors. Published by Elsevier Inc. on behalf of The American Association of Hip and Knee Surgeons. This is an open access article under the CC BY-NC-ND license (<http://creativecommons.org/licenses/by-nc-nd/4.0/>).

Introduction

Severe heterotopic ossification (HO) after total knee arthroplasty (TKA) is rare. Although the overall incidence ranges from 1%–42% in primary TKAs, most are nonsignificant clinically [1–4]. In the few reported cases, treatment modalities varied between either conservative treatment, in the form of physical therapy, nonsteroidal anti-inflammatory drugs (NSAIDs), and radiation therapy [5,6], or surgical resection, with or without revision of the prosthesis [7–9]. We report a case of severe knee ankylosis, secondary to extensive HO, affecting the anterior distal femur, the posterior capsule, and both collateral ligaments, at 4 weeks after TKA revision.

Case history

A 67-year-old female, with a body mass index of 34.2 kg/m² and a medical history of controlled diabetes and hypertension, underwent a left TKA in 2011 at a community hospital, for severe osteoarthritis after failed conservative treatment with NSAIDs and multiple steroid intra-articular injections. No additional drugs were

used. Preoperative range of motion was limited to 0°–100° due to pain. The medial parapatellar approach was used, there were no intraoperative complications, and implants were correctly positioned on initial radiographs. Three days later, an accidental fall resulted in a periprosthetic tibial plateau fracture and tibial component loosening, which was treated with a tibial component revision surgery. There was no significant soft tissue injury, and minor dissection was performed. However, postoperative evolution was unfavorable and saw the development of progressive knee stiffness. At the 3-week postoperative visit, maximum flexion reached was 70°, with radiographs already showing the presence of extensive HO. Closed manipulation under anesthesia, 4 weeks postoperatively, achieved a range of motion of 0°–100°. Nonetheless, range of motion progressively decreased to 10°–30° at 3 months postoperatively.

The patient was referred to our institution 5 months after initial surgery for severe loss of motion and persistent pain. Clinical examination showed a warm and moderately swollen knee. Flexion contracture of 10° and maximal flexion of 20° were noted. Routine radiographs including anteroposterior, lateral, and merchant views showed satisfactory component fixation, with extensive HO in the supracondylar, posterior, and mediolateral aspects of the knee, mildly affecting the patellar tendon (Fig. 1). A complementary investigation revealed elevated serum alkaline phosphatase levels and abnormal bone scintigraphy, confirming high metabolic activity in all affected areas. A complete workup, including normal sedimentation rate, C-reactive protein values, and negative knee aspiration, ruled out a possible infection.

No author associated with this paper has disclosed any potential or pertinent conflicts which may be perceived to have impending conflict with this work. For full disclosure statements refer to <http://dx.doi.org/10.1016/j.artd.2016.11.001>.

^{*} Corresponding author. Department of Orthopedic Surgery, Hôpital du Sacré-Coeur, Université de Montréal, Montreal, Quebec H4J 1C5, Canada. Tel.: +1-514-792-9890.

E-mail address: baroudi_maher@hotmail.com

<http://dx.doi.org/10.1016/j.artd.2016.11.001>

2352–3441/© 2016 The Authors. Published by Elsevier Inc. on behalf of The American Association of Hip and Knee Surgeons. This is an open access article under the CC BY-NC-ND license (<http://creativecommons.org/licenses/by-nc-nd/4.0/>).

Please cite this article in press as: M. Baroudi, et al., Severe heterotopic ossification and stiffness after revision knee surgery for a periprosthetic fracture, Arthroplasty Today (2016), <http://dx.doi.org/10.1016/j.artd.2016.11.001>

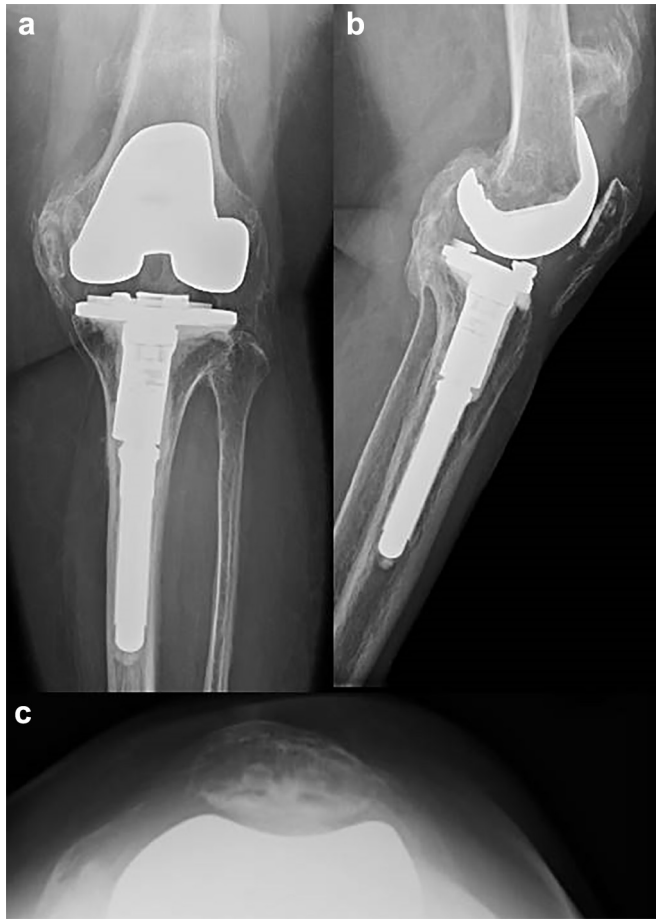

Figure 1. Preoperative radiographs (anteroposterior (AP) (a), lateral (b), and Merchant (c) views) showing extensive heterotopic ossification of the left total knee arthroplasty.

After an in-depth discussion with the patient, who was seeking a functional painless knee, it was decided to perform a total knee revision surgery after ossification maturation. Regular follow-up, with clinical examination, serial radiographs and bone scintigraphy, confirmed after 2 years the maturation and stabilization of the pathology, with a marked decrease in bone scan activity. Therefore, a total knee revision surgery, with excision of the ossification, was scheduled at 3 years after the index operation. Technical challenges were expected, with surgical exposure and safe excision of HO being the main concerns. Soft tissue balancing and bone stock also needed to be taken into consideration when choosing the implants. The knee was first exposed in full extension, before proceeding to the resection of the anterior distal femur ossification, while conserving the quadriceps which was completely functional. The polyethylene insert was removed with an osteotome, giving more space to evaluate the collaterals. Extensive ossification of the collaterals makes them nonfunctional, consequently they were completely excised. This allowed for some degree of knee flexion, to reach the posterior aspect of the knee. The osseous bridge between the femur and the tibia was broken. Because of ossification maturation, a well-defined surgical plane was identified between the ossification and the posterior aspect of the distal femur, which was released all the way up, until 90° of knee flexion were reached. At this stage, with an unobstructed view, posterior ossification was resected from the posterior capsule, using careful dissection. A rotating hinged knee implant was chosen to deal with collateral ligament insufficiency after resection, requiring existing implant removal. Femoral component removal

showed significant bone loss and poor bone quality of the distal femur (Fig. 2a). Intraoperative decision was to perform distal femoral resection and segmental replacement, with the proposed level of resection marked above the ossification, based on implant configuration (Fig. 2b). Attention then focused on the joint line, which was restored using a circumferential metallic tibial augment. A segmental distal femoral component and a rotating hinged knee modular tibial platform (Zimmer, Warsaw, IN) were implanted (Fig. 2c). At the end of the procedure, the knee could achieve 0°–110° range of motion. In the first postoperative day, the patient received a prophylactic single-dose regimen of radiation therapy, and a routine postoperative rehabilitation protocol was followed.

At 4 weeks postoperatively, a lateral patellar dislocation, secondary to medial capsular rupture after a traumatic episode, was diagnosed. Clinically, this manifested in an inability to perform a straight leg raise and a hypermobile patella. Therefore, the patient underwent a lateral release of the patella, with advancement and augmentation of the medial capsule, using a synthetic ligament. This resulted in a stable and well-centered patella with a 0°–90° range of motion.

At 1 year postoperatively, her active range of motion was from full extension to 100° of flexion, with no extension lag. Standard radiographs showed satisfactory position and alignment, with no ossification recurrence (Fig. 3).

Discussion

The incidence of symptomatic HO following TKA is relatively rare. Symptoms are present in less than 1% of patients and expressed by loss of motion, pain, or quadriceps snapping [1]. Numerous risk factors that have been listed for HO around the hip, such as previous history of HO, ankylosing spondylitis, Paget disease, hypertrophic osteoarthritis, and post-traumatic osteoarthritis characterized by extensive osteophytosis [3,4,10,11], are also predisposing factors in TKAs. Other factors involved in the formation of HO after TKA are related to the surgical technique, such as excessive periosteal injury after exposure of the distal femur for instrumentation positioning, notching of the anterior cortex, damage to the quadriceps muscle, and inadequate hemostasis and knee hematoma [2,3,12,13]. Forced knee manipulation is also recognized as potentially increasing the risk factor [3]. Several classification systems for HO after TKA have been proposed, and are all based on anteroposterior and lateral radiographic sizing [2–4]. None of them include clinical considerations or the need for surgical treatment. As with the hip, prevention is the most efficient treatment for HO of the knee. However, as it is rare, routine prophylaxis after TKA is not indicated, and only required when several risk factors are combined [13]. The efficacy of NSAIDs and local radiation therapy, in terms of prevention, has been studied and well documented for the hip [14,15], and can also be applied for the knee [9]. Most knees with HO achieve a satisfactory clinical outcome without additional surgery [3,5,7,12]. Spontaneous resolution of pain with flexion restrictions has also been reported [6].

Surgical treatment is rarely required. Therefore, the literature on interventions for symptomatic HO after TKA is limited to case reports. In most of the reported cases, surgical excision was used specifically to remove the symptomatic bony masses found in the quadriceps expansion that led to limited range of motion, pain, and snapping [7,8]. Thienpont et al [16] reported one case of successfully treated ossified collaterals, using complete collateral resection and reconstruction, with a hinged implant and radiotherapy.

In our case, the ossification was already visible on radiographs at less than 4 weeks after tibial component revision surgery, and affected the collaterals extensively, as well as the anterior distal femur and posterior capsule, leading to a stiff knee. Extensive bone

Download English Version:

<https://daneshyari.com/en/article/8796105>

Download Persian Version:

<https://daneshyari.com/article/8796105>

[Daneshyari.com](https://daneshyari.com)