

# Optimizing Arthroscopy for Osteochondral Lesions of the Talus: The Effect of Ankle Positions and Distraction During Anterior and Posterior Arthroscopy in a Cadaveric Model

Phinit Phisitkul, M.D., Craig C. Akoh, M.D., Chamnanni Rungprai, M.D., Alexej Barg, M.D., Annuziatio Amendola, M.D., Kevin Dibbern, Ph.D., and Donald Anderson, Ph.D.

**Purpose:** To quantify arthroscopic accessibility of the talar dome with predefined ankle positions through anterior and posterior approaches. **Methods:** Fourteen below-knee cadaver specimens underwent preoperative range of motion assessments. A 30° 2.7-mm arthroscopic camera was used to mark accessible areas at varying ankle positions. Accessible regions were quantified using a surface laser scanner and digital 3 × 3 grid. Statistical analyses were performed to detect differences in arthroscopic accessibility between different flexion angles and noninvasive distraction. **Results:** The mean arthroscopic accessibility of the talus was 58.5% and 49.8% for the anterior and posterior approaches, respectively ( $P < .001$ ). During anterior arthroscopy, accessibility increased with up to 30° of plantarflexion ( $P < .001$ ). There were no significant differences in accessibility between flexion groups for the posterior approach. There was significantly greater central zone accessibility for anterior arthroscopy (87.7%) when compared with posterior arthroscopy (74.3%;  $P = .002$ ). Arthroscopic accessibility increased with increasing ankle distraction for both the anterior and posterior approaches (parameter estimates ± standard error): anterior = 6.5% ± 1.3%/mm of distraction,  $P < .001$ ; and posterior = 7.0% ± 2.8%/mm,  $P = .026$ . Frequency analysis showed that the posterior third of the talus was completely inaccessible in 7 out of 14 of ankles during anterior arthroscopy. The anterior third of the talus during posterior arthroscopy was inaccessible in 11 out of 14 ankles during posterior arthroscopy. **Conclusions:** Ankle plantarflexion up to 30° may be adequate for anterior arthroscopy for osteochondral lesions of the talus (OLTs). Noninvasive distraction also increases accessibility during both anterior and posterior arthroscopy. Anterior arthroscopy should be used for central third OLTs due to greater accessibility. **Clinical Relevance:** Ankle positioning is an important consideration for anterior arthroscopy. Surgical approach used should match with the location of the OLTs.

Osteochondral lesions of the talus (OLTs) are a common source of chronic disability after ankle sprains in active patients, occurring in up to 70% of

rotational ankle injuries.<sup>1</sup> OLTs most commonly occur in male patients in the third decade of life.<sup>2</sup> Trauma is the most common etiology of OLTs, implicated in 98% and 70% of lateral and medial lesions, respectively.<sup>3</sup> Diagnosing OLTs is difficult and requires a high index of suspicion. Clinical features are nonspecific such as discomfort, swelling, catching, and instability.<sup>4,5</sup> Often missed on plain radiography, advanced imaging improves the sensitivity for detecting these lesions.<sup>4,6-10</sup> The lack of both blood supply and lymphatic drainage at the talus makes OLTs extremely difficult to heal and susceptible to avascular necrosis.<sup>11,12</sup> Inappropriate management of OLTs due to improper diagnosis can lead to osteoarthritis of the ankle joint and chronic pain.<sup>13,14</sup>

Arthroscopy is the gold standard for both visualization and treatment for recalcitrant OLTs.<sup>4</sup> OLTs have been cited as the most common preoperative diagnosis for ankle arthroscopy.<sup>15</sup> However, there is much debate as

From the Department of Orthopaedics and Rehabilitation, University of Iowa (P.P., C.C.A., K.D., D.A.), Iowa City, Iowa, U.S.A.; Phramongkutklao Hospital and College of Medicine (C.R.), Bangkok, Thailand; Department of Orthopaedics, University of Utah (A.B.), Salt Lake City, Utah; and Duke University (A.A.), Durham, North Carolina, U.S.A.

The authors report the following potential conflicts of interest or sources of funding: P.P. receives support from Mortise Medical, First Ray, Arthrex, and Smith and Nephew. Full ICMJE author disclosure forms are available for this article online, as supplementary material.

Received November 28, 2016; accepted June 19, 2017.

Address correspondence to Craig C. Akoh, M.D., Department of Orthopaedics and Rehabilitation, University of Iowa, 200 Hawkins Drive, Iowa City, IA 52242, U.S.A. E-mail: [craig-akoh@uiowa.edu](mailto:craig-akoh@uiowa.edu)

© 2017 by the Arthroscopy Association of North America  
0749-8063/161129/\$36.00

<http://dx.doi.org/10.1016/j.arthro.2017.06.027>

to the optimal surgical approach algorithm for OLTs. Previous data have shown that posterior OLTs are inaccessible from an anterior arthroscopic approach and are potentially more accessible via the posterior approach.<sup>5,16,17</sup> However, there is a paucity of data comparing accessibility of OLTs from the posterior versus anterior arthroscopic approaches. Additionally, there have been concerns about increased length of surgery and postoperative complications for the posterior arthroscopic approach.<sup>18-20</sup>

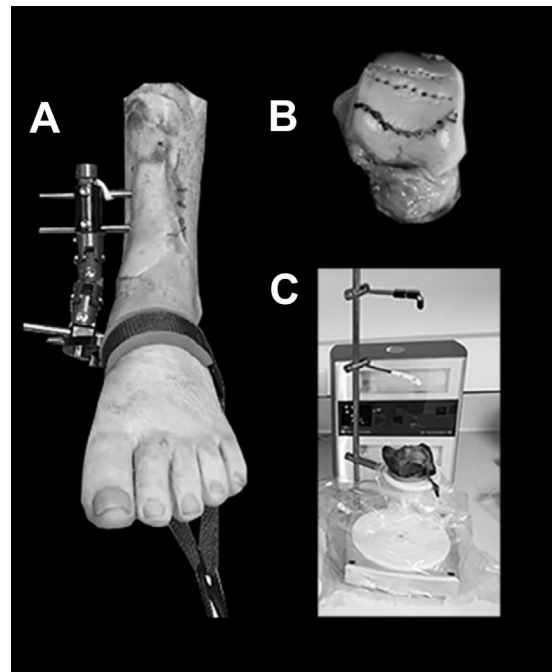
Furthermore, little is known about the effects of limitations in ankle range of motion upon arthroscopic accessibility. Increasing age and the male gender have been associated with decreased ankle range of motion.<sup>21,22</sup> Limited ankle range of motion can lead to increased arthroscopic soft-tissue impingement, reducing optimal arthroscopic visualization and increasing the risk of neurovascular injury.<sup>23,24</sup> Various distraction methods have been described to safely improve intra-articular visualization of the ankle joint while reducing iatrogenic damage to cartilage.<sup>25,26</sup> However, previous studies failed to determine the effects of ankle position and amount of noninvasive ankle distraction on arthroscopic accessibility of OLTs.

This study's purpose was to quantify arthroscopic accessibility of the talar dome with predefined ankle plantarflexion and dorsiflexion through the anterior and posterior approaches. We hypothesized that increasing both the ankle plantarflexion and the amount of ankle distraction will significantly increase the area of arthroscopic accessibility on the talar dome.

## Methods

Fourteen below-knee human cadaveric specimens from 14 individuals were obtained from the Science Tissue Bank (Hanover, MD). Inclusion criteria included cadavers  $\leq 65$  years old without clinical or radiographic evidence of pathologic conditions at the time of procurement. Exclusion criteria included cadavers with pathologic conditions, degenerative changes, or prior surgeries. Maximum plantarflexion and dorsiflexion were measured from the lateral ankle using a modification of a previously described method.<sup>27</sup> We measured the angle between (1) one line from the posterior aspect of the fibula to the lateral malleolus and (2) a second line that was drawn from the base of the fifth metatarsal. All measurements were taken using a calibrated electronic goniometer with a precision of  $0.1^\circ$  (iGaging 11" Electronic Protractor Digital Goniometer; San Clemente, CA).

To create a stiff ankle model, we used a pediatric Biomet EBI monolateral external fixator (Parsippany, NJ; Fig 1A) to set the ankle position at varying angles of plantarflexion (neutral,  $30^\circ$ , and maximum) and maximum dorsiflexion. The electronic goniometer was used to accurately set the previously mentioned ankle



**Fig 1.** Experimental design. (A) Experimental setup with the monolateral external fixation and noninvasive ankle distraction applied. (B) After intra-articular arthroscopic delineation of arthroscopic accessibility using a curette to mark the articular cartilage, drilling was performed to enhance the visibility of the arthroscopically assessable area. The anterior line represents neutral dorsiflexion, the middle line represents  $30^\circ$  of plantarflexion, and the most posterior line represents maximum plantarflexion during anterior arthroscopy. (C) Surface three-dimensional laser scan is used to quantify arthroscopically accessible areas of the talus.

positions. The EBI monolateral external fixator contained an internal telescoping rod that allowed for noninvasive distraction to be placed as described elsewhere.<sup>28</sup> The noninvasive distraction was placed with the ankle in the neutral position using a disposable ankle strap (Smith and Nephew, Andover, MA). The amount of distraction was set at 135 Newtons (30 pounds) using a calibrated spring scale. This was previously determined to be the maximum amount of noninvasive distraction that can be safely administered.<sup>25</sup> The amount of intra-articular working space during noninvasive distraction was defined as the vertical distance from the roof of the distal tibia plafond and the apex of the talar body. Measurements were obtained with calibrated sizing rods in millimeters (Genius Tools 6 PC Metric Pin Punch Set PC 566MP; Ontario, CA).

The order of arthroscopic approach (anterior vs posterior) was randomized using a computerized random number generator (<http://stattrek.com/statistics/random-number-generator.aspx>). For anterior arthroscopy, anteromedial and anterolateral portals were established in the standard fashion.<sup>29</sup> The 2.7-mm,  $30^\circ$  arthroscopic camera

Download English Version:

<https://daneshyari.com/en/article/8796852>

Download Persian Version:

<https://daneshyari.com/article/8796852>

[Daneshyari.com](https://daneshyari.com)