



ELSEVIER

Contents lists available at ScienceDirect

## The Journal of Arthroplasty

journal homepage: [www.arthroplastyjournal.org](http://www.arthroplastyjournal.org)

## The Posterior Capsular Ligamentous Complex Contributes to Hip Joint Stability in Distraction

Masaki Takao, MD, PhD <sup>a,\*</sup>, Yoshito Otake, PhD <sup>b</sup>, Norio Fukuda, MEng <sup>b</sup>,  
Yoshinobu Sato, PhD <sup>b</sup>, Mehran Armand, PhD <sup>c</sup>, Nobuhiko Sugano, MD, PhD <sup>a</sup>

<sup>a</sup> Department of Orthopaedic Medical Engineering, Osaka University Graduate School of Medicine, Suita, Osaka, Japan

<sup>b</sup> Graduate School of Information Science, Nara Institute of Science and Technology, Ikoma, Nara, Japan

<sup>c</sup> Johns Hopkins University Applied Physics Laboratory, Laurel, Maryland

### ARTICLE INFO

#### Article history:

Received 7 July 2017

Received in revised form

13 September 2017

Accepted 12 October 2017

Available online xxx

#### Keywords:

total hip arthroplasty

hip joint stability

traction

hip capsular ligament

short external rotators

### ABSTRACT

**Background:** Laxity of soft tissues after total hip arthroplasty is considered to be a cause of accelerated wear of bearing surfaces and dislocation. The purpose of this study is to assess the contribution of the anterior and posterior capsular ligamentous complexes and the short external rotators, except the quadratus femoris, on the stability of the hip against axial traction.

**Methods:** The study subjects comprised 7 fresh cadavers with 12 normal hip joints. In 6 hips, soft tissues surrounding the hip joint were resected in the following order to simulate the anterior approach: anterior capsule, posterior capsule, piriformis, conjoined tendon, and external obturator. In the remaining 6 hips, soft tissues were resected in the following order to simulate the posterior approach: piriformis, conjoined tendon, external obturator, posterior capsule, and anterior capsule. Soft tissue tension was measured by applying traction amounting to 250 N with joints in the neutral position.

**Results:** The separation distance between the femoral head and acetabulum during axial leg traction significantly increased from 4.0 to 14.5 mm on average after circumferential resection of the capsule via the anterior approach. Subsequent resection of the short external rotators increased the separation distance up to 19.0 mm, but the differences did not reach statistical significance. Resection of the short external rotators via the posterior approach did not significantly increase the separation distance; it significantly increased from 6.0 to 11.4 mm after the resection of the anterior capsule and further to 20.5 mm after the resection of the posterior capsule.

**Conclusion:** The posterior capsule, in addition to the anterior capsule, significantly contributes to hip joint stability in distraction regardless of whether the short external rotators, except the quadratus femoris, were preserved or resected.

© 2017 Elsevier Inc. All rights reserved.

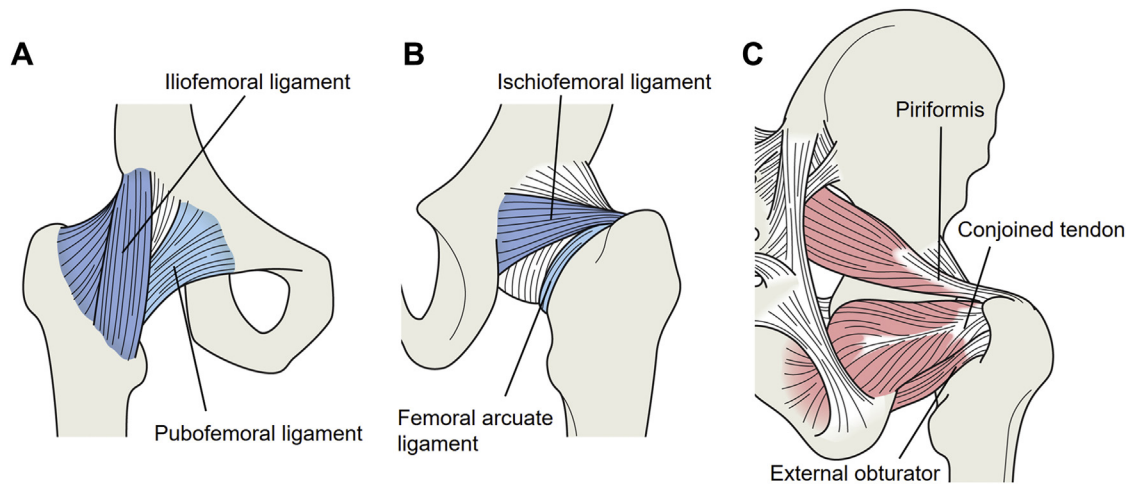
Laxity of soft tissues after total hip arthroplasty (THA) is considered a cause of accelerated wear of bearing surfaces [1] and dislocation [2,3]. After THA, separation of the artificial femoral head

**Source of Funding:** This research was supported by MEXT/JSPS KAKENHI26108004, JSTPRESTO20407, and AMED/ETH the strategic Japanese-Swiss cooperative research program and R21EB020113-01 from the National Institutes of Health.

One or more of the authors of this paper have disclosed potential or pertinent conflicts of interest, which may include receipt of payment, either direct or indirect, institutional support, or association with an entity in the biomedical field which may be perceived to have potential conflict of interest with this work. For full disclosure statements refer to <https://doi.org/10.1016/j.arth.2017.10.026>.

\* Reprint requests: Masaki Takao, MD, PhD, Department of Orthopaedic Medical Engineering, Osaka University Graduate School of Medicine, 2-2 Yamadaoka, Suita, Osaka 565-0871, Japan.

from the acetabular insert has been reported during the swing phase of normal walking in the direction of the cup axis [4]. This phenomenon is considered to result in stripe wearing of the head with ceramic-on-ceramic bearings and have a significant impact on the wear and biomechanics of the implant [1,5]. The hip capsule is reported to be a significant stabilizer against axial traction in addition to the acetabular labrum according to the results of biomechanical experiments using cadaveric hip joints [6–9]. The hip capsule is a capsular ligamentous complex that consists of a superficial layer of longitudinal ligaments and a deep layer of circularly oriented fibers lined with synovium [10]. The most important and anatomically consistent capsular ligamentous complexes are the iliofemoral and ischiofemoral ligaments [11,12], which form the anterior and posterior capsular ligamentous complexes respectively (Fig. 1). However, which capsular ligamentous



**Fig. 1.** The anterior capsular ligamentous complex consists mainly of the iliofemoral and pubofemoral ligaments (A). The posterior capsular ligamentous complex consists mainly of the ischiofemoral and femoral arcuate ligaments (B). In the anterior approach group, soft tissues surrounding the hip joint were resected in the following order: anterior capsule (A), posterior capsule (B), piriformis, conjoined tendon, and external obturator (C). In the posterior approach group, the soft tissues were resected in the following order: piriformis, conjoined tendon, external obturator (C), posterior capsule (B), and anterior capsule (A).

complex contributes to the stability of the hip joint against distraction remains unclear. The short external rotators consisting of the piriformis, internal and external obturators, superior and inferior gemelli, and quadratus femoris are also considered as hip joint stabilizers. Selective resection of the short external rotators, except the quadratus femoris, is performed via various surgical approaches, while their effect on stability against traction remains unknown. The purpose of this study is to assess the contribution of capsular ligamentous complexes and the short external rotators, except the quadratus femoris, to joint stability against distraction with surrounding major muscles.

## Materials and Methods

### Subjects

A total of 12 normal hips (7 right hips and 5 left hips) from 7 fresh cadavers (4 men and 3 women) were used in this study. Cadaver specimens had a mean age of 69 years (range 47–85) at the time of death. Details of the antemortem weight and mobility status were not available. We acquired computed tomography images of all specimens prior to the experiment with a slice thickness of 0.61 mm (in-plane pixel size ranging between 0.74 and 0.93 mm) to exclude specimens with hip joint disorders, including osteoarthritis, and to develop pelvic and femoral bone computational models for computer navigation. The lateral center-edge angle was measured by aligning the pelvis based on an anterior pelvic plane consisting of the bilateral anterior superior iliac spines and pubic tubercles. Neck anteversion and neck-shaft angle were measured by aligning the femur with the posterior condylar plane consisting of the most posterior point of trochanteric region and bilateral posterior condyles. The maximal alpha angle on the radial reconstructed planes along the femoral neck axis was also measured. The lateral center-edge angle was  $35^\circ \pm 6^\circ$  ( $25^\circ$ – $45^\circ$ ). The neck-shaft and neck anteversion angles were  $124^\circ \pm 2^\circ$  ( $119^\circ$ – $129^\circ$ ) and  $11^\circ \pm 7^\circ$  ( $-1^\circ$  to  $25^\circ$ ), respectively. The maximal alpha angle was  $51^\circ \pm 9^\circ$  ( $35^\circ$ – $68^\circ$ ). We obtained approval for this study from the Institutional Review Board committees of each of the collaborative institutes.

### Measurement of Soft Tissue Tension

Cadaveric bodies were positioned in the lateral position and the pelvic ring was fixed to the operation table using external fixation devices for pelvic fractures (Fig. 2). Skin and subcutaneous fat tissues surrounding the hip joint were removed. The anterior aspect of the capsule was exposed through the boundary between the gluteus medius and the tensor fascia lata. The posterior aspect of the capsule was exposed through the boundaries among the gluteus minimus, piriformis, and conjoined tendon.

The optical reference markers for the pelvis were fixed to the iliac crest with 2 apex pins of 4-mm diameter (Fig. 2). The optical reference markers for the femur were fixed to the femoral shaft with 2 apex pins of 4-mm diameter (Fig. 2). An L-shaped metal plate fitted with a hook was fastened with inelastic bandages from the lower thigh to the sole of the foot, and traction was applied to a traction gauge (FB 500N; IMADA Co, Ltd, Aichi, Japan) attached to the hook. Traction amounting to 250 N was applied with the joint in the neutral position. The traction force was determined based on the average intraoperative leg traction force of 21 orthopedic surgeons, which was 24 kg [13].

In 6 hips, soft tissues surrounding the hip joint were resected in the following order to simulate the anterior approach: (1) anterior capsule, (2) posterior capsule, (3) piriformis, (4) conjoined tendon consisting of the internal obturator and gemelli, and (5) external obturator (Fig. 1). In the remaining 6 hips, the soft tissues were resected in the following order to simulate the posterior approach: (1) piriformis, (2) conjoined tendon, (3) external obturator, (4) posterior capsule, and (5) anterior capsule (Fig. 1). In 5 cadavers, 5 left hips were allocated to the anterior approach group and 5 right hips were allocated to the posterior approach group. In the remaining 2 cadavers, right hips were allocated to the anterior and posterior approach groups, respectively, as the left hips in these cadavers demonstrated osteoarthritic changes.

The separation distance between the femoral head and the acetabulum was measured after each soft tissue resection using our in-house navigation system [14]. The system was developed as a plug-in module of an open source platform for medical image processing (3D Slicer). The navigation system was connected to an optical tracker (Polaris; Northern Digital Inc, Canada) with Open

Download English Version:

<https://daneshyari.com/en/article/8799574>

Download Persian Version:

<https://daneshyari.com/article/8799574>

[Daneshyari.com](https://daneshyari.com)