



Contents lists available at ScienceDirect

## International Journal of Pediatric Otorhinolaryngology

journal homepage: [www.elsevier.com/locate/ijporl](http://www.elsevier.com/locate/ijporl)

## Protocol incorporating airway CT decreases negative bronchoscopy rates for suspected foreign bodies in pediatric patients



Omar G. Ahmed<sup>a,b,\*</sup>, Robert P. Guillerman<sup>c,d</sup>, Carla M. Giannoni<sup>a,b</sup>

<sup>a</sup> Texas Children's Hospital, Otolaryngology, Houston, TEXAS, USA

<sup>b</sup> Baylor College of Medicine, Otolaryngology, Houston, TEXAS, USA

<sup>c</sup> Texas Children's Hospital, Department of Pediatric Radiology, Houston, TX, USA

<sup>d</sup> Baylor College of Medicine, Department of Radiology, Houston, TX, USA

### A B S T R A C T

**Background:** Foreign body aspiration (FBA) is the 4th leading cause of death in children between the ages 1-5. Although direct laryngoscopy and bronchoscopy (DL&B) is the reference standard for diagnosis of pediatric airway foreign bodies, there is a high negative bronchoscopy rate, exposing patients to unnecessary operative and anesthetic risks and costs.

**Methods:** A clinical care protocol entailing the selective use of low-dose non-contrast airway computed tomography (CT) for children with an intermediate risk for FBA on the basis of clinical exam and chest radiography was implemented to decrease the negative DL&B rate. A retrospective review was conducted to compare negative bronchoscopy rates before and after implementation of the new protocol and the diagnostic performance characteristics of airway CT for airway foreign bodies were analyzed.

**Results:** After implementation of the airway FB clinical care protocol entailing selective airway CT, the overall negative bronchoscopy rate decreased from an institutional historical rate of 37% (54/145) to 17% (10/56) ( $p = .06$ ). The overall sensitivity, specificity, and positive and negative predictive value of airway CT for FB was 91%, 100%, 100%, and 97% respectively.

**Conclusions:** Low-dose non-contrast airway CT is highly sensitive and specific for airway foreign bodies, and its selective use in a clinical care protocol for children with suspected foreign body aspiration could greatly reduce the negative bronchoscopy rate, thereby decreasing operative risks and costs.

### 1. Introduction

Foreign body aspiration (FBA) is the fourth leading cause of death for children between the ages 1-5 according to the Centers for Disease Control [1]. Failure to identify an airway foreign body carries the risk of pneumonia, hypoxemia, pneumothorax and/or acute respiratory failure. Johnson et al. found an overall mortality risk of 2.5% in over 11,000 pediatric patients who were admitted for FBA [2]. The diagnosis of airway FBA can be very challenging in the pediatric population. The typical initial methods for detecting FBA are clinical history, physical exam and chest radiography (CXR). However, the reported sensitivity and specificity of the clinical history, physical examination physical exam and/or CXR for the diagnosis of FBA in children is widely variable, ranging from 10 to 90%, according to a recent review of the literature by Hitter et al. [1].

The current reference standard for diagnosing FBA when the clinical

presentation and findings on CXR are suspicious for FBA is direct laryngoscopy and bronchoscopy (DL&B). However, many children referred for suspected FBA have negative DL&B procedures. This exposes children to the perioperative risks of the procedure (2-22%) including bronchospasm, hypoxemia, bronchial laceration, airway edema, pneumothorax, and the anesthesia-associated risks including aspiration of gastric contents if not preceded by fasting [3], as well as potential cognitive deficits from anesthetic neurotoxicity in infants and young children [4]. The negative bronchoscopy rate for suspected FBA is 20–50% nationally [5,6]. At our institution the negative bronchoscopy rate for the years 2008–2012 was 37% (i.e., only 63% of patients that underwent Pediatric Otolaryngology consultation and DL&B were identified as having a true FBA) [7].

Historically, patients deemed high suspicion for FBA are first evaluated by the Otolaryngology service and then in most cases taken to the operating room for DL&B. Patients considered low suspicion are

Abbreviations: DL&B, Direct Laryngoscopy and Bronchoscopy; FBA, foreign body aspiration

\* Corresponding author. 3 Hermann Museum Circle Dr, Unit 6201, Houston, Tx 77004, USA.

E-mail address: [oa1@bcm.edu](mailto:oa1@bcm.edu) (O.G. Ahmed).

<https://doi.org/10.1016/j.ijporl.2018.03.016>

Received 28 January 2018; Received in revised form 16 March 2018; Accepted 16 March 2018

Available online 19 March 2018

0165-5876/ © 2018 Elsevier B.V. All rights reserved.

typically evaluated and the disposition determined by the Emergency Center (EC) physician. Patients of intermediate suspicion pose a clinical dilemma on whether to proceed to the operating room or observe since many of these patients are not found to have FBA on DL&B (negative bronchoscopy).

Over the past 10 years there have been a few reports of using computed tomography (CT) in the evaluation of FBA. The sensitivity of CT for the detection of FBA has been reported as high as 100% with a specificity of between 66.7 and 100% [6]. A CT scan of the pediatric airway can be obtained with a radiation effective dose of 3 milliSieverts (mSv) or less, depending on the imaging technique and the patient age, sex and size. For comparison, a typical pediatric chest radiograph involves a radiation effective dose of 0.02 mSv, and the average annual natural background radiation effective dose worldwide is 2.4 mSv [8]. Further reduction of the radiation dose from a CT scan for suspected FBA is achievable by limiting the scan coverage to the airways rather than the entire chest, and by implementing new techniques such as wide-detector-array volumetric scanning and iterative reconstruction.

In an effort to decrease the high negative bronchoscopy rate for FBA at our institution, the Pediatric Otolaryngology service in collaboration with the Pediatric Emergency Medicine and Pediatric Radiology services developed and implemented a clinical care protocol incorporating CT for selected patients presenting to the EC [9]. In this protocol, patients were classified either as high, intermediate, or low likelihood of FBA based on clinical history, physical exam, and CXR. A CT of the airways was performed with low radiation dose technique without the use of intravenous contrast or sedation in patients with an intermediate likelihood of FBA. If the CT was interpreted as showing an airway foreign body, the patient underwent referral to Otolaryngology for DL&B. If the CT did not reveal an airway foreign body, the patient's disposition was determined by the EC physician.

The purpose of this study was to assess the impact of a new clinical care protocol for suspected FBA on the negative bronchoscopy rate at a large quaternary children's hospital and to determine the diagnostic performance characteristics of low-dose, non-contrast airway CT for FBA.

## 2. Methods

The new clinical care protocol for suspected FBA was introduced January 1, 2015 at Texas Children's Hospital in Houston, Texas. Patients were classified either as low, intermediate, or high likelihood of FBA based on clinical history, physical exam, and CXR findings

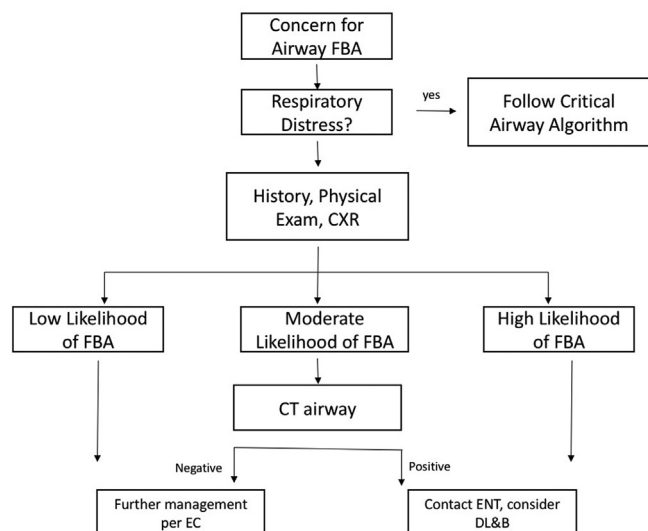


Fig. 1. (Giannoni 2015) Algorithm for evaluating child with possible airway foreign body.

(Fig. 1). Findings highly suggestive of FBA included a clinical history of a witnessed choking event, physical exam finding of unilateral wheezing, or CXR findings of unilateral air trapping or radiopaque foreign body. Patients with two or more highly suggestive findings were considered to have a high likelihood of FBA and the Otolaryngology service was consulted for consideration of DL&B. Patients with no highly suggestive findings were considered to have a low likelihood of FBA and disposition was determined by the EC physician. Patients with only one highly suggestive finding were considered to have an intermediate likelihood of FBA and an airway CT was recommended. The airway CT technique consisted of a single volumetric acquisition on a Toshiba Aquilion One 320-detector scanner during free-breathing without sedation or intravenous contrast administration with low-dose radiation exposure technique (80 kVp, 40 mA, 0.35 s gantry rotation time, mean CTDI<sub>vol</sub> 1.1 mGy, mean effective dose 0.8 mSv) and z-axis coverage from the larynx to the segmental bronchi. If the CT scan did not reveal an airway foreign body, the patient was re-evaluated and disposition determined by the EC physician. If the CT scan was interpreted as showing an airway foreign body, the Otolaryngology service was consulted for consideration of DL&B.

A search of the EPIC electronic medical record was performed to identify all patients who underwent an airway CT and/or DL&B for possible airway foreign body from January 1, 2015 to August 1, 2016 at our quaternary children's hospital. Specific information recorded included age, sex, days of symptoms, clinical history, physical exam findings, physical exam findings, and CT and DL&B findings. As per the clinical care protocol, patients were classified as low, intermediate, or high likelihood of having an airway foreign body based on the clinical history, physical exam findings, and CXR findings recorded in EPIC. The negative bronchoscopy rate was calculated for this time period and compared to the negative bronchoscopy rate from this institution for the period 2008-20012 published by Friedman et al. prior to the implementation of the new clinical care protocol [7].

The diagnostic performance characteristics of airway CT for foreign body were determined using DL&B and clinical follow-up as the reference standard. True positive CT scans were those interpreted as showing an airway foreign body that was confirmed by DL&B. False positive CT scans were those interpreted as showing an airway foreign body that was unconfirmed by DL&B. True negative CT scans were those interpreted as not showing an airway foreign body and corroborated by clinical follow-up or by DL&B performed in deviation from the clinical care protocol. False negative CT scans were those interpreted as not showing an airway foreign body but refuted by an airway foreign body diagnosed on clinical follow-up or DL&B performed in deviation from the clinical care protocol. Clinical follow-up consisted of a phone call made to the patient's parent or legal guardian asking if the patient was later diagnosed with an airway foreign body within thirty days of the initial presentation, or a review of the EPIC chart for patients whose caretaker was unable to be contacted.

Chi-square analysis was used to compare negative bronchoscopy rates before and after implementation of the new clinical care protocol. Sensitivity, specificity, and positive and negative predictive values for CT were calculated from 2 × 2 contingency tables populated by the number of true positive, true negative, false positive, and false negative scans. Baseline characteristics were also compared between intermediate and high likelihood groups for airway foreign body using t-testing and chi-square analysis.

## 3. Results

A total of 87 patients were evaluated for possible airway foreign body with airway CT and/or DL&B from January 1, 2015 to August 1, 2016 in our study. This includes all patients considered as having a high or intermediate likelihood of an airway foreign body. Most patients with a low likelihood of an airway foreign body were not identified by our search criteria and thus excluded from further analysis. However,

Download English Version:

<https://daneshyari.com/en/article/8806258>

Download Persian Version:

<https://daneshyari.com/article/8806258>

[Daneshyari.com](https://daneshyari.com)