International Journal of Pediatric Otorhinolaryngology 109 (2018) 168–173

Contents lists available at ScienceDirect

International Journal of Pediatric Otorhinolaryngology

journal homepage: www.elsevier.com/locate/ijporl

Sialoblastoma in chin and management of treatment

Qian Wang, Sainan Ma, Huanhuan Chen, Mingli Yang, Weisong Cai*

Shengjing Hospital of China Medical University, Department of Oncology, 39 Huaxiang Street, Shenyang, Liaoning, China

ARTICLE INFO

Keywords:
Pediatric sialoblastoma
Therapy
Chemothepary
Prognosis

ABSTRACT

Objective: Sialoblastoma is a rare salivary gland tumor mainly located in parotid. In this article, we aimed to review the clinical manifestations and treatments of sialoblastoma, especially to provide effective chemotherapy regimens to instruct internal medicine therapy for unresectable or recurrent tumors.
Method: We reported a 1-year old girl who presented a left-sided firm facial mass and subsequently diagnosed as sialoblastoma. Afterwards, we reviewed and analyzed relevant literatures.
Results: Sixty-four cases of pediatric sialoblastoma were reviewed. Of them, surgical excision was the basic treatment, 17 cases received chemotherapy, and 15 cases got good response. Lung metastasis was reported in six patients, all of whom had good response to chemotherapy.
Conclusion: Chemotherapy may play an important role in residual, extensive, metastatic and relapsed cases. In addition, lung metastasis was unlikely to exert a significant effect on prognosis.

1. Introduction

Sialoblastoma is a rare malignant tumor originated from salivary gland epithelial cells, and always occurs during the congenital, neonatal or childhood period [1]. It was first reported as embryoma by Vawterand Tefftin 1966 [2]. Afterwards, Taylor suggested the sialoblastoma term [3], and the other appellations included congenital basal celladenoma, basal cell adenoma, basaloid adenocarcinoma, orembryoma. In 1996, sialoblastoma was classified as a type of benign tumor, however, the World Health Organization(WHO) classification regrouped it as a malignant epithelial salivary gland tumor in 2005 [1]. To our best knowledge, extremely limited literature has reported this disease, and the treatment regimen of this rare tumor remains controversial. In the article, we reported a patient who cannot get gross resection of primary tumor, who, instead, recieved the first-line chemotherapy of CEV (vincristine1.5 mg/m^2, epirubicin 60 mg/m^2, cyclophosphamide1000 mg/m^2) and obtained a good response. In addition, related reports in the literature were also reviewed.

2. Methods

We reported a 1-year old girl presenting a left-sided firm facial mass, who was subsequently diagnosed as sialoblastoma. The size, extent and invasive characteristics of the tumor made it incompletely excised, and her parents refused surgery. Hence, the regimen of CEV (vincristine1.5 mg/m^2, epirubicin 60 mg/m^2, cyclophosphamide1000 mg/m^2) was administered, which gave rise to good response. Relevant literatures were searched using the online search databases PubMed, Medical subject headings (MeSH), and the key words included sialoblastoma, congenital basal cell adenoma, salivary embryoma, congenital hybrid basal cell adenoma-adenoid cystic carcinoma and congenital hybrid basal cell adenoma.

3. Results

3.1. Case report

A 1-year old girl was accidently found to harbor a left-sided firm facial mass after an injury. With a gradual increase in size, she visited Pediatric Hospital of Beijing. And the biopsy was performed, the pathological diagnosis of biopsy indicated neuroendocrine tumor of the salivary gland initially. Then she visited the Hospital of Beijing Medical University for further consultation. After reviewing the slides from the original biopsy, the diagnosis was finally revised to sialoblastoma. The microscopic findings contained solid nests of basaloid cells, whit high nuclear: cytoplasmic ratio, round to oval nuclei, small nucleoli,fine nuclear chromatin. The number of mitotic figures was 20 per 10 high-power fields (HPFs). Immunohistochemical (IHC) staining showed the tumor cells to be positive for EMA, INi1and NSE (some cells) protein, the Ki67 proliferative index was 50%. Afterwards, she was admitted to our institution for further therapy.

On admission, the clinical examination revealed a firm, nodular, non-tender 7 × 5 × 3cm mass. Non-enhanced computed tomography (CT) showed diffuse uneven-dense soft tissue masses located around

* Corresponding author.
E-mail address: caiws@sj-hospital.org (W. Cai).

https://doi.org/10.1016/j.ijporl.2018.03.023
Received 25 December 2017; Received in revised form 19 March 2018; Accepted 21 March 2018
Available online 11 April 2018
0165-5876/ © 2018 Elsevier B.V. All rights reserved.

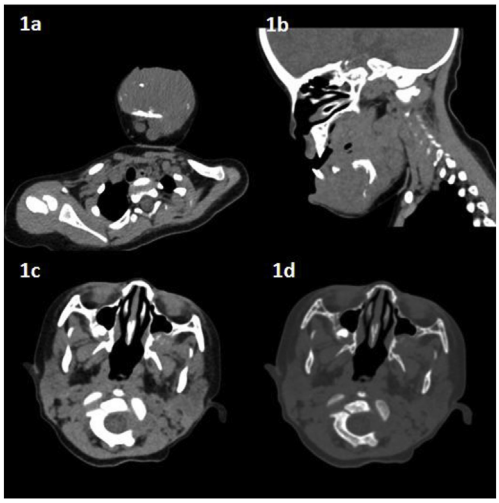

Fig. 1. CT images at initial diagnosis. **1a and 1b** Uneven-dense soft tissue masses located around maxillary and mandibular bones.**1c** The mass in left maxillary sinus.**1d** Destruction of superior wall of orbit bones.

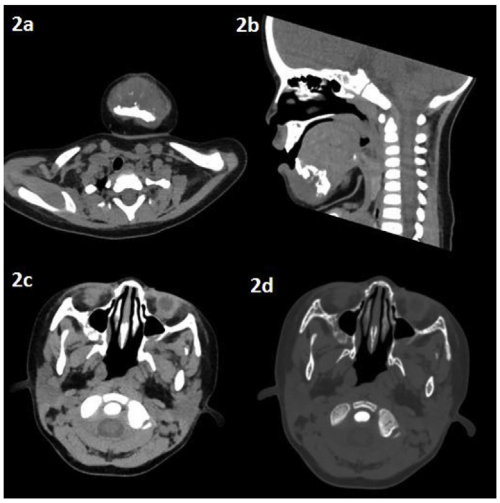

Fig. 2. CT images after two chemotherapy cycles. **2a and 2b** The tumor around maxillary shrunk in the size. **2c** Mass in left maxillary sinus shrunk. **2d** Mass in right superior wall of orbit stabilized.

maxillary and mandibular bones of 7cm in diameter and in left maxillary sinus of 1.7cm in diameter, enlarged bilateral submandibular lymph nodes and multiple bony destruction of the left maxillary, mandibular and right supraorbital bones, without evidence of intracranial extension (Fig. 1). Then, the patient underwent a comprehensive examination to determine the stage and to exclude the distance

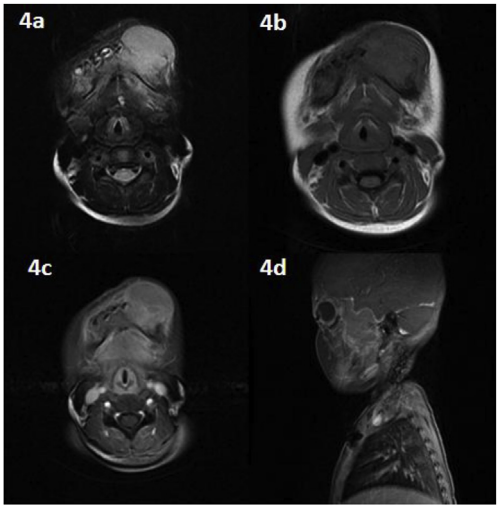

Fig. 4. MRI images demonstrating the submandibular mass of the patients. **4a** T2-weighted (T2-W) image revealed hyperintensity of the lesion.T1-W **4b** axial and **4d** sagittal images showed a huge facial mass mostly hypointense to the brain. **4c** Contrast-enhanced T1-W image demonstrated heterogeneous contrast enhancement.

metastasis, which concluded that there was no evidence of distant disease in chest CT scan, bone scintigraphy, and abdomen ultrasound. Additionally, she was born spontaneously by vaginal route after an uneventful pregnancy.

Surgery is the preferred option for sialoblastoma, but the size, extent and invasive characteristics of the tumor made it impossible to achieve complete excision, and her parents refused surgery, there was no guideline for other treatments. Since radiotherapy might cause culturally unacceptable side effects for her mid-face growth, chemotherapy was proposed as the valid management and the girl was administered with regimen CEV comprising of vincristine1.5 mg/m^2, epirubicin at 60 mg/m^2, cyclophosphamide 1000 mg/m^2, which was repeated every three weeks according to the Children's Oncology Group (COG)protocol of the sarcoma. After two cycles of therapy, there was a marked reduction in the tumor size both clinically and radiologically. A repeat CT scan demonstrated the volume of the tumor around maxillary reduced to 3.8 × 2.1 × 1.8 cm, the damage of mandibular bonesand the bilateral submandibular lymph nodes got shrunk as well, and the destruction of maxillary, mandibular bones got stable. Mass in left maxillary sinus shrunk too, and mass in right superior wall of orbit stabilized (Fig. 2). Then she received three more cycles, the mass shrunk to approximately 1.0 cm × 0.7 cm, destruction of mandibular bones get less in size, the mass in left maxillary sinus vanished (Fig. 3), so another three cycles were carried out, followed by clinical follow-up. One month later, the tumor relapsed, the disease-free survival (DFS) was 7 months. Because there is no standard second line chemotherapy regimen, the EP regimen consisting of cisplatin (60–80 mg/m^2) and

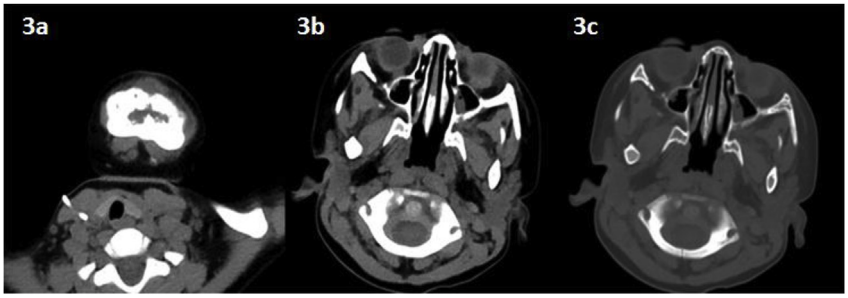

Fig. 3. CT images after five chemotherapy cycles. **3a** The mass in chin shrunk to approximately 1.0 cm × 0.7 cm **3b** The mass in left maxillary sinus vanished. **3c** Destruction of mandibular bones get less in size.

Download English Version:

https://daneshyari.com/en/article/8806262

Download Persian Version:

https://daneshyari.com/article/8806262

Daneshyari.com