Journal of Pediatric Surgery Case Reports 38 (2018) 4–8

Contents lists available at ScienceDirect

Journal of Pediatric Surgery Case Reports

journal homepage: www.elsevier.com/locate/epsc

Complete traumatic aortic transection

Pilar Anton-Martin[a,*], Brigham C. Willis[b,c], John J. Nigro[d], Katie Budolfson[b], Dannah Raz[a], Ramin Jamshidi[b,e]

[a] Department of Medical Education, Phoenix Children's Hospital, Phoenix, AZ, USA
[b] Department of Child Health, University of Arizona College of Medicine – Phoenix, Phoenix, AZ, USA
[c] Division of Cardiovascular Intensive Care, Phoenix Children's Hospital, Phoenix, AZ, USA
[d] Division of Cardiovascular Surgery, Phoenix Children's Hospital, Phoenix, Arizona, USA
[e] Division of Surgery, Phoenix Children's Hospital, Phoenix, AZ, USA

ARTICLE INFO

Keywords:
Complete aortic transection
Pediatric trauma
Blunt trauma
Mediastinal vascular injury
Aortic graft
Endovascular repair
Interposed graft
Blunt trauma

ABSTRACT

Complete aortic transection is typically fatal and extremely rare in pediatric patients. High clinical suspicion, even in hemodynamically stable patients, is essential for timely recognition and intervention. There is scant literature on the management of complete aortic transection in pediatric patients. Retrospective chart review of an adolescent who survived a large complete thoracic aortic rupture along with systematic pediatric literature review. A 16-year old female presented with a complete thoracic aortic transection with a 5–6 cm gap after an auto-pedestrian collision. Mediastinal vascular injury was suspected based on presentation, confirmed by chest radiograph, and further delineated by computed tomography. CT angiography was critical in determining the anatomy of injury and planning repair. Repair was achieved by left heart bypass and Dacron interposition grafting. The patient survived without vascular-related complications and remains well at 3-year follow up. Literature review revealed scant data on the diagnosis and management of complete aortic transection in children. The role of selective imaging for diagnosis is warranted. The applicability of endovascular stent-grafting in pediatric patients remains uncertain.

1. Introduction

Complete aortic transection is a rare and typically lethal complication of pediatric blunt trauma [1,2]. A high index of suspicion and a systematic approach to prompt diagnosis and intervention are mandatory for patient survival [2,3]. There is scant literature on the management of complete aortic transection in pediatrics with case reports being the only source [2,4–9]. The purpose of this report is to present the successful management of an adolescent with a large complete thoracic aortic rupture with a 5–6 centimeter (cm) gap, emphasizing the mode of diagnosis along with a systematic literature review. Careful review of the chest radiograph (CXR) identified mediastinal vascular injury. Computed tomographic angiography (CTA) with three-dimensional (3D) reconstruction clearly delineated the location and features of aortic transection. CT helped weigh open repair against endovascular intervention. The patient survived without vascular-related complications and remains well at 3-year follow up.

2. Case report

Emergency medical services were called to the scene immediately after a 16 year old, 80 kg girl was struck by a high-speed automobile. On the scene, she was alert and oriented with a Glasgow Coma Score of 14 (1 verbal point deducted for confusion). Initial vital signs were notable for blood pressure of 110/76 mmHg, heart rate of 170 bpm and oxygen saturation of 85% in room air. The patient was stabilized and transported to the state's only level 1 pediatric trauma center within 30 min of the accident without further decompensation. Evaluation in the trauma bay was most notable for dyspnea, decreased breath sounds, a forehead hematoma without depressed cranial fracture, a left forearm deformity and poor peripheral pulses with moderate hypotension. She was fluid resuscitated for tachycardia and ongoing hypotension but rapidly progressed to a decreased level of consciousness and moderate respiratory distress. CXR showed a widened mediastinum which prompted CT angiography of the chest with 3D reconstruction. This revealed a thoracic aortic transection with a gap of over 5 cm, corresponding to American Association for Surgery of Trauma (AAST) grade IV injury and Aortic Trauma Foundation (ATF) grade IV (Fig. 1) [10].

* Corresponding author.
E-mail address: pantonmartin@phoenixchildrens.com (P. Anton-Martin).

https://doi.org/10.1016/j.epsc.2018.08.001
Received 28 July 2018; Received in revised form 31 July 2018; Accepted 1 August 2018
Available online 06 August 2018
2213-5766/ © 2018 Published by Elsevier Inc. This is an open access article under the CC BY-NC-ND license (http://creativecommons.org/licenses/BY-NC-ND/4.0/).

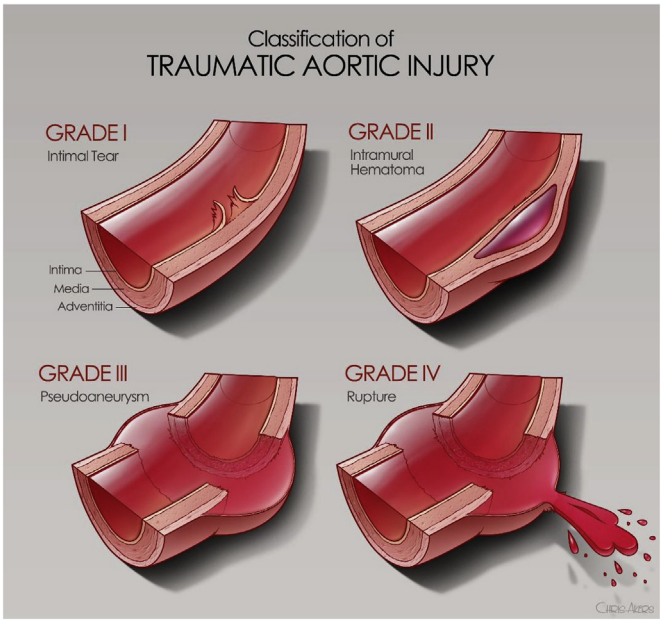

Fig. 1. Thoracic vascular injury grading system - American Association for surgery of trauma (AAST).

There was extravasation of blood into the posterior mediastinum and left pleural space, as well as flow into the distal aorta maintained by periaortic tissue and mediastinal pleura (Figs. 2 and 3). Other major associated injuries included bone fractures and visceral lacerations. While preparing the operative suite, the patient received judicious intravenous fluid and blood product resuscitation, aiming for balanced resuscitation to minimize risk of rupture of the contained transection.

Repair was performed via left thoracotomy. A large hemothorax (1.5 L) was encountered and hemomediastinum was noted to extend around the descending aorta and distal arch. The contained transection was not explored until left heart bypass was instituted. A complete transection of the descending aorta was identified, with approximately 5–6 cm separation between the two ends of the intima. An 18-millimeter (mm) Dacron graft was successfully interposed between the transected areas of the aorta (Fig. 4, A-D). Approximately 3.5 h elapsed between the crash and completion of repair. Postoperative echocardiogram showed normal flow in the abdominal aorta. She remained hemodynamically stable and was extubated to non-invasive ventilation within 24 h of the repair. She subsequently underwent several operations for repair of her other injuries. She was transferred out of the intensive care unit on postoperative day (POD) 13 and was discharged home on POD 48. Over 3 years of outpatient follow-up visits to surgery and cardiology, she has been thriving and has a patent aortic graft with normal Doppler flows and left ventricular function.

3. Discussion

This is a rare case of complete thoracic aortic transection (AAST grade IV/ATF grade IV) in a pediatric patient with a long gap (5–6 cm) between aortic ends. There are other reports of such injuries, but only two pediatric case reports with such a dramatic gap length [4,9]. Our study is consistent with the reported challenge to clearly identify aortic ruptures unless a high index of suspicion is established. Our patient's clinical picture and stable hemodynamics were not suggestive of an aortic injury. However, respiratory difficulty and a wide mediastinum on CXR in the setting of severe blunt trauma indicated that mediastinal vascular injury should be immediately ruled out. Our findings also add data to the previous literature demonstrating the feasibility of achieving intact survival after urgent surgical repair of pediatric aortic ruptures. Furthermore, our study is the first to determine with high accuracy the location and extent of the complete aortic rupture using CT angiography with 3D reconstruction.

Rupture of the aorta is extremely rare and life-threatening in children with an incidence of less than 0.01% of all pediatric trauma patients [1,2]. Motor vehicle crashes are the most common cause of aortic ruptures, and associated multisystem injuries are typical [2]. Overall mortality associated with aortic transection is estimated at 90–94% [11]. Incidence in the pediatric population is exceedingly more infrequent than in adults, which is believed to be due to a few factors. The lack of atherosclerosis in the pediatric aorta imparts inherent pliability to the vessel. Furthermore, greater compliance of the chest wall and flexibility of the aorta's anchor points allows pediatric patients to better absorb acceleration/deceleration impulses without actually disrupting the tissue [2,3]. About 80–90% of these injuries are located in the region of the aortic isthmus because the aorta is anchored on each side, by arch branches and the ligamentum arteriosum, as well as between sternum and vertebral column, so the ability to absorb forces is limited [2,3]. The formation of a hematoma or pseudoaneurysm can contain the hemorrhage, but an estimated 75–85% of patients expire before arrival to the hospital [2,3]. In-hospital death results when rupture of the pseudoaneurysm or hematoma causes fatal hemorrhage [2,3]. Concurrent injuries to the central nervous system, skeletal system, thorax and abdomen contribute to morbidity and mortality both in the field and for those who survive to hospital evaluation [2]. As a pediatric patient, this injury was less likely for our patient, but the severe, abrupt blunt mechanism set up the conditions, and we believe her body habitus limited her aorta's ability to absorb the impulse without disruption.

The risk of exsanguination is extremely high if there is bleeding from the proximal aorta, so survival depends on prompt diagnosis and intervention. Diagnosis can be challenging in less severe grades of aortic injuries, and up to 50% present delayed clinical manifestations over the first 24 h [2,12]. Abdominal pain, dyspnea, and mediastinal widening on CXR with or without hemodynamic instability are classic findings [12]. There may be no evidence of chest or abdominal wall

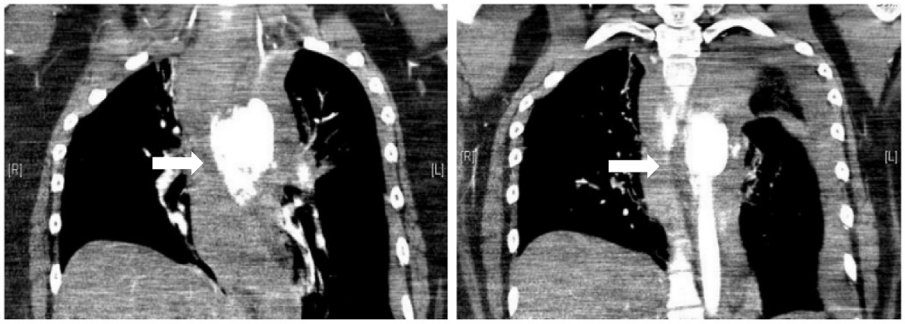

Fig. 2. Chest CT: Acute aortic injury with focal aneurysmal dilatation measuring 4.5 cm in length (with an over 4 cm concomitant gap between the transected aortic ends) and a 2.8 cm × 4 cm transverse dimensions. Active extravasation of blood also noted resulting in a large hematoma in the posterior mediastinum.

Download English Version:

https://daneshyari.com/en/article/8810725

Download Persian Version:

https://daneshyari.com/article/8810725

Daneshyari.com