



# Complication of newborn circumcision: Meatal stenosis or meatal web?

Mehmet Ali Özen<sup>a</sup>, Gökhan Gündoğdu<sup>a</sup>, Mehmet Taşdemir<sup>c</sup>, Egemen Eroğlu<sup>a,b</sup>

<sup>a</sup>Department of Pediatric Surgery, Koç University Hospital, Istanbul, Turkey

<sup>b</sup>Department of Pediatric Surgery, Koç University, School of Medicine, Istanbul, Turkey

<sup>c</sup>Department of Pediatric Nephrology, Koç University Hospital, Istanbul, Turkey

Correspondence to:  
E. Eroğlu, Department of Pediatric Surgery, Koç University, School of Medicine, Topkapı, Maltepe, 34010 Istanbul, Turkey

egemene@amerikanhastanesi.org (E. Eroğlu)

**Keywords**  
Newborn; Circumcision; Stenosis; Web

Received 14 January 2017  
Accepted 2 May 2017  
Available online 2 June 2017

## Summary

### Introduction

Meatal stenosis (MS) is a known complication of newborn circumcision. Symptoms are usually masked in young kids with a diaper. Deflation of urinary stream, dysuria, urinary frequency, and incontinence are the most common reported symptoms. Diagnosis of MS is still controversial. A narrow pinpoint urethral meatus is the current accepted diagnostic criteria.

### Objective

In our practice, we observed that our cases do not overlap to the classic definition and presentation of MS. In this study, we presented our cases and aimed to share our observations.

### Materials and methods

Records of children who had meatoplasty between 2014 with 2016 were analyzed retrospectively. Only children with MS who had had newborn circumcision performed in our clinic were included in the study. Over 500 newborn circumcisions are performed per year in our clinic using the Gomco Clamp technique. Age at diagnosis, presenting complaints, penile anomalies including urethral meatus configuration, urinary symptoms, operation methods, and postoperative follow-up were gathered.

### Results

A total of 13 boys who were circumcised in the newborn period had undergone meatoplasty with the diagnosis of MS.

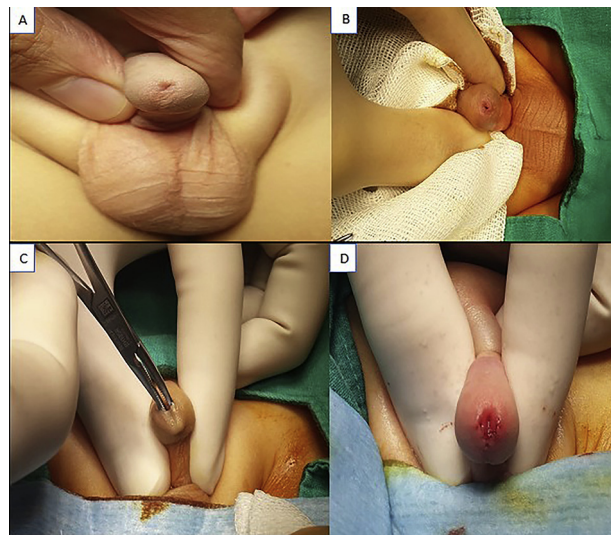
The mean age at the time of meatoplasty was  $52.5 \pm 17.9$  (range 37–93 months). All children were examined before and during the circumcision. There were no associated penile anomalies, including MS. The only presenting complaint was upward deflation of urinary stream instead of other lower urinary tract symptoms. Although the appearance of the meatus was pinpoint in all cases (Figure); it was easy to calibrate with an 8–10 Fr feeding tube. There was no stenosis, but a ventral web was detected. Meatoplasty with removal of this web was performed under general anesthesia. Two sutures were applied at 5 and 7 o'clock with 7/0 PDS. Mean postoperative follow-up time was  $16.9 \pm 7.5$  months. Children were pleased with direction of urinary stream.

### Discussion

Both the diagnosis and morphological definition of MS have some controversies. To our knowledge, there is no similar reported study with pinpoint appearance and normal calibration of the meatus. There was no stenosis in any of them. Unlike classical MS presentations, upward deflation of urinary stream resulting from ventral web was a single presenting complaint.

### Conclusions

Upward deflation of urinary stream can develop after neonatal circumcision because of a meatal web without stenosis, and can be cured easily with meatoplasty. Instead of 'meatal stenosis', 'meatal web' may be a more appropriate term to explain the pathology in these patients.



**Figure** (A, B) Preoperative appearance of external urethral meatus and pinpoint orifice. (C) Picture of ventral web. (D) Meatal opening after meatoplasty.

## Introduction

Meatal stenosis (MS) is a known complication of newborn circumcision [1]. Symptoms are usually masked in infants and young kids in diapers, thus the diagnosis is often delayed until the toilet training stage. Deflection of the urinary stream, dysuria, hematuria, urinary frequency, and incontinence are the most common reported symptoms [2,3]. Diagnosis of MS is still controversial. A narrow pinpoint urethral meatus is the current accepted diagnostic criteria [1,4,5]. However, our cases do not overlap with the classic definition and presentation of MS. In this study, we presented these children who had meatal pathology after newborn circumcision, and aimed to share our observations.

## Materials and methods

An approval statement was obtained from the Koç University Hospital local ethics committee for the study. Over than 500 newborn circumcisions are performed per year in our clinic with the Gomco Clamp technique after routine detailed genital examination of the babies. Records of children who had meatoplasty between 2014 with 2016 were analyzed retrospectively. Only children with MS who had newborn circumcision performed in our clinic were included in the study. Data on age at MS diagnosis, penile anomalies including urethral meatus configuration at newborn circumcision and during the preprocedural genital examination, urinary symptoms including voiding pattern, incontinence and dysuria, operation methods, and postoperative follow-up were gathered. Also, all patients were contacted by phone and current status was recorded.

## Results

A total of 13 boys, who were circumcised in the newborn period had undergone meatoplasty with the diagnosis of MS. Age ranged from 37 to 93 months, with a mean of  $52.5 \pm 17.9$  months at the time of meatoplasty operation. All children had been examined before and during the circumcision and there were no associated penile anomalies, including MS. The only presenting complaint in children with MS was upward deflation of urinary stream, instead of other lower urinary tract dysfunction symptoms. Although the appearance of the meatus was pinpoint in all cases; it was easy to calibrate with a lubricated 8–10 Fr feeding tube. There was no stenosis, but a ventral web was detected. Meatoplasty with removal of this web was performed under general anesthesia. After web removal, two sutures were applied at 5 and 7 o'clock with 7/0 PDS, and no catheter was left after the procedure. Daily calibration was applied for 2 weeks with the conical tip of an antibacterial eye pomade. Children were symptom-free during the mean postoperative follow-up time of  $16.9 \pm 7.5$  months. All of the patients and their parents were pleased with the caliber and direction of the urine stream according to the information received in the phone call.

## Discussion

Circumcision is one of the most common surgical procedures performed in boys. It can be performed in a wide range of age periods [6–9]. Our preference for timing of surgery is the newborn period for several reasons, including feasibility by local anesthesia and fast recovery period [10,11]. Over 500 newborn circumcisions are performed per year in our pediatric surgery department. However, circumcision can be associated with potential complications such as bleeding, removal of excessive or inadequate foreskin, buried penis, penile injury, and MS [12–14]. MS usually occurs after newborn circumcision and is very rare in uncircumcised boys [5,12,15]. It can be seen congenitally as a component of Townes Brocks syndrome, Kindler Syndrome, hypospadias and isolated; or can be acquired after hypospadias repair, penile trauma, prolonged urethral catheterization, and balanitis xerotica obliterans (BXO) [16–18]. No systemic, metabolic, or syndromic disease was detected in these patients. The meatal web is also described in girls as an anomaly that disturbs the direction of urinary flow, which also requires a surgical correction [19,20]. This study is only concerned with healthy children, who had MS after newborn circumcision. Other causes of MS are beyond the scope of this study.

In the present series, all of the babies were examined routinely before and during the newborn circumcision procedure, and no penile anomaly including urethral meatus configuration was detected [21]. All meatal problems developed post-operatively over the specified timeframe. So MS was not a congenital lesion in these children. While its etiology is uncertain, the most popular theory is that the meatal mucosa undergoes chronic irritation in the absence of a prepuce which results in meatus losing its elliptical shape to a rounded one [22]. Another theory states that ischemia after damage to the frenular artery during circumcision, results in poor blood supply to the meatus and subsequent fusion of the ventral sides of the orifice [2]. Shenoy et al. mentioned that MS is not seen after circumcision if the frenular artery is protected [23]. These two hypothetical scenarios may explain the etiology in these children. The glans is more prone to diaper rash after removal of the prepuce, and it may not be possible to protect frenular artery during newborn circumcision with a Gomco clamp.

The incidence of MS was reported in a wide range, from 0.2 to 20.4%, after neonatal circumcision [4,24,25]. In the Van Howe study none of the noncircumcised boys were diagnosed with meatal stenosis while it occurred in 7.29% of those circumcised at birth. He suggested that meatal stenosis might be the most common complication following neonatal circumcision [26]. In another study, reported incidence of MS was 20.4% after neonatal circumcision [4]. In one of the largest series, Eroğlu et al. reported a much lower incidence of MS than the others (0.31%) in his 1050 newborn circumcisions [27].

Meatal stenosis has varied presenting symptoms in the literature. In the study by Mahmoudi the most common symptom was dysuria in 35% of the patients with MS [5]. Noe et al. reported that the most common presenting symptom

Download English Version:

<https://daneshyari.com/en/article/8811827>

Download Persian Version:

<https://daneshyari.com/article/8811827>

[Daneshyari.com](https://daneshyari.com)