

Bone tumours in childhood and adolescence

Vicki Lee

Abstract

Primary bone tumours are rare diseases in children and young people. Osteosarcoma and Ewing sarcoma are the commonest types of bone tumour in this age group. Whilst other rarer tumours occur their presentation and investigation are similar and their treatment will be individualised by specialist teams. We will therefore focus in on the challenges faced in the presentation, timely diagnosis, treatment and rehabilitation in young growing individuals with osteosarcoma and Ewing Sarcoma.

Keywords bone tumours; Ewing sarcoma; osteosarcoma; paediatrics

Epidemiology and genetics

Osteosarcoma is a malignancy of the primitive bone-forming mesenchyme. They are tumours of *growing* bone. They are the sixth commonest malignancy of childhood and the third commonest in adolescents and young adults. The peak incidence is in the second decade of life which coincides with the adolescent growth spurt. It has been noted that patients with osteosarcoma are statistically taller than their peers and the peak incidence in girls occurs earlier than in boys corresponding to the timing of the growth spurt in each gender. The male propensity is attributed to the larger total bone volume which is also formed over a longer growth period in boys. Osteosarcoma has a predilection for those metaphyseal parts which grow most rapidly in adolescence e.g. distal femur, proximal tibia and proximal humerus, However they can occur in any bone of the body.

The aetiology of osteosarcoma is unknown. There is a higher incidence in Afro-Caribbean population than in Caucasians. Rarely, some individuals have a genetic predisposition to osteosarcomas. These include those with the hereditary retinoblastoma gene, Li-Fraumeni syndrome and Rothmund-Thomson syndrome. There is also a higher incidence in those treated with ionising radiation and alkylating chemotherapy agents for previous disease. The majority of patients however will not have an obvious predisposition at presentation.

The origin of the small round blue cells of Ewing sarcoma remains a much debated enigma. Whilst this tumour is commonest in the second decade of life with a median presentation age of 15 years they have a wider age distribution of occurrence than osteosarcoma. They are slightly commoner in males and have a predilection to Caucasians. Unlike osteosarcoma, the axial

skeleton is a more common site for Ewing's sarcoma and when long bones are involved the diaphysis is the most common site.

Classical Ewing sarcoma is of the bone. However extra-skeletal Ewing sarcoma, Askin tumour of the thoracic wall and peripheral neuroectodermal tumour form a group known as the Ewing sarcoma family of tumours that share molecular, immunological and genetic traits. In 85% of these tumours a reciprocal chromosomal translocation of chromosomes 11 and 22, the t(11;22) (q24;q12) is present. This is a genetic characteristic of the tumour rather than the individual who has the tumour.

Natural history and pattern of spread

Osteosarcoma is a primary disease of bone which can metastasise. Lung and bone are the commonest metastatic sites. Historically, with surgical resection of primary tumour alone, only 20% of patients survived. Of the 80% who died, most had fatal metastatic lung disease in first 2 years following diagnosis.

Those with metastatic bone disease or multiple primary sites at diagnosis have an extremely poor prognosis. Fortunately only 15%–20% have visible metastatic disease at presentation. The very poor outcome prior to the introduction of chemotherapeutic agents implies that many more have micrometastases which cannot be readily detected at diagnosis.

Ewing sarcoma is characteristically a more obviously systemic disease at initial presentation. Ewing sarcomas occur most commonly in the pelvic bones, diaphysis of the long bones of the legs and bones of the chest wall. At presentation 25% will have metastatic disease to the lung, bone or bone marrow or a combination of these. Prior to chemotherapeutic interventions only 10% of patients survived with the majority succumbing to metastatic disease in the first two years.

Clinical presentation

In both tumour types localised pain is the most common presenting symptom. It usually predates soft tissue swelling. Occasionally a pathological fracture of the affected bone, which is structurally weak, may predate soft tissue swelling and lead to presentation.

In a population who are young and physically very active the pain is often initially erroneously attributed to injury. At diagnosis the average duration of symptoms for osteosarcoma is 3 months though for some it may be 6 months or longer. The median for Ewing sarcoma is 3–9 months. An adolescent or child whose pain has any of the following characteristics should be investigated to exclude a bone malignancy with at least a plain X-ray.

1. A painful 'injury' which fails to resolve over a reasonable time (more than 1 month)
2. Intermittent or persistent localised pain for one month with no history of trauma
3. Night pain that wakes the individual from sleep or prevents adequate sleep.
4. Fracture where history of force resulting in injury seems insufficient.

Delays in time to diagnosis may involve a combination of a low index of suspicion on the part of clinicians and denial and lack of awareness in teenagers and young adults.

The time to diagnosis can also be significantly affected by the site of the tumour. Soft tissue swelling may be easily identified in the arm of a thin individual, less easily in the thigh of a heavier

Vicki Lee MB ChB MRCP(UK) MRCPCH is a Consultant Paediatric Oncologist lead clinician in the treatment of bone tumours and in the Neuro-Oncology Service at Sheffield Children's NHS Foundation Trust, Sheffield, UK. Conflict of interest: none declared.

teenager and a very large pelvic or internal chest wall masses may remain hidden from the observer for a long time before they are clinically evident in a patient experiencing pain and dysfunction.

Osteosarcoma most commonly presents with local pain followed by swelling at the site of the primary tumour. Even when they are present pulmonary metastases tend to remain asymptomatic at presentation. Patients rarely have systemic symptoms such as fever, weight loss, and fatigue unless they have very extensive disease at presentation. Ewing sarcoma on the other hand typically present with more systemic symptoms such as fever, weight loss, and fatigue. However, local symptoms are possible and spinal disease may present with pain or even spinal cord compression.

Investigation and diagnosis

Plain X-ray in two planes of the painful area remains the first line investigation of choice and is readily available to most clinicians.

Both osteosarcoma and Ewing sarcoma can lead to an important radiological sign, Codman triangle. Codman triangle is the triangular area of new subperiosteal bone that is created when a lesion, often a tumour, raises the periosteum away from the bone. Osteosarcomas traditionally present on X-ray with destruction of the normal trabecular pattern and lifting of the periosteum due to intense new bone formation (Codman's triangle). They are classically metaphyseal in location. 45% will be osteosclerotic and 30% osteolytic with the remaining 25% being a mixture of both. Ewing sarcomas traditionally demonstrate osteolysis, detachment of the periosteum and occasional calcification in any associated soft tissue mass.

Whilst plain X-ray films are helpful in identifying an abnormality of bone in a person experiencing pain further imaging is required to adequately define the extent of that disease and for staging (see Figures 1–5). Biopsy is the gold standard for histological diagnosis to guide treatment.

MRI imaging of the affected bone is required to define true tumour extent in bone and surrounding muscle groups and relationship to important structures such as nerves, blood vessels and other organs. This information guides surgeons in local control of the tumours through surgery.

Whole body technetium-99m bone scan and chest CT are performed to assess metastatic disease at presentation. These are

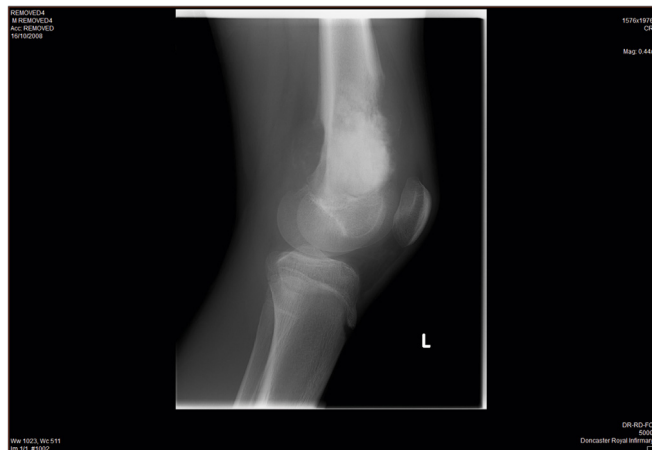

Figure 1 Plain X-ray AP and Lateral of teenager with osteosarcoma of distal femur.

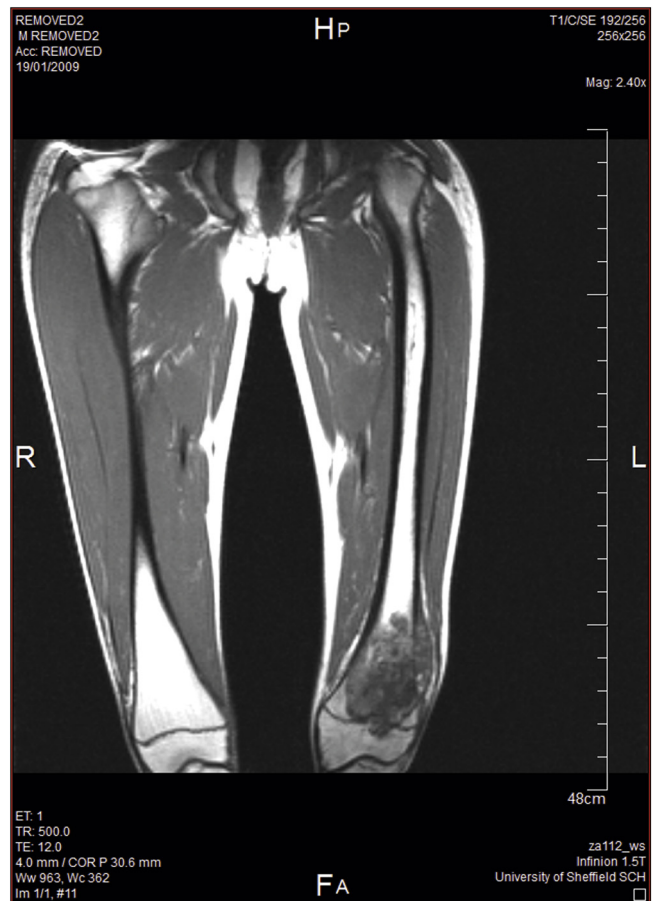

Figure 2 MRI of same patient in figure one.

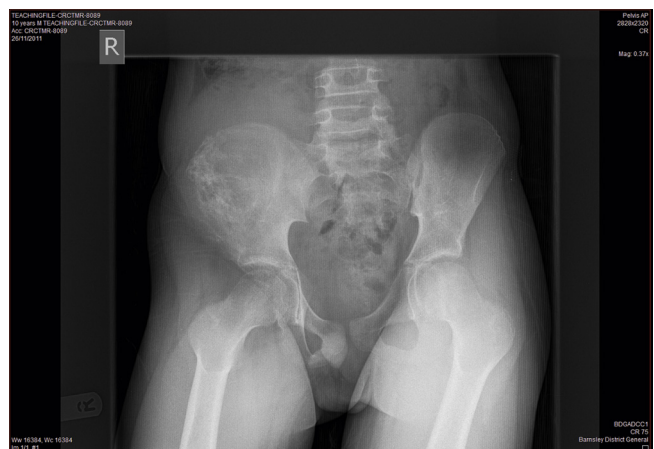


Figure 3 Plain X-ray pelvis of young man of 10 years with learning difficulty presenting with reduced mobility, poor appetite and altered behaviour due to pain from a large pelvic Ewing's sarcoma.

essential in providing accurate information on prognosis and in subsequent disease monitoring during and following treatment. Ideally the CT chest is best performed awake and not in the days immediately after general anaesthesia for biopsies or MRI as post-anaesthetic atelectasis can make interpretation difficult.

Bone marrow aspirates and trephines are required for Ewing sarcoma patients as marrow involvement is a part of the disease process and for some high dose procedures requiring harvest of stem cell from the patient may be part of their treatment.

Download English Version:

<https://daneshyari.com/en/article/8813103>

Download Persian Version:

<https://daneshyari.com/article/8813103>

[Daneshyari.com](https://daneshyari.com)