



## Case report

## Asymmetric bilateral traumatic hip dislocation: A case report

Ahmed Alshammari<sup>a</sup>, Basam Alanazi<sup>a</sup>, Ismail Almogbil<sup>a</sup>, Saud M. Alfayez<sup>b,\*</sup><sup>a</sup> Orthopedic Department, King Saud Medical City, Riyadh, Saudi Arabia<sup>b</sup> Department of Orthopedic Surgery, College of Medicine, King Saud University, Riyadh, Saudi Arabia

## ARTICLE INFO

## Keywords:

Hip dislocation  
Bilateral  
Asymmetric  
Traumatic  
Case report

## ABSTRACT

**Introduction:** Traumatic hip dislocation is a severe injury with the potential for significant morbidity and mortality. Bilateral hip dislocation is rare representing 1.25% of all hip dislocations.

**Presentation of the case:** A 19-year-old male had a high-speed motor vehicle accident. After stabilizing the patient, it was noticed that the position of the right lower limb was in adduction and internal rotation while the left was in external rotation and abduction. Pelvis x-ray showed right superior posterior and left anterior inferior hip dislocations. Closed reduction was performed within 3 hours from the trauma for both sides. The post reduction CT scan showed adequate reduction of both hips with no associated fractures. During his three-year follow-up, he never had any complaints and the clinical examination and radiographs did not reveal any abnormalities.

**Discussion:** Early reduction of hip dislocations minimizes the risk of osteonecrosis of the femoral head. The current recommendations state that a hip dislocation must be reduced within 6 hours.

**Conclusion:** This is a rare case of bilateral asymmetric hip dislocations with no concomitant fractures. It is important to reduce hip dislocation within 6 hours from the time of injury to prevent osteonecrosis of the femoral head.

## 1. Introduction

Traumatic hip dislocation is a severe injury with the potential for significant morbidity and mortality. The cause is almost always traumatic and usually associated with motor vehicle accidents. Posterior dislocation is the most common type constituting 85–90% of hip dislocations [1].

Bilateral hip dislocation is a rare injury representing 1.25% of all hip dislocations [2]. Asymmetrical dislocations are even more rare accounting for approximately 0.01–0.02% of all joint dislocations [3]. Careful trauma evaluation is important in order to rule out common associated injuries that may lead to a long-term morbidity. Early reduction within 6 hours is the mainstay management to prevent the complication of avascular necrosis (AVN) [1].

In this article, we present a rare case of asymmetric dislocations of the hips with no associated fractures in a young man and the outcome after a three-year follow-up. This case report adds to the scarce existing data about bilateral hip dislocation including the mechanism, clinical and radiographic findings and outcome. The article was reported in line with the SCARE criteria [4].

## 2. Case report

A 19-year-old man, with no known medical illnesses, was brought by ambulance to the emergency room at our community hospital following high-speed collision into another vehicle. On arrival, ATLS protocol was carried out. Although the primary survey showed a patent airway with good bilateral air entry, the patient was in respiratory distress. Chest x-ray showed right pneumothorax. An intercostal tube was inserted by the thoracic surgeon. His vital signs were stable at that time. Pelvis x-ray showed right superior posterior and left anterior inferior hip dislocations (Fig. 1). The position of the right lower limb was in adduction and internal rotation while the left was in external rotation and abduction. The patient had intact motor function, sensation, and pulses distally throughout the lower and upper extremities. Chest, abdomen and pelvis CT scan was done revealing right pneumothorax, right posterior hip dislocation and left anterior hip dislocation with no obvious fractures (Fig. 2). Under conscious sedation, closed reduction was performed within 3 hours from the trauma for both hip dislocations. After reduction, both hips were noted to be stable throughout the range of motion with intact distal neurovascular status. The post reduction radiographs (Fig. 3) and CT scan (Fig. 4) showed adequate reduction of both hips with no associated fractures. The patient was admitted in the trauma ward and kept in skin traction for both hips for

\* Corresponding author.

E-mail address: [alfayezsaud@gmail.com](mailto:alfayezsaud@gmail.com) (S.M. Alfayez).

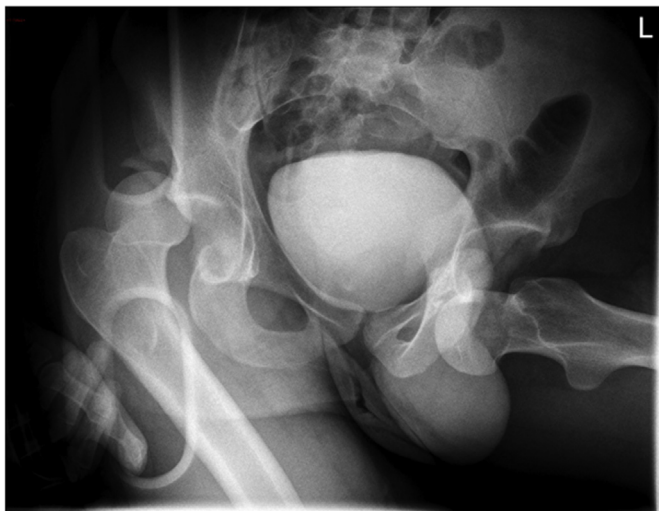


Fig. 1. Pre-reduction x-ray.

6 weeks as requested by one of the senior trauma surgeons involved in his care but there was no clear indication from the orthopedic surgeons perspectives. He was given analgesia and antithrombotic medications during his stay. He was discharged on the 6th week after he became able to fully weight bear. During his three-year follow-up, he never had any complaints and the clinical examination and radiographs did not reveal any abnormalities (Fig. 5).

### 3. Discussion

Hip dislocation is more common among young male patients [3]. It usually occurs due to motor vehicle accidents resulting in a severe deceleration force to a flexed knee; associated injuries are acetabular fractures and knee injuries [2].

Posterior hip dislocations are sustained in dashboard injuries as the force toward the knee is directed posteriorly while the hip is in flexion position. Anterior hip dislocations, representing approximately 11% of all hip dislocations, usually result when the hip is forced into abduction

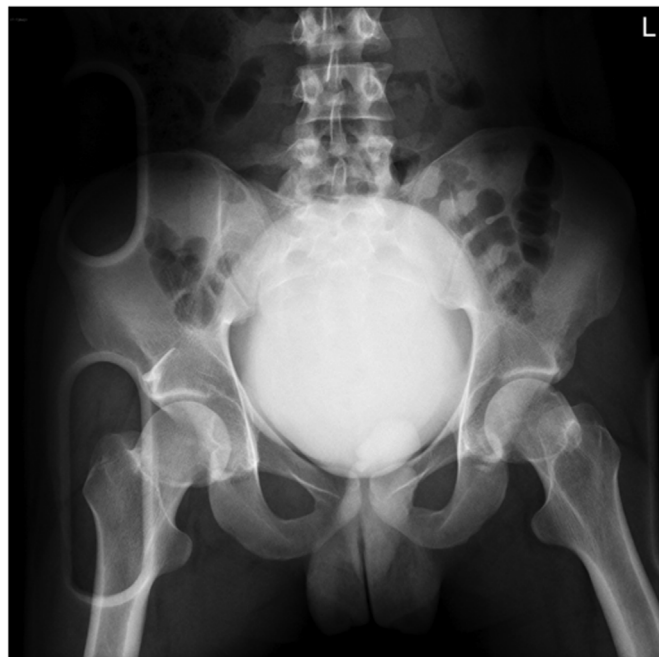

Fig. 3. Post-reduction x-ray.

and external rotation. In this regard, fractures of the femoral head and shaft may occur in such circumstances [2,5]. Suggestive findings on examination include shortening, internal rotation, and adduction of the lower limb which is associated with posterior hip dislocation. On the other hand, a flexed, abducted, and externally rotated lower limb indicates an anterior inferior dislocation [6].

Pelvic radiographs should be done in the multiple-trauma patient as part of the ATLS protocol especially when clinical findings are suggestive of hip dislocation. Judet views are useful for identifying associated acetabular fractures [7]. CT scan of the hip is usually not necessary prior to reduction but few cuts can be obtained in a multiple-trauma patient who has other indications for a CT scan. This is

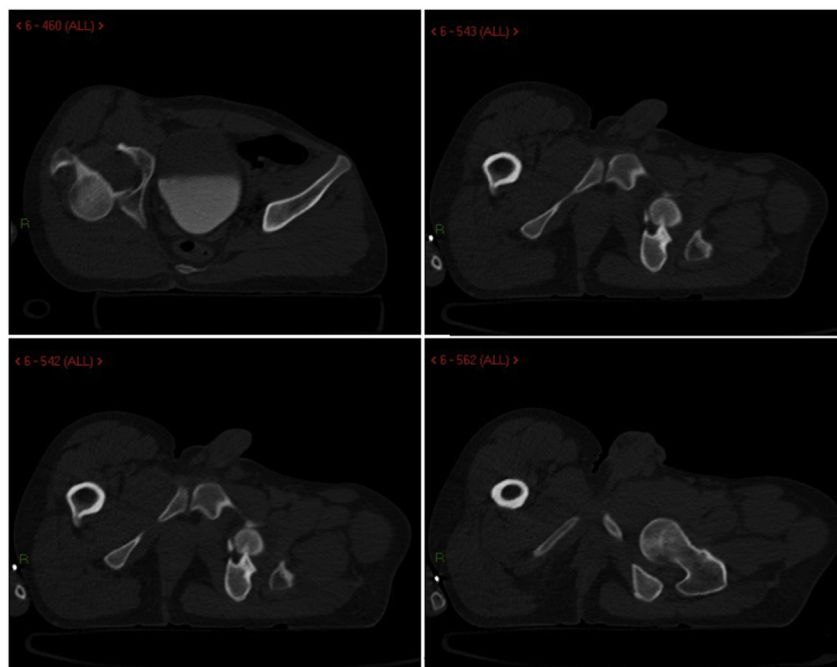


Fig. 2. Pre-reduction CT scan.

Download English Version:

<https://daneshyari.com/en/article/8817230>

Download Persian Version:

<https://daneshyari.com/article/8817230>

[Daneshyari.com](https://daneshyari.com)