



## Case report

## Management of a postbulbar duodenal ulcer and stricture causing gastric outlet obstruction: A case report

Maxwell D. Mirande<sup>a,\*</sup>, Raul A. Mirande, MD, FACS<sup>b</sup><sup>a</sup> OMS II at Western University of Health Sciences, College of Osteopathic Medicine of the Pacific-Northwest, 200 Mullins Drive, Lebanon, OR 97355, United States<sup>b</sup> Chairman of the Surgical Services Executive Committee, Department of General Surgery at Sky Lakes Medical Center, 2865 Daggett Ave, Klamath Falls, OR, United States

## ARTICLE INFO

## Keywords:

Peptic ulcer disease  
Gastric outlet obstruction  
Duodenum  
Stricture  
Strictureplasty

## ABSTRACT

**Introduction:** Peptic ulcer disease has significantly decreased over the past several decades making the need for definitive surgical intervention an infrequent occurrence.

**Presentation of Case:** A 44-year-old Caucasian female was sent to the emergency department by her primary care physician for right upper quadrant abdominal pain which had been intermittent for the past two months but acutely worsened over the last five days. During this time, she was unable to tolerate oral intake with intractable nausea and vomiting. Upper GI endoscopy revealed a tight stricture in the second part of the duodenum and antral biopsy was *Helicobacter pylori* negative. Patient underwent two rounds of balloon dilation with short lived symptomatic relief. An open pylorus-preserving duodenal strictureplasty using a Heineke-Mikulicz technique was then performed. The operation was successful and the patient has had no reoccurrence of her symptoms.

**Discussion:** Gastric outlet obstruction is an uncommon complication of peptic ulcer disease in respect to chronic nonsteroidal anti-inflammatory drug use. The unique location of the patient's stricture and her desire to minimize post-operative GI alterations demanded a review of surgical options and identified the benefits of maintaining the patient's original anatomy versus choosing an extra-anatomic approach.

**Conclusion:** This case presented a unique challenge and demonstrated the need for definitive surgical interventions in the treatment of peptic ulcer induced gastric outlet obstruction. This case adds support for the direct anatomic treatment of duodenal strictures when conservative measures fail and perhaps promotes further development of laparoscopic management of gastric outlet obstruction in the future.

## 1. Introduction

The incidence of peptic ulcer disease (PUD) has significantly decreased over the past several decades with the development of pharmacological agents such as H2 blockers and proton pump inhibitors (PPIs) [1]. Additionally, the discovery of *Helicobacter pylori* (*H. pylori*) as a leading cause of PUD and its treatment have made the need for definitive surgical intervention fairly uncommon [2,3]. However, complications such as hemorrhage, perforation, and gastric outlet obstruction (GOO) still occur. Although advancements in endoscopic therapies such as balloon dilation and stenting can be successful [4–6], there is still a role for surgical intervention. We present a unique case of a postbulbar duodenal ulcer and stricture causing GOO secondary to chronic nonsteroidal anti-inflammatory drugs (NSAIDs) use in a 44-year-old female and discuss her management and surgical treatment. This case report has been reported in line with the SCARE criteria [7].

## 2. Presentation of Case

A 44-year-old Caucasian female was sent to the emergency department by her primary care physician (PCP) for right upper quadrant abdominal pain which had been intermittent for the past two months but acutely worsened over the last five days. During this time, she was unable to tolerate oral intake with intractable nausea and vomiting. Patient denied any hematemesis or melena. Patient has a past medical history of irritable bowel syndrome, gastroesophageal reflux disease, iron deficiency anemia, and chronic headaches treated for years with excess use of acetaminophen/aspirin/caffeine and ibuprofen. Her past surgical history includes a cholecystectomy, an appendectomy, and multiple spine surgeries. An outpatient barium upper GI study (UGI) ordered by the patient's PCP two days prior noted a mottled filling defect within the stomach consistent with a bezoar and a tight narrowing in the second part of the duodenum with a deep medial ulcer noted (Fig. 1). An abdominopelvic CT with IV contrast was completed the next day and did not identify any obvious bowel obstruction, mass,

\* Corresponding author. 200 Mullins Drive, Lebanon, OR 97355 United States.

E-mail addresses: [mmirande@westernu.edu](mailto:mmirande@westernu.edu) (M.D. Mirande), [mirandemd@live.com](mailto:mirandemd@live.com) (R.A. Mirande).

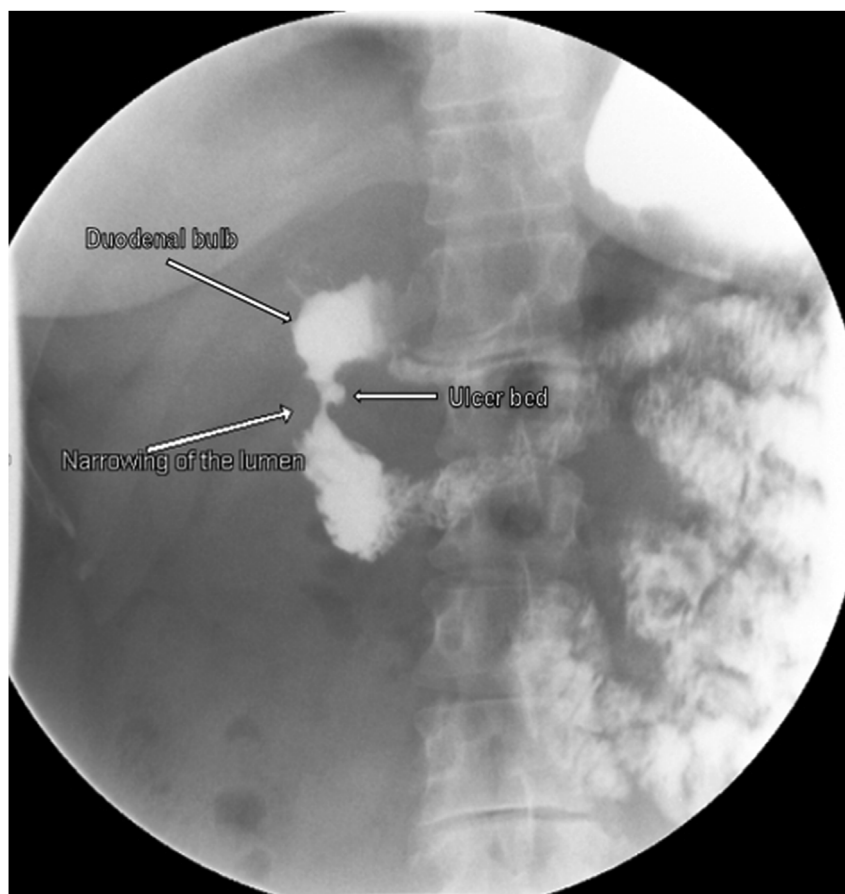


Fig. 1. Initial outpatient barium upper GI study showing a tight narrowing in the second part of the duodenum (postbulbar).

annular pancreas, or inflammatory changes to explain the patient's continued symptoms. Surgery was consulted and the patient was admitted to the hospital.

The patient was immediately treated with nasogastric tube decompression, sucralfate, and maximal IV PPIs. The patient underwent an esophagogastroduodenoscopy (EGD) the next day which demonstrated distal esophagitis, gastritis, a food bezoar, and a tight stricture in the second part of the duodenum just proximal to the major duodenal papilla. There was significant mucosal edema and erythema above and below the stricture making the medial ulcer bed difficult to visualize. Endoscopic biopsy showed mild chronic nonspecific inflammation duodenal mucosa. Antral biopsy was negative for *H. pylori* on H&E and immunohistochemical stains. Balloon dilation successfully enlarged the duodenal lumen diameter without an obvious complication. She was maintained on sucralfate and maximal IV PPIs with her oral intake slowly advanced as tolerated.

She reported almost immediate relief of her nausea and vomiting and had a nearly pain free abdominal exam. After a few days of relief, unfortunately, the patient's symptoms returned. After consulting gastroenterology, a second EGD was performed for further biopsies, balloon dilatation of the recurrent stricture was repeated, and a triamcinolone acetonide submucosal injection was administered.

The patient again had immediate improvement after the repeat dilation but her symptoms recurred within 24–36 hours. After extensive discussions with the patient, gastroenterology, and multiple regional tertiary referral centers, we proceeded with an exploratory laparotomy with formal Kocher maneuver, a pylorus-preserving duodenal stricturoplasty utilizing a Heineke-Mikulicz technique, and an 8 French feeding tube placement into the first portion of the jejunum. The firm chronic ulcer bed, approximately 2 cm in diameter, involved approximately one third of the posteromedial circumference of the duodenum without

pancreatic or common bile duct involvement. The patient was quickly advanced to full liquid diet and her feeding tube was removed. The patient was discharged home five days later tolerating her full liquid diet and continuation of the same medication regimen. A follow up UGI a month later showed a widely patent duodenum without signs of obstruction (Fig. 2). At six months post-operative, the patient had no recurrence of her GOO. At more than one year following her procedure, the patient has had no recurrence of abdominal pain, GERD, gastritis, ulceration, GOO, or any new GI complaints.

### 3. Discussion

Benign GOO is the most uncommon complication of PUD, only occurring in about 3% of cases [2]. Additionally, GOO due to excessive NSAIDs use is quite infrequent as up to 94% of duodenal ulcers are caused by *H. pylori* [8,9]. In our case, the patient had a history of chronic headaches with the excessive use of acetaminophen/aspirin/caffeine and ibuprofen which lead to the development of an ulcer and obstruction in the second part of the duodenum. The location of her ulcer and stricture just proximal to the major duodenal papilla was also unusual as ulcers most commonly occur in the antrum of the stomach and duodenal bulb [10].

Current management of benign GOO begins with conservative measures such as IV PPIs, sucralfate, cessation of NSAIDs use, treatment of *H. pylori* when applicable, and gastric decompression. Recent research has shown the use of endoscopic balloon dilation and medical therapy to be associated with favorable long-term outcomes and is considered to be first-line treatment of benign GOO [11,12], but one-third of patients may ultimately require surgical intervention [13]. It has also been suggested that patients who are *H. pylori* negative may have less success with endoscopic balloon dilation [14]. As the

Download English Version:

<https://daneshyari.com/en/article/8817258>

Download Persian Version:

<https://daneshyari.com/article/8817258>

[Daneshyari.com](https://daneshyari.com)