



Case report

Post-primary pulmonary TB haemoptysis – When there is more than meets the eye

Ubaid Feroze Seedat*, Faheem Seedat

Department of Internal Medicine, Chris Hani Baragwanath Academic Hospital and Faculty of Health Sciences, University of the Witwatersrand, Johannesburg, South Africa

ABSTRACT

Haemoptysis is concerning for both patient and healthcare provider and points to the presence of severe underlying lung disease warranting investigation. Approximately 8% of patients with pulmonary tuberculosis (PTB) infection will experience haemoptysis at some point during their life^[1,2]. The aetiology of haemoptysis in the setting of PTB is diverse and may occur during active or following prior PTB infection due to pulmonary complications. We describe the case of a 33-year-old female who presented with massive haemoptysis on two separate occasions within a five-month period. Her background history included PTB 6 years prior and subsequent post-TB bronchiectasis with a destroyed left lung, and the development of apical mycetoma's. Despite numerous pre-existing aetiologies that could account for haemoptysis in this patient, on this admission, a newly identified ruptured Rasmussen's aneurysm was identified by angiography and successfully treated with arterial embolization. This report serves to highlight the multitude of reasons for haemoptysis in a patient with post PTB lung destruction and the associated diagnostic challenges that may be present. In particular, we highlight the Rasmussen's aneurysm, a rare entity, as a hidden cause of haemoptysis, where despite extensive parenchymal lung disease identified on chest radiography, specialised imaging is needed to confirm the diagnosis.

1. Background

Tuberculosis (TB), remains a significant health burden in the developing world despite medical and technological advances. As of 2015, South Africa remains in the top 6 of both the worldwide incidence and prevalence of TB, with haemoptysis being a closely associated symptom [3]. Despite 81% of PTB patients achieving cure, haemoptysis may present in the post - PTB patient, and may be related to parenchymal distortion and associated vascular complications associated with prior PTB [3]. This report aims to highlight the numerous aetiologies accounting for haemoptysis in a post-primary PTB patient, with emphasis on the Rasmussen's aneurysm, a rare but established entity with possible life-threatening consequences.

2. Case study

A 32-year-old HIV seronegative female patient, currently working as a research assistant in a healthcare facility presented with a second episode of massive haemoptysis within a 5-month period. She had been diagnosed with microbiologically proven PTB 6 years prior to her admission and completed 6 months of therapy. However, this was complicated by fibro-cavitary destruction of her left lung with post-TB bronchiectasis (Fig. 1). Over the course of her follow up at the pulmonology clinic, and 2 years prior to this current presentation, she developed apical mycetoma's, which were identified on computed

topographical scan of the chest (Fig. 2) and due to evident haemoptysis, she was considered for a left pneumonectomy. Her lung function test showed a restrictive lung pattern with a FEV1 of 64%, a FVC of 67% (FEV1/FVC of 95) and a DLCO of 74. Furthermore, a nuclear medicine split perfusion scan indicated no discernible perfusion to the affected lung. An electrocardiogram and echocardiogram were performed, indicating the presence of pulmonary hypertension.

On examination during this admission, she was haemodynamically stable with a blood pressure of 127/82 mmHg and a sinus tachycardia of 110 beats/min. She was afebrile, her respiratory rate measured 20 breaths/min and she was a-cyanotic on room air with an oxygen saturation of 93%. Marked digital clubbing and subconjunctival pallor were noted. On respiratory examination, evidence of left sided volume loss was present with decreased expansion of the left chest wall and compensatory hyperinflation of the right. The breath sounds on the right were vesicular in nature but the left side had breath sounds of reduced intensity with amphoric breath sounds and coarse crackles predominantly in the upper zone. No evidence of decompensated cor pulmonale was present on cardiovascular examination, but pulmonary hypertension and mediastinal shift to the left were evident. A parasternal heave with a palpable P2 were elicited, as was a loud pulmonary component of the second heart sound. Her apex beat was displaced to the anterior axillary line in the fifth intercostal space with tracheal deviation to the left side. Initial laboratory results showed a microcytic hypochromic anaemia with a haemoglobin of 7.7 g/dL (MCV = 73.8fl;

* Corresponding author. P.O. Box 732, Auckland Park, 2006, South Africa.
E-mail address: ubaidseedat@gmail.com (U.F. Seedat).

<https://doi.org/10.1016/j.rmcr.2018.07.006>

Received 18 June 2018; Received in revised form 25 July 2018; Accepted 26 July 2018

2213-0071/ © 2018 The Authors. Published by Elsevier Ltd. This is an open access article under the CC BY-NC-ND license (<http://creativecommons.org/licenses/by-nc-nd/4.0/>).

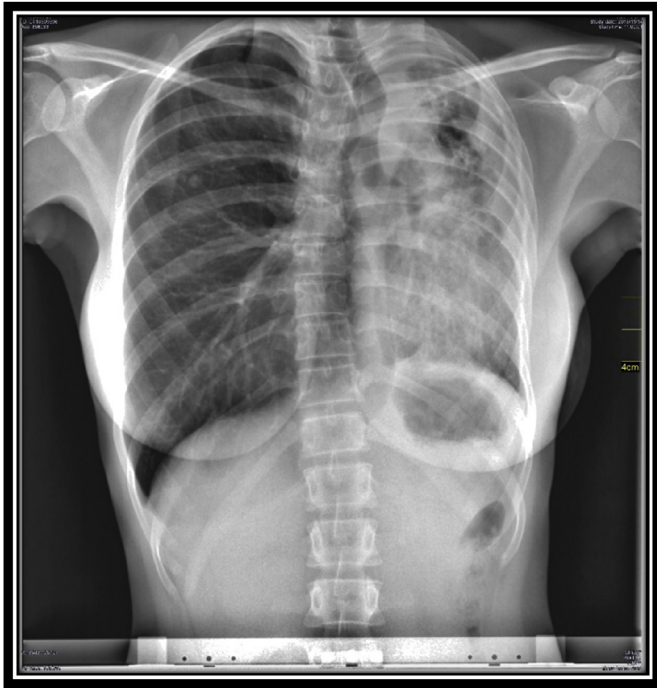


Fig. 1. Chest X-ray demonstrating mediastinal shift secondary to left lung fibrocavitary destruction.

MCHC = 31.4g/dL) and a platelet count of $487 \times 10^9/l$. Further haematological work-up demonstrated an iron-deficiency anaemia with a ferritin of 37 $\mu\text{g/l}$, percentage saturation of 5% and associated morphological features. Her renal and liver function tests were normal. Her C-Reactive Protein was 32mg/L and her INR measured 1.28. An Xpert MTB/RIF assay was performed and was reported as negative for *Mycobacterium tuberculosis*.

She was admitted to medical high care. Transfused 1 unit of packed red blood cells and initiated on oral codeine phosphate. An emergency computed topographical pulmonary angiogram (CTPA) was performed and suggested the presence of a Rasmussen's aneurysm but formal angiography was deemed necessary for confirmation. Direct angiography indicated a pulmonary arterial blush adjacent to the left upper lung cavity confirming the presence of a Rasmussen's aneurysm (Fig. 3). Despite difficult initial ventilation due to her diseased lung, selective right bronchial intubation was performed and successful arterial embolization was achieved. Following 48 hours of post-procedural monitoring in a high care setting, she was stepped down to the general medical ward where after 6 days of remaining haemoptysis free, she was discharged home and is currently awaiting left sided pneumonectomy.

3. Discussion

Haemoptysis, the coughing up or expectoration of blood, is a worrying symptom and usually serves as an indicator of severe underlying lung pathology. Massive haemoptysis is a term reserved for a large volume of blood expectorated within a 24-h period, with the potential for morbidity and mortality stemming from haemodynamic instability, airway compromise and gaseous exchange abnormalities. There is no universal consensus on the precise volume of blood to define massive haemoptysis, and the most acceptable quantifiable definition refers to values ranging from 200 to 1000 ml over a 24-h period, to a bleeding rate of 100ml per hour [4].

South Africa is a WHO high burden country [3], but there is a dearth of literature assessing the prevalence of post-PTB related lung disease in South Africa, however, experts in South African pulmonary medicine

believe PTB to be a significant contributor to chronic lung disease in the region, and is an important cause of haemoptysis. Active PTB may present with both trivial and significant degrees of haemoptysis and a sizeable proportion of haemoptysis is secondary to active PTB, as highlighted by an older South African case series where up to 73% of massive haemoptysis was attributable to active TB and this is supported by a recent study of HIV positive patients with diabetes who were 31 times more likely to have active TB if haemoptysis was a presenting symptom [5,6]. Although haemoptysis is strongly associated with active pulmonary TB infection, it may also present following resolution of acute disease due to subsequent pulmonary complications [1,2]. Unfortunately there is no data assessing the prevalence of haemoptysis amongst patients with active PTB compared to those with haemoptysis from post-primary PTB pulmonary complications. Thus even though the aetiologies of haemoptysis are varied and multi-systemic, in a high TB burden setting, its presence should always alert the physician to the possibility of active PTB.

Haemoptysis originates from local blood supply, being derived from both pulmonary and bronchial arteries. The pulmonary arterial system carries the entirety of the cardiac output through a relatively low-pressure system for oxygenation whilst the bronchial artery and its tributaries carry oxygenated blood to the lung parenchyma, and despite a much smaller volume are under high systemic pressures. In 90% of cases with massive haemoptysis, bleeding originates from these high-pressure bronchial artery networks [7]. Numerous possibilities are present when considering the aetiology of haemoptysis in the post-primary TB patient. Although the pathogenesis of haemoptysis, as a sequelae of PTB, occurs most commonly due to destruction and structural remodelling of the lung parenchyma and its vasculature, other concomitant disease processes may occur in these patients resulting in haemoptysis. This presents a diagnostic challenge to the physician when determining the cause in these patients, as well as, the necessary therapy. As such, despite clearly evident parenchymal lung destruction, multiple other possibilities may still explain haemoptysis.

Up to 40–60% of patients with prior pulmonary TB suffer from airway and parenchymal destruction with fibrosis and cavitation, the hallmark being apical and posterior traction bronchiectasis with upper lobe fibro-cavitation and mediastinal shift toward the diseased lung [8]. Post tuberculous fibro-cavitary disease and bronchiectasis leads to irreversible damage and dilation of the airways and its associated vasculature. The bronchial vasculature becomes hypertrophied, ectatic and exposed. The hyper vascularity, disrupted architectural support and open exposure of these vessels make them easily prone to bleeding and these abnormalities account for the majority of clinically evident haemoptysis in the post-PTB patient [9].

Significant post-primary PTB parenchymal lung damage with cavitation serves as the ideal milieu for fungal colonisation and infection with pathogenic species such as *Aspergillus* spp. Pulmonary aspergillosis may manifest as cavities containing fungal balls referred to as mycetoma's or as chronic cavitary or fibrosing aspergillosis [10]. Occurring in 7–11% of patients after previous PTB, the presence of both a mycetoma on radiological imaging (with CT demonstrating greater diagnostic accuracy than a standard chest x-ray [11]) as well as serum aspergillus antibodies leads to an increase incidence of clinically evident haemoptysis [12]. Erosion of adjacent vasculature and intra-cavitary bleeding serve as the basis for haemoptysis in these patients [6].

Mycobacterial mediated granulomatous inflammation and lymphadenitis may progress to calcification of tissue known as broncholiths. The presentation of post-tuberculous broncholiths may be vague but rarely calcified nodes may disrupt and erode adjacent bronchi and when bronchial vascular networks are involved, haemoptysis may be apparent [8,13]. Although rare, lung cancer and TB may co-exist, with post-primary PTB lung scarring predisposing to the growth of malignancy (scar carcinoma), as such haemoptysis with suspicious lesions on radiological imaging should not be overlooked and require further evaluation [8,13].

Download English Version:

<https://daneshyari.com/en/article/8820174>

Download Persian Version:

<https://daneshyari.com/article/8820174>

[Daneshyari.com](https://daneshyari.com)