



## Case report

## Unicentric castleman disease complicated by paraneoplastic bronchiolitis obliterans and pemphigus



Hassan A. Raza, MD.<sup>a</sup>, Brandon T. Nokes, MD.<sup>c</sup>, Allison C. Rosenthal, DO.<sup>b</sup>,  
Aaron R. Mangold, MD.<sup>d</sup>, Katalin Kelemen, MD.<sup>a</sup>, Clinton E. Jokerst, MD.<sup>e</sup>,  
Rodrigo Cartin-Ceba, MD.,MSc.<sup>a,f,\*</sup>

<sup>a</sup> Division of Pulmonary Medicine, Mayo Clinic Hospital, Phoenix, AZ, USA

<sup>b</sup> Division of Hematology and Medical Oncology, Mayo Clinic Hospital, Phoenix, AZ, USA

<sup>c</sup> Department of Internal Medicine, Mayo Clinic, Scottsdale, AZ, USA

<sup>d</sup> Department of Dermatology, Mayo Clinic, Scottsdale, AZ, USA

<sup>e</sup> Division of Cardiothoracic Radiology, Mayo Clinic, Scottsdale, AZ, USA

<sup>f</sup> Division of Pulmonary Medicine, Mayo Clinic, Scottsdale, AZ, USA

## ARTICLE INFO

## Keywords:

Bronchiolitis

Chest imaging

Leukotriene receptor antagonist

Multisystemic syndrome

Small airway disease

## ABSTRACT

Bronchiolitis obliterans (BO) and paraneoplastic pemphigus are rare and ominous complications of Castleman disease. Collectively, these processes have been reported as part of paraneoplastic autoimmune multiorgan syndrome (PAMS), and they can occur in the setting of various hematologic malignant tumors, carcinoid tumors, and melanoma. Irrespective of the underlying malignancy driving PAMS, the clinical outcomes are uniformly poor, and there are no standard treatment regimens, given the clinical rarity of the syndrome. We describe 2 patients with unicentric Castleman disease complicated by paraneoplastic pemphigus and bronchiolitis obliterans. In addition to primary surgical resection for Castleman disease, we also used therapy from a treatment protocol used for bronchiolitis obliterans resulting from hematopoietic stem cell transplant (HSCT). We were able to treat the patients using intravenous immunoglobulin; rituximab; fluticasone, azithromycin, and montelukast (FAM); and rosuvastatin therapy. One patient demonstrated a favorable response, while the other demonstrated minimal response to this therapy.

## 1. Introduction

Bronchiolitis obliterans and paraneoplastic pemphigus (PNP) are rare, ominous complications of Castleman disease [1], and they have been reported as part of paraneoplastic autoimmune multiorgan syndrome (PAMS) [2]. Irrespective of the underlying malignancy driving PAMS, the clinical outcomes are uniformly poor because of secondary respiratory failure and no standard treatment regimen, given the clinical rarity of the syndrome. We describe 2 patients with PAMS secondary to Castleman disease. In conjunction with treatment for Castleman disease, the patients also received therapy based on a transplant protocol for bronchiolitis obliterans and standard therapy for pemphigus [3–5] (intravenous immunoglobulin [IVIg], rituximab, and rosuvastatin; and fluticasone, azithromycin, and montelukast [FAM therapy]) [3–5].

## 1.1. Case reports

A 39-year-old woman without a smoking history was evaluated for dyspnea on exertion. She had a history of recurrent unicentric Castleman disease complicated by PNP (Fig. 1). Her initial pulmonary function tests (PFTs) in August 2017 showed a forced vital capacity (FVC) of 63% and a forced expiratory volume in the first second of expiration (FEV<sub>1</sub>) of 37% (FEV<sub>1</sub>/FVC ratio, 59%). Computed tomography (CT) showed mild, diffuse bronchial wall thickening and multiple patchy areas of air-trapping consistent with small airway disease (Fig. 2). After initiation of the above treatment regimen, the patient's respiratory symptoms began to improve (Fig. 3). However, shortly thereafter, she discontinued azithromycin and rosuvastatin because of muscle aches, which she said were intolerable. Repeat PFTs in December 2017 showed progressive respiratory failure (FVC, 55%; FEV<sub>1</sub>, 23%; FEV<sub>1</sub>/FVC ratio, 43%). Currently, she is undergoing extracorporeal photopheresis, which has been used to treat patients with

\* Corresponding author. Division of Pulmonary Medicine, 13400 E Shea Blvd, Scottsdale, AZ 85259, USA.

E-mail address: [cartinceba.rodrigo@mayo.edu](mailto:cartinceba.rodrigo@mayo.edu) (R. Cartin-Ceba).

<https://doi.org/10.1016/j.rmcr.2018.08.002>

Received 26 April 2018; Received in revised form 3 August 2018; Accepted 4 August 2018

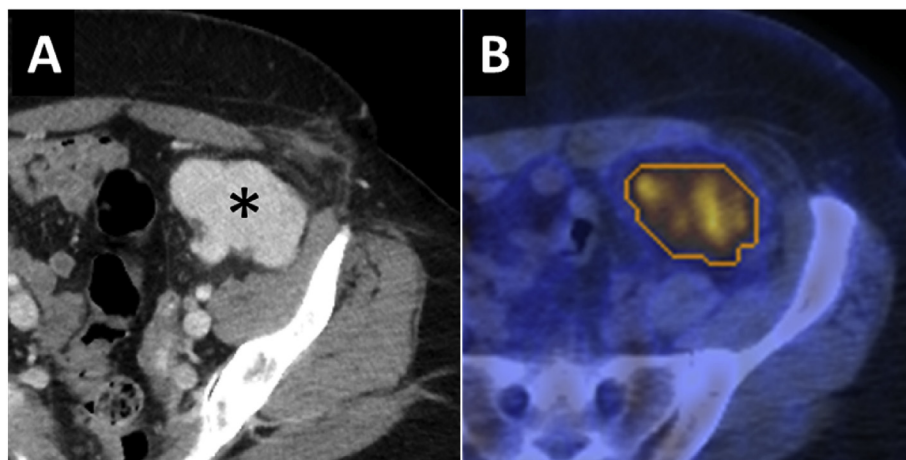
2213-0071/ © 2018 The Authors. Published by Elsevier Ltd. This is an open access article under the CC BY-NC-ND license (<http://creativecommons.org/licenses/by-nc-nd/4.0/>).

### Abbreviations

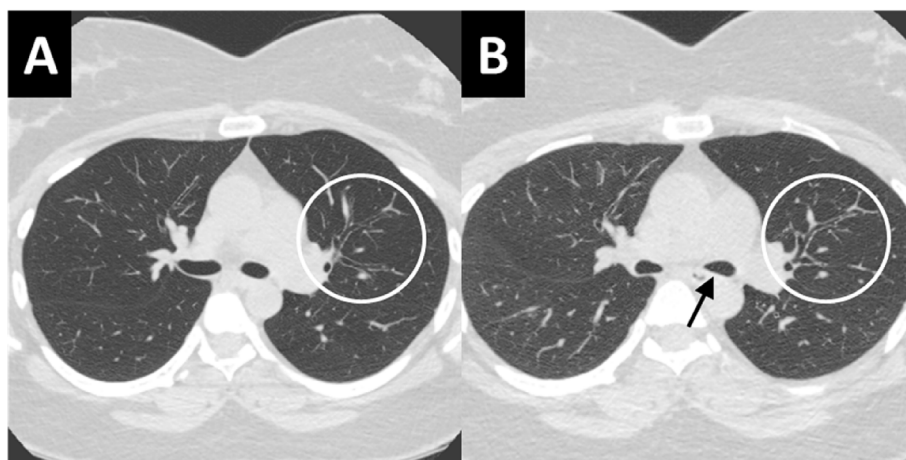
CT	computed tomography
IVIg	intravenous immunoglobulin
FEV <sub>1</sub>	forced expiratory volume in the first second of expiration
FVC	forced vital capacity
HSCT	hematopoietic stem cell transplant
PAMS	paraneoplastic autoimmune multiorgan syndrome
PFT	pulmonary function test
PNP	paraneoplastic pemphigus

## 2. Discussion

Among patients with Castleman disease who succumb to PAMS, the most common cause of mortality is progressive respiratory failure due to bronchiolitis obliterans, for which there are no agreed upon therapeutic options. The mechanism for this respiratory failure, initially proposed by Nousari et al., [6] is related to the unique autoantibodies in PNP. Unlike pemphigus vulgaris, which has autoantibodies to desmogleins 1 and 3 that do not cross-react with respiratory epithelia, various autoantibodies of PNP do react (desmoplakin I, bullous pemphigoid antigen I, desmoplakin II, envoplakin, periplakin, plectin, a previously unidentified 170 kD protein, and  $\alpha$ -2-macroglobulin-like-1) [6–8]. Rat



**Fig. 1.** Axial Image From Contrast-Enhanced Computed Tomography (CT). A, Homogeneously enhancing mass in the left hemipelvis (\*) was consistent with an enlarged lymph node. The degree of enhancement suggested hypervascularity, a characteristic finding in Castleman disease. B, The lesion was fluorodeoxyglucose-avid on subsequent positron emission tomography-CT.



**Fig. 2.** High Resolution Axial Computed Tomography Scan. A, Inspiratory phase. B, Expiratory phase. There is persistent hypoattenuation of the pulmonary parenchyma in the expiratory phase, consistent with diffuse air-trapping. The posterior membrane of the bronchi has collapsed (arrow), confirming the expiratory technique. There is mild, diffuse bronchial wall thickening (circles). These findings are consistent with bronchiolitis obliterans.

bronchiolitis obliterans after hematopoietic stem cell transplant (HSCT).

A 40-year-old man without a smoking history was evaluated for dyspnea on exertion. He also had a history of unicentric Castleman disease complicated by PNP (Fig. 4). Initial pulmonary function tests (PFTs) in November 2016 showed a forced vital capacity (FVC) of 69% and a forced expiratory volume in the first second of expiration (FEV<sub>1</sub>) of 41% (FEV<sub>1</sub>/FVC ratio, 58%). Computed tomography (CT) showed mild, diffuse bronchial wall thickening and multiple patchy areas of air-trapping consistent with small airway disease. After initiation of the above treatment regimen, the patient's respiratory symptoms began to improve (Fig. 5). He remained therapy compliant, and repeat PFTs in October 2017 showed a relatively stable condition (FVC, 88%; FEV<sub>1</sub>, 60%; FEV<sub>1</sub>/FVC ratio, 68%). On most recent follow-up in April 2018, his chest CT showed stability of his respiratory disease (Fig. 6).

bladder antibody testing by immunofluorescence is often used as a surrogate for antibodies to envoplakin, periplakin, and desmoplakins, although desmogleins 1 and 3 (the autoantibody targets in non-PNP) are not present [8].

The mainstay of therapy for paraneoplastic manifestations of Castleman disease is definitive treatment of the neoplasm. However, autoimmune features can persist, especially in recurrent disease [9]. IVIg and rituximab were effective in resolving our patients' mucocutaneous lesions after surgery for Castleman disease recurrences. FAM therapy and rosuvastatin are given to patients for bronchiolitis obliterans after HSCT and for chronic lung rejection because of their anti-inflammatory effects: orally inhaled fluticasone (topical anti-inflammatory effects), azithromycin (impaired interleukin-8 production), and montelukast (blockade of leukotriene production). Our first patient initially improved but then had progressive respiratory decline, which may have resulted from noncompliance to therapy or the natural course

Download English Version:

<https://daneshyari.com/en/article/8820186>

Download Persian Version:

<https://daneshyari.com/article/8820186>

[Daneshyari.com](https://daneshyari.com)