



## Case report

## Massive hemorrhage after inspection bronchoscopy for carcinoid tumor

Mirna Ayache, MD, MPH<sup>a,b,\*</sup>, Christopher Donatelli, MD<sup>a,b</sup>, Kara Roncin, MD<sup>a</sup>,  
Kianoush AnsariGilani, MD<sup>a</sup>, Michael Yang, MD<sup>a</sup>, Jihane Faress, MD<sup>b</sup>, Catalina Teba, MD<sup>a</sup>

<sup>a</sup> Division of Pulmonary, Critical Care and Sleep Medicine, University Hospitals Cleveland Medical Center, USA

<sup>b</sup> Division of Pulmonary, Critical Care and Sleep Medicine, Louis Stokes Veterans Affairs Medical Center, USA

## ARTICLE INFO

## Keywords:

Hemoptysis  
Carcinoid tumor  
Hemorrhage

## ABSTRACT

Carcinoid tumor is a neuroendocrine tumor that can arise in the bronchial tree and can be hypervascular. Here we describe a case of bronchial carcinoid tumor in a 34-year-old previously healthy male who presented with hemoptysis and right lung mass. Inspection bronchoscopy revealed bronchus intermedius endobronchial lesion and was complicated by urgent intubation and placement of endobronchial blocker for massive hemorrhage. Subsequent angiography with embolization of the bronchial artery supplying the mass resulted in control of bleeding. While massive hemorrhage has been described with biopsy of bronchial carcinoid tumor, this case suggests that careful planning for inspection bronchoscopy is needed when carcinoid tumor is suspected.

## 1. Introduction

Carcinoid tumor is a neuroendocrine tumor that can arise from various body sites including gastrointestinal tract and bronchopulmonary system [1–3]. Carcinoid tumors of the lung constitute 10–25% of total carcinoid tumors [1–3] and 0.5–2% of all lung tumors [4,5]. Hemoptysis is one of the most common presenting symptoms in carcinoid tumor [5–7] which most commonly arises in the proximal airways and can be hypervascular. We describe a case of 34-year old previously healthy male who presented with hemoptysis and underwent bronchoscopy for inspection. However, he developed massive hemorrhage leading to intubation and abortion of the procedure with subsequent angiographic embolization that was successful in controlling the bleeding. This case sheds light on the importance of careful planning for bronchoscopy when carcinoid tumor is suspected.

## 2. Case presentation

A 34-year old previously healthy Caucasian male presented with hemoptysis of 3-day duration. The patient quantified his hemoptysis as an ounce of clotted blood twice daily. He denied any associated cough, shortness of breath or wheezing. He stated that he had a brief episode of hemoptysis five months prior to presentation, for which he was treated as pneumonia by his primary care physician with subsequent resolution of hemoptysis. A thorough review of systems was done and was only positive for fatigue over the 4–5 days prior to presentation. He denied

fevers, chills, weight loss, night sweats, lightheadedness, chest pain, nausea, vomiting, and diarrhea. There was no history of recent travel or trauma. Past medical and surgical histories were negative. Family history was positive for cervical cancer in mother and negative for lung disease. He smoked half a pack a day for 14 years, used marijuana daily, reported occasional alcohol intake, but no other illicit drugs.

On examination, the patient did not appear to be ill or in distress. Initial vital signs were: temperature 36.8 °C, blood pressure 109/64 mmHg, heart rate 51 beats/min, respiratory rate 18 breaths/min, and pulse oximetry 97% on room air. Examination of the neck was negative for lymphadenopathy and thyroid enlargement. Lungs were clear with good air entry and breath sounds bilaterally, no wheezing or crackles. Cardiovascular examination revealed regular rate and rhythm without murmurs. The abdomen was soft, non-tender with normal bowel sounds and no hepatosplenomegaly. Extremities were warm without clubbing, cyanosis or edema. Neurological exam was intact.

Laboratory tests were normal including complete blood count, renal function panel, liver enzymes and coagulation profile. Chest radiograph showed right middle lobe opacity (Fig. 1). Unenhanced computed tomography (CT) of the chest showed endobronchial mass of the bronchus intermedius containing dystrophic calcifications (Fig. 2). Patient underwent inspection bronchoscopy which revealed bright red blood originating from large endobronchial tumor obstructing the bronchus intermedius (Fig. 3). Due to massive hemorrhage, the patient was intubated for airway protection, an endobronchial blocker was placed into the right mainstem bronchus, and bronchoscopy was

Abbreviations: CT, computed tomography

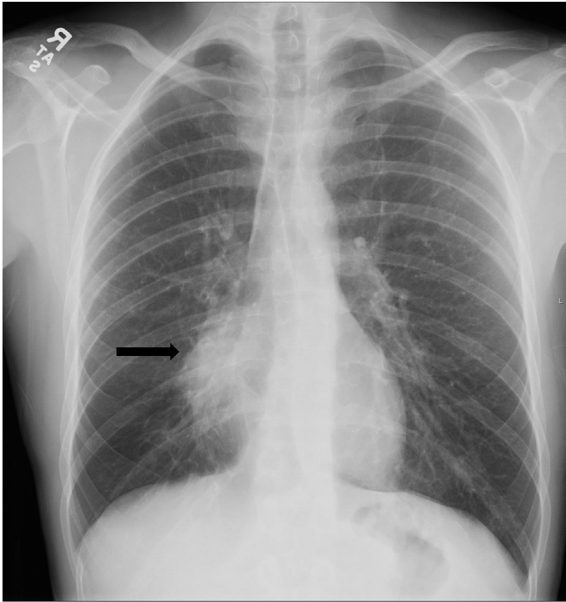
\* Corresponding author. 2355 Botanica Lane, Pepper Pike, OH, 44124, USA.

E-mail address: [ayachemirna@hotmail.com](mailto:ayachemirna@hotmail.com) (M. Ayache).

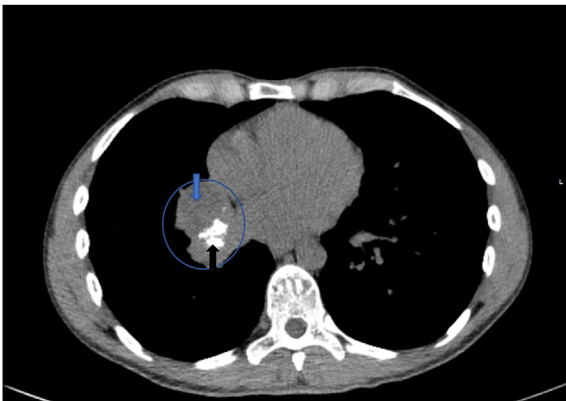
<https://doi.org/10.1016/j.rmcr.2018.05.002>

Received 2 April 2018; Received in revised form 30 April 2018; Accepted 2 May 2018

2213-0071/ © 2018 The Authors. Published by Elsevier Ltd. This is an open access article under the CC BY-NC-ND license (<http://creativecommons.org/licenses/by-nc-nd/4.0/>).



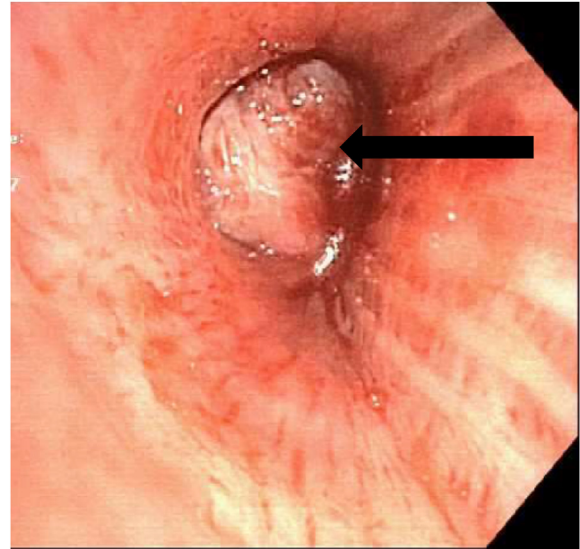
**Fig. 1.** Posteroanterior radiograph of the chest showing a mass like opacity in the medial aspect of the right lower lung (arrow), silhouetting the right heart border, likely located in the medial segment of the right middle lobe.



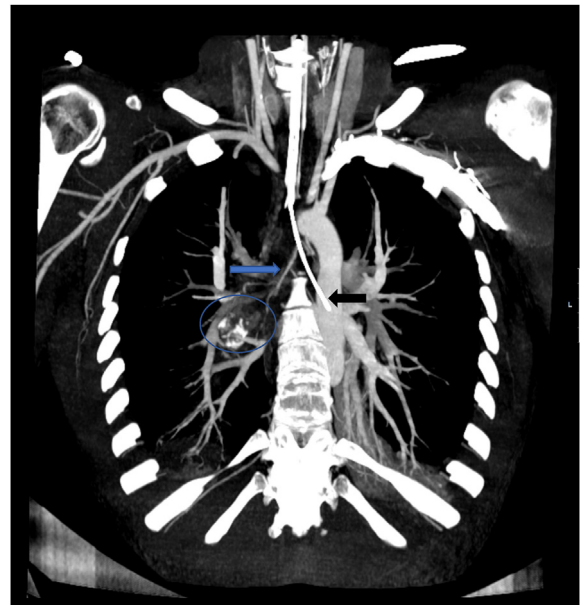**Fig. 2.** Noncontrast computed tomography of the chest at the level of bronchus intermedius, showing a mass (circle) with large dystrophic calcification (black arrow) and an area of cystic appearing lesion more anteriorly (blue arrow), which is likely a bronchocele associated with the mass.

aborted. Estimated blood loss was 200 ml and bleeding was persistent the entire procedure time (more than one hour) even after the instillation of 14 ml of Epinephrine (1:10,000) via bronchoscope. CT chest angiography showed large mass extending from the region of the right mainstem bronchus. The mass appeared to be supplied by a bronchial artery at the level of T4 (Fig. 4). Right bronchial arteriogram showed a right bronchial artery perfusion to a hypervascular right hilar mass corresponding with the hemorrhagic mass shown on CT chest and bronchoscopy (Fig. 5). The right bronchial artery supplying the mass was subsequently embolized. The patient's hemoptysis improved and he went for general anesthesia bronchoscopy with endobronchial biopsies. He later underwent posterolateral thoracotomy and bi-lobectomy (right middle and lower lobes) for mass removal.

Macroscopic examination of the right middle and lower lobes revealed a tumor protruding into the mainstem bronchus, abutting the bronchial margin. On cross section, the mainstem bronchus was expanded by a poorly demarcated, irregular, yellow-white, firm mass that measured 3.5 cm in greatest dimension (Fig. 6). Microscopic evaluation revealed a distinct population of small, polygonal neoplastic cells with



**Fig. 3.** Right mainstem bronchus-endobronchial large, smooth, friable mass occluding bronchus intermedius.



**Fig. 4.** Reconstructed contrast enhanced CT of the chest in oblique coronal Maximal Intensity Projection (MIP) at the area of the tumor, showing the mass in the right bronchus intermedius with dystrophic calcification (circle). The bronchial artery supplying the mass is visible (blue arrow). Black arrow points to bronchial blocker placed for massive hemorrhage and displaced into the left bronchial tree.

granular, pale eosinophilic cytoplasm and open, “salt and pepper” chromatin within rounded nuclei. Mitoses were infrequent (Fig. 7) and there were regions of squamous and osseous metaplasia observed within the mass. The histopathological findings were consistent with typical carcinoid tumor.

### 3. Discussion

This case depicts a young previously healthy male presenting with hemoptysis without any other symptoms. Unenhanced CT of the chest showed endobronchial mass of the bronchus intermedius with no lymph node enlargement. While the differential diagnosis include hamartomas, benign mesenchymal tumors and other lung cancers, the

Download English Version:

<https://daneshyari.com/en/article/8820243>

Download Persian Version:

<https://daneshyari.com/article/8820243>

[Daneshyari.com](https://daneshyari.com)