Clinical Imaging 50 (2018) 20–30

Contents lists available at ScienceDirect

Clinical Imaging

journal homepage: www.elsevier.com/locate/clinimag

Analysis of the risk factors for anterior cruciate ligament injury: an investigation of structural tendencies

Volkan Kızılgöz[a,*], Ali Kemal Sivrioğlu[b], Gökhan Ragıp Ulusoy[c], Hasan Aydın[d], Sunay Sibel Karayol[a], Utku Menderes[e]

[a] Kafkas University, Faculty of Medicine, Department of Radiology, Kars, Turkey
[b] Okmeydanı Training and Research Hospital, Department of Radiology, Istanbul, Turkey
[c] Kafkas University, Faculty of Medicine, Department of Orthopaedics, Kars, Turkey
[d] Abdurrahman Yurtaslan Ankara Oncology Research and Training Hospital, Department of Radiology, Ankara, Turkey
[e] Eskişehir State Hospital, Department of Radiology, Eskişehir, Turkey

ARTICLE INFO

Keywords:
Anterior cruciate ligament
Knee injury
Risk factors
Knee morphology
Magnetic resonance imaging

ABSTRACT

Objective: The aim of this study was to determine the most important anatomical risk factors for injury of the anterior cruciate ligament (ACL) of the knee.

Materials and methods: After study approval by our institutional ethics committee, 3 radiologists reinterpreted the preoperative magnetic resonance (MR) images of 86 patients who had undergone surgery for ACL rupture. The measurements were compared with those for a control group comprising 109 patients with intact ACL who had undergone MR examinations for other reasons, such as meniscal injuries or Baker cyst ruptures. Interobserver differences were calculated after measurement of the notch width (NW), NW index (NWI), medial condyle width (MCW), lateral condyle width (LCW), MCW/LCW ratios, alpha (α) angle, NW angle, quadriceps angle (Q angle), posterior medial tibial slope (MTS), posterior lateral tibial slope, coronal tibial slope, and depth of medial tibial plateau for each group. The relationships between these parameters and ACL injury were studied by performing logistic regression and receiver operating characteristic curve analyses in comparison with those in the control group.

Results: We found that there were significant differences in the anatomical parameters of the NW, MCW, NWI, α angle, and MTS between the ACL injured and noninjured groups ($p < 0.05$). There were also significant differences in the bicondylar width, α angle, Q angle, and MTS between the patients with ACL rupture because of noncontact injuries and the control group ($p < 0.05$). The NWI and MTS had the highest predicted relative risk for both the male and female groups.

Conclusion: We found that the NW, NWI, and MTS were the most important parameters in risk assessment of ACL injuries.

1. Introduction

The anterior cruciate ligament (ACL) is a major stabilizer of the knee joint and is the knee ligament most often involved in injuries and related functional instability [1–3]. Researchers have studied the structural bony morphology, functional anatomy of the knee, and biomechanics of ligament injury to understand the mechanism of ACL injuries. Some researchers have emphasized the relationship between ACL injury and the anatomical morphology of the bones.

The notch width (NW) and NW index (NWI) have been studied to analyze the relationship between the bony morphology and ACL injuries in an attempt to explain why ACL rupture occurs. Souryal et al. described a method to measure the intercondylar NW and NWI. They used plain tunnel-view radiographs and measured the NWI by determining the ratio of the femoral NW to the femoral bicondylar width (BCW). In their research, the NWI was statistically smaller in patients who had suffered from bilateral ACL than in patients without ACL injuries [4–5]. Sex-related variations in the femoral notch morphometry have also been studied to determine if they can explain the increased risk of ACL tears in females; however, biological sex alone has not been correlated with femoral notch stenosis according to some researchers [4–7]. ACL morphology has been investigated as a possible risk factor for ACL injuries. Some researchers have found a correlation between the ACL ligament width and ACL rupture [8,9]. A high angle between

* Corresponding author.
E-mail address: vkizilgoz@kafkas.edu.tr (V. Kızılgöz).

https://doi.org/10.1016/j.clinimag.2017.12.004
Received 15 May 2017; Received in revised form 27 October 2017; Accepted 8 December 2017
0899-7071/ © 2017 Elsevier Inc. All rights reserved.

the femoral longitudinal axis and Blumensaat line (BL), known as the alpha (α) angle, has been thought to be a possible risk factor of ACL rupture [10] as has the NW angle (NWA) [11].

Some studies have suggested that the morphology of the tibial plateau directly influences the biomechanics of the tibiofemoral joint. Tibial plateau geometry is known to affect the translation of force involved with rotation of the tibia internally and the end of knee extension externally, functions that are known as the screw-home mechanism, and to affect the location of the instantaneous rotation center and the strain biomechanics of the ACL [12–14]. The posterior medial tibial slope (MTS), posterior lateral tibial slope (LTS), and depth of the medial tibial plateau (DMP) have been mentioned as potential factors related to ACL injuries [15–20]. The quadriceps angle (Q angle), which is defined as the angle formed by a line from the anterior superior iliac spine to the center of the patella and a line from the center of the patella to the tibial tuberosity, has been thought to be another possible risk factor of ACL rupture [21–24].

The aim of the present study was to determine the most important risk factors for injury of the ACL of the knee. The ACL is known to significantly contribute to restraint of internal tibial rotation and anterior tibial translation [2,25]. We also investigated knee rotation and anterior tibial translation (or translocation), which have been shown to differ between ACL ruptured and nonruptured individuals because of altered knee kinematics of the ACL-deficient knees.

2. Materials and methods

2.1. Patients

This retrospective case–control study was approved by the Institutional Review Board of Kafkas University. Between January 2015 and March 2017, 86 patients (mean age, 28 ± 6.5 yr; range, 20–50 yr) who had been examined for ACL injury by magnetic resonance imaging (MRI) in the hospitals of Kafkas University and Atatürk University were included in this study.

There were 54 male (mean age, 29 ± 6.4 yr; range, 20–46 yr) and 32 female (mean age, 27 ± 6.7 yr; range, 20–50 yr) patients. Three radiologists (a musculoskeletal radiologist with 11 yr of experience and 2 general radiologists with 15 and 17 yr of experience, respectively) reinterpreted the MR images. The median time interval between the injury and the MRI scan was 21.5 days (minimum, 1 day; maximum, 122 days) for the patients with ACL rupture. The control group consisted of 109 patients (mean age, 29 ± 5.1 yr; range, 18–39 yr). There were 63 males (mean age, 29 ± 5 yr; range, 19–39 yr) and 46 females (mean age, 29 ± 5.3 yr; range, 18–38 yr). The patients in the control group were chosen from patients who were examined by knee MRI and had no ACL injuries. Patients who had knee pathologies other than ACL rupture, such as isolated meniscal and chondral injuries, millimetric geode formations, and Baker's cyst rupture, were also included in the control group. Three patients with severe osteoarthritis and 2 patients with a family history of genetic musculoskeletal disorders were excluded from the study. The study group (ACL injury group) was divided into 2 subgroups: (1) patients with contact trauma history, fracture, or contusional bone marrow edema were grouped as contact ACL injuries and (2) patients with noncontact trauma were grouped as nontraumatic ACL injuries. The nontraumatic ACL group (n = 85) consisted of 38 females and 47 males. Only the patients > 18 and < 50 yr old were included in the study to avoid the morphological changes of osteoarthritis, which would affect the results of the morphological measurements. Each patient was examined by 3 radiologists separately. The researchers measured NW, NWI, medial condyle width (MCW), lateral condyle width (LCW), BCW, MCW/LCW ratios, alpha (α) angle, NWA, Q angle, MTS, LTS, coronal tibial slope (CTS), and DMP for each patient in the study and control groups. Tibial rotation was calculated by measuring the femorotibial angle (FTA). Interobserver differences were calculated after measurements were made by the 3 radiologists for the control group and patient group.

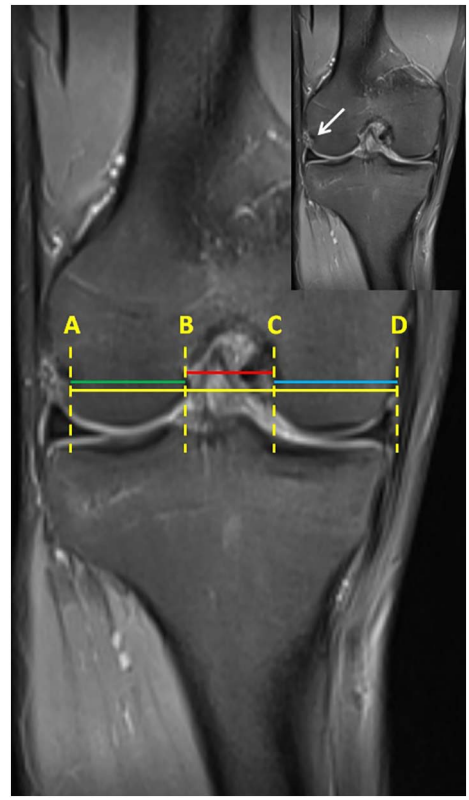

Fig. 1. The medial condyle width (MCW) (blue line), lateral condyle width (LCW) (green line), notch width (NW) (red line), and bicondylar width (BCW) (yellow line) measurements in the coronal section in which the popliteal groove (indicated in the same section in the upper left side by a white arrow) can be seen. (For interpretation of the references to color in this figure legend, the reader is referred to the web version of this article.)

2.2. Measurements

All measurements were made by using the digital Picture Archiving and Communication System provided by Kafkas University. The NW, MCW, LCW, and BCW of each patient were measured in coronal proton density-weighted (PDW) images. BCW was measured first in the coronal plane, where the popliteal groove of the lateral femoral condyle was seen. On the same line, the most interior margins of the femoral condyles were identified to measure the LCW and MCW. The distance between these margins represented the NW. The MCW/LCW ratio was calculated by dividing the MCW by the LCW. The NWI was calculated by dividing the NW by the BCW [Fig. 1].

The longitudinal axis of the femur (LAF) in the sagittal plane is defined by a line between 2 points that represent the midpoints of the anterior–posterior width of the tibia. These width measurements were made approximately 4 to 5 cm apart and as distally in the sagittal image as possible. The line that passes through these 2 midpoints of the femoral width represented the sagittal LAF in the sagittal plane. The angle between the LAF and BL is the alpha (α) angle and was measured on sagittal T1-weighted (T1 W) images. The sagittal section in which the entire BL was seen was chosen for the α angle measurement [Fig. 2].

Posterior MTS and LTS angles and DMP measurements were made on the sagittal T1 W images. For posterior slope measurements, the sagittal plane that passed closest to the centroid of the tibial plateau was identified with the aid of axial planes that passed through the level of the plateau. The longitudinal axis of the tibia (LAT) was defined by a line through 2 points that represented the midpoints of the anterior–posterior width of the tibia. These width measurements were made

Download English Version:

https://daneshyari.com/en/article/8821437

Download Persian Version:

https://daneshyari.com/article/8821437

Daneshyari.com