European Journal of Radiology 98 (2018) 207–213

Contents lists available at ScienceDirect

European Journal of Radiology

journal homepage: www.elsevier.com/locate/ejrad

Research article

Computer-aided diagnosis of contrast-enhanced spectral mammography: A feasibility study

Bhavika K. Patel, MD[a,*], Sara Ranjbar[b], Teresa Wu, PhD[c], Barbara A. Pockaj, MD[d], Jing Li, PhD[c], Nan Zhang[e], Mark Lobbes, MD, PhD[f], Bin Zhang, PhD[g], J. Ross Mitchell, PhD[b]

[a] Mayo Clinic, Scottsdale, Department of Radiology
[b] Mayo Clinic, Scottsdale, Dept. of Research
[c] Arizona State University, Phoenix, Department of Computer Science
[d] Mayo Clinic, Scottsdale, Department of General Surgery
[e] Mayo Clinic, Scottsdale, Department of Biostatistics
[f] Maastricht University Medical Center, Maastricht, Netherlands, Department of Radiology
[g] University of Oklahoma, Norman, School of Electrical and Computer Engineering

ARTICLE INFO

Keywords:
Breast cancer
Computer-aided diagnosis
Contrast-enhanced digital mammography
Contrast-enhanced spectral mammography
Quantitative image analysis

ABSTRACT

Objective: To evaluate whether the use of a computer-aided diagnosis–contrast-enhanced spectral mammography (CAD-CESM) tool can further increase the diagnostic performance of CESM compared with that of experienced radiologists.

Materials and methods: This IRB-approved retrospective study analyzed 50 lesions described on CESM from August 2014 to December 2015. Histopathologic analyses, used as the criterion standard, revealed 24 benign and 26 malignant lesions. An expert breast radiologist manually outlined lesion boundaries on the different views. A set of morphologic and textural features were then extracted from the low-energy and recombined images. Machine-learning algorithms with feature selection were used along with statistical analysis to reduce, select, and combine features. Selected features were then used to construct a predictive model using a support vector machine (SVM) classification method in a leave-one-out–cross-validation approach. The classification performance was compared against the diagnostic predictions of 2 breast radiologists with access to the same CESM cases.

Results: Based on the SVM classification, CAD-CESM correctly identified 45 of 50 lesions in the cohort, resulting in an overall accuracy of 90%. The detection rate for the malignant group was 88% (3 false-negative cases) and 92% for the benign group (2 false-positive cases). Compared with the model, radiologist 1 had an overall accuracy of 78% and a detection rate of 92% (2 false-negative cases) for the malignant group and 62% (10 false-positive cases) for the benign group. Radiologist 2 had an overall accuracy of 86% and a detection rate of 100% for the malignant group and 71% (8 false-positive cases) for the benign group.

Conclusions: The results of our feasibility study suggest that a CAD-CESM tool can provide complementary information to radiologists, mainly by reducing the number of false-positive findings.

1. Introduction

Dual-energy contrast-enhanced spectral mammography (DE-CESM or CESM) (also called dual-energy contrast-enhanced digital mammography [DE-CEDM]) improves the accuracy of breast cancer diagnosis [6]. CESM generates a low-energy mammographic image along with a recombined contrast-enhanced image, reflecting contrast accumulation within a breast (Fig. 1). Breast regions with increased or leaky vasculature, two common characteristics of neoplasms, can be identified using intravenously administered, iodinated-contrast material, thus

Abbreviations: BIRADS, Breast Imaging Reporting and Data Systems; CAD, computer aided diagnosis; CC, craniocaudal; CEDM, contrast-enhanced digital mammography; CESM, contrast-enhanced spectral mammography; DICOM, Digital Imaging and Communications in Medicine; DOST, discrete orthonormal Stockwell transform; DE, dual-energy; FFDM, full-field digital mammography; GFB, Gabor filter bank; GLCM, gray level co-occurrence matrices; IRB, institutional review board; LBP, local binary patterns; LoGHist, Laplacian-of-Gaussian histogram; LOOCV, leave-one-out–cross-validation; MLO, mediolateral oblique; PASH, pseudoangiomatous stromal hyperplasia; PC, principal component; PCA, principal component analysis; ROC, receiver operating characteristic; ROI, region of interest; SFFS, sequential forward feature selection; SVM, support vector machine

* Corresponding author at: Department of Radiology, MayoClinic Hospital, 5777 E Mayo Blvd, Phoenix, AZ, 85054, United States.
E-mail address: patel.bhavika@mayo.edu (B.K. Patel).

https://doi.org/10.1016/j.ejrad.2017.11.024
Received 19 May 2017; Received in revised form 19 August 2017; Accepted 30 November 2017

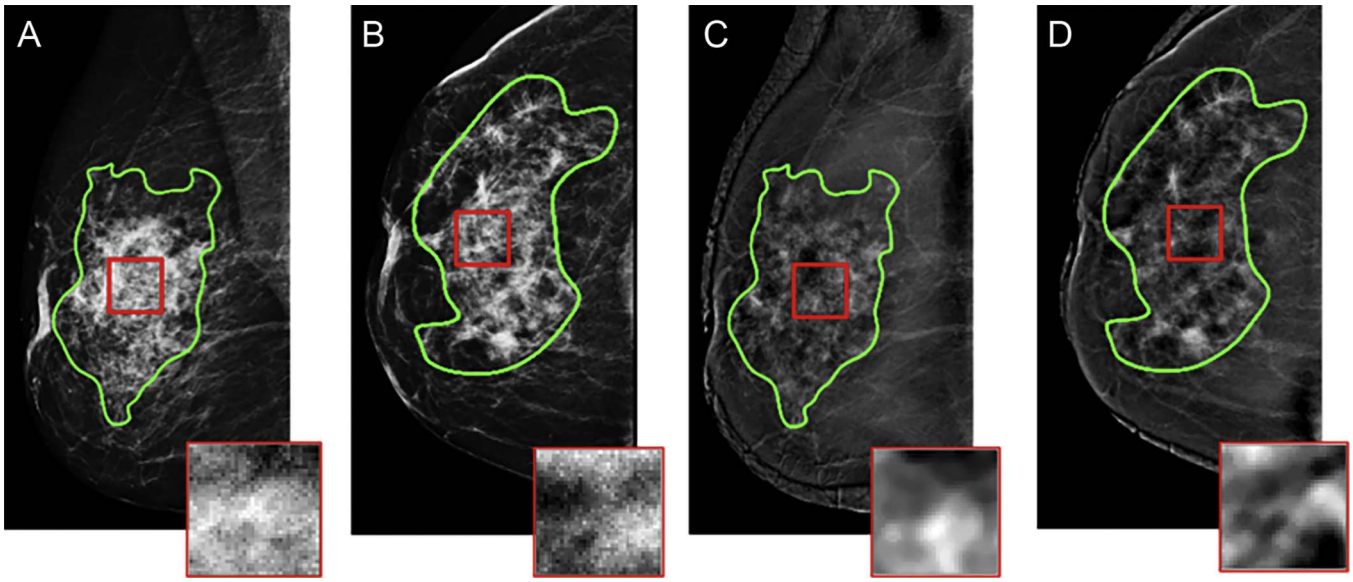

Fig. 1. Regions of interest for shape and texture analysis. Sixty-one-year-old woman with a malignant-appearing lesion in the right breast. A, Low-energy, mediolateral oblique view. B, Low-energy, craniocaudal view. C, Recombined image, mediolateral oblique view. D, Recombined image, craniocaudal view. The regions of interest are identical for the low-energy and contrast-enhanced images on each view. Shape features are extracted from the contours (green), and texture features are extracted from a rectangular area inside each contour (red). (For interpretation of the references to colour in this figure legend, the reader is referred to the web version of this article.)

improving lesion detection and characterization [7]. Although studies have shown that CESM is superior to FFDM, specificity is estimated to be 58% to 70% [8], leaving room for further improvement in diagnostic accuracy, for example, by applying quantitative image analyses.

Quantitative image analysis is a topic of active research that includes well-established applications like computer-aided diagnosis (CAD) algorithms. CAD algorithms, when coupled with traditional mammography, have shown promise for identifying suspicious breast lesions [9]. These algorithms have evolved and are improved by leveraging large datasets generated from high-throughput sequencing experiments [10]. However, no studies thus far have evaluated the use of CAD algorithms in CESM.

Recently, there has been some interest in the use of texture features to distinguish benign and malignant lesions on magnetic resonance [11] and mammographic imaging [12]. We hypothesized that lesion texture and shape features can often capture often-missed information regarding the characteristics of a tumor and can provide details that have prognostic or diagnostic value [13]. These texture features describe intensity distributions within the lesion and capture spatial and spectral frequency patterns, as well as characterize the relationships between different intensity levels within the lesion. Some of these features might not be visually apparent to the radiologists and therefore have the potential to complement the diagnostic skillset of radiologists. The purpose of our current study was to evaluate a prototype CAD-CESM tool, using texture and morphologic analysis to differentiate benign and malignant breast lesions.

2. Material and methods

2.1. Study population

The study was considered exempt by the Institutional Review Board (IRB). We retrospectively reviewed CESM examinations on a Selenia mammography system (Hologic, Bedford, MA). The examinations were performed between August 1, 2014, and December 31, 2015. Informed consent was obtained from all patients having a BI-RADS (Breast Imaging Reporting and Data Systems) [14] classification of 4 and 5 in a preexisting IRB-approved study to determine if CESM could lower the false-positive biopsy rates in mammography. As part of the aforementioned study, the radiologist counseled patients on the risks and benefits of biopsy and CESM. CESM was offered as an adjunct, not as an alternative to the recommended breast biopsy. The patient was informed that CESM might increase or decrease the level of suspicion of a lesion and might show additional suspicious areas. CESM was performed before the biopsy, typically on the diagnostic examination day or on the day of the biopsy.

The cohort for the current study included examinations that met the following criteria: (1) a diagnostic mammogram that received a BI-RADS rating of 4 or 5 and (2) studies that corresponded with available pathologic results from a surgical or image-guided biopsy. We limited the cohort to BI-RADS 4 and 5 lesions because the analysis required the criterion standard of lesion pathology. Fifty studies were identified that met the above inclusion criteria, comprising 24 benign and 26 malignant, biopsy-proven lesions (Table 1). We analyzed 1 lesion per patient. If a patient had multiple enhancing lesions, the annotating radiologist

Table 1
Characteristics of the Study Population.

Biopsied Lesions (N = 50)			
Benign Lesions (n = 24)	No. (%)	Malignant Lesions (n = 26)	No. (%)
Fibroadenoma	6 (25)	Ductal carcinoma in situ	6 (23)
Fibrosis	5 (21)	Grade 1	1 (4)
Intraductal papilloma	2 (8)	Grade 2	1 (4)
PASH	1 (4)	Grade 3	4 (15)
Fat necrosis	1 (4)	Invasive ductal carcinoma	17 (65)
Sclerotic intraductal papilloma	1 (4)	Grade 1	5 (19)
Cyst	1 (4)	Grade 2	6 (23)
Nonproliferative breast changes	1 (4)	Grade 3	6 (23)
Fibroadenoma and phyllodes tumor	1 (4)	Invasive lobular carcinoma	3 (12)
Lymph node	1 (4)	Grade 1	1 (4)
Cellular fibroadenoma	1 (4)	Grade 2	2 (8)
Stromal fibrosis	1 (4)		
Proliferative fibrocystic changes with radial scars	1 (4)		
Ductal proliferation with papillary features and apocrine metaplasia	1 (4)		

Abbreviation: PASH, pseudoangiomatous stromal hyperplasia.