

Foreign-body granuloma mimicking post-chemotherapy residual seminoma: A case of true-negative findings using diffusion-weighted whole-body magnetic resonance imaging with background suppression

Hideki Takeshita^{a,*}, Satoru Kawakami^a, Taro Takahara^b, Kojiro Tachibana^a, Shunsuke Hiranuma^a, Hironori Sugiyama^a, Makoto Kagawa^a, Akihiro Yano^a, Yohei Okada^a, Makoto Morozumi^a

^a Department of Urology, Saitama Medical Center, Saitama Medical University, 1981 Kamoda, Kawagoe, Saitama, 350-8550, Japan

^b Department of Biomedical Engineering, Tokai University School of Engineering, 4-1-1 Kitakaname, Hiratsuka, Kanagawa, 259-1292, Japan

ARTICLE INFO

Keywords:

Whole-body imaging
Diffusion magnetic resonance imaging
Seminoma
Chemotherapy
Positron-emission tomography

ABSTRACT

Diffusion-weighted whole-body magnetic resonance imaging with background suppression (DWIBS) is increasingly used in cancer imaging. However, little is known about its usefulness in the management of metastatic seminoma, in which evaluation of the viability of postchemotherapy residual nodules is pivotal. To date, 2–18fluoro-deoxy-D-glucose positron emission tomography (FDG-PET) has been recommended for post-chemotherapeutic assessment. We describe a case of metastatic seminoma in a 27-year-old man in which the viability of post-chemotherapy residual nodules tested false-positive on FDG-PET, but true-negative on DWIBS. DWIBS may be a good alternative technique to evaluate post-chemotherapy seminoma, although further studies are required to determine its usefulness.

1. Introduction

In the management of metastatic seminoma, the evaluation of the viability of post-chemotherapy residual nodules is pivotal. To date, the use of 2–18 fluoro-deoxy-D-glucose positron emission tomography (FDG-PET) has been recommended for that purpose [1–3]. However, there are several problems with FDG-PET evaluations of cancer viability after chemotherapy. One is that false-positive FDG-PET results are not uncommon [4], and another is that an interval of at least 6 weeks after the completion of chemotherapy is recommended to avoid acute false-positive results [1,2].

Diffusion-weighted whole-body magnetic resonance imaging with background suppression (DWIBS) is increasingly used in cancer imaging [5,6]. This new technique provides a whole-body functional image similar to FDG-PET, but little is known about its usefulness in the management of metastatic seminoma. Here we describe a case of metastatic seminoma in a 27-year-old man in which the post-chemotherapy residual nodules tested false-positive on FDG-PET but true-negative on DWIBS, 2 weeks after the completion of chemotherapy.

2. Case report

A 27-year-old man was referred to us for a right side intrascrotal mass the size of an infant's head with swelling of the right inguinal region. Imaging studies revealed a right testicular tumor with left supraclavicular, mediastinal, and retroperitoneal lymph node swelling (Fig. 1). Elevated serum levels of tumor markers included human chorionic gonadotropin (hCG), 11927 mU/mL (normal range [NR], < 0.5 mU/mL); hCG-β, 63.6 ng/mL (NR, < 0.1 ng/mL); and lactate dehydrogenase (LDH), 5710 U/L (NR, 115–280 U/L). Serum α-fetoprotein was within the NR (< 10 ng/mL). A right orchiectomy was performed and pathological examination indicated a testicular seminoma with a positive surgical margin at the spermatic cord stump. His testicular cancer was finally staged as pT3N2M1aS2, stage IIIB. Three cycles of combination chemotherapy with bleomycin, etoposide, and cisplatin were introduced and FDG-PET was performed immediately after the completion of the chemotherapy to explore residual viable cancer. The FDG-PET showed positive nodules in the right inguinal region near the proximal stump of the right spermatic cord (Fig. 2). Considering inadequate treatment efficacy, a single cycle of etoposide and cisplatin chemotherapy was added. FDG-PET was repeated two weeks after completion of the final chemotherapy, but the positive nodules in the

* Corresponding author.

E-mail address: takeuro@saitama-med.ac.jp (H. Takeshita).

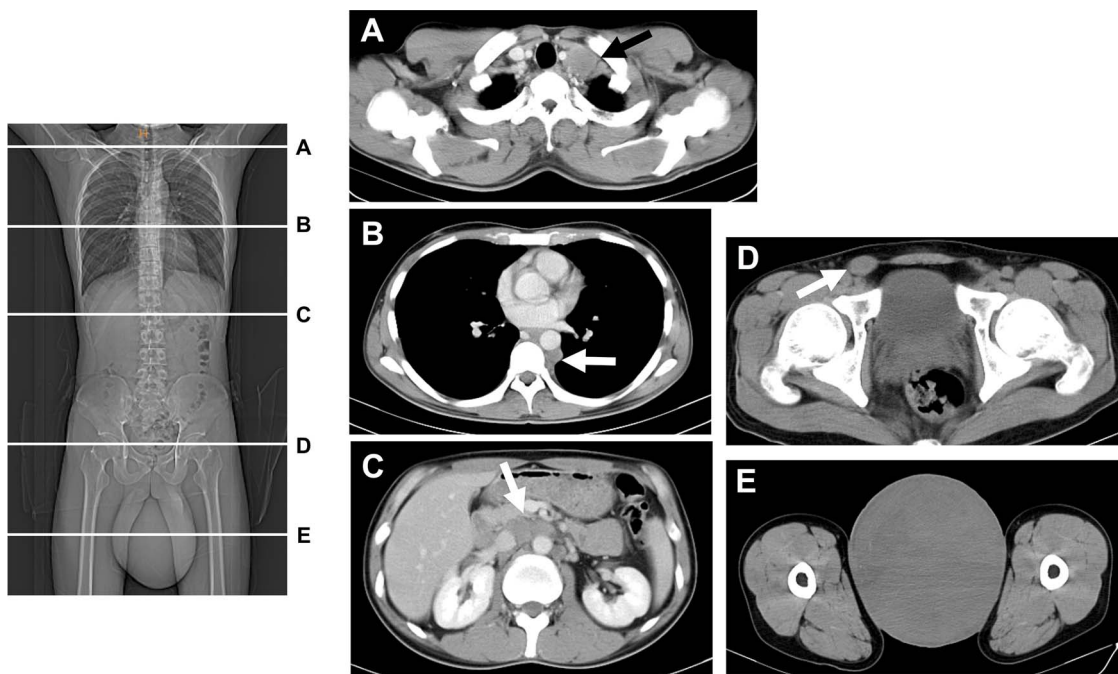


Fig. 1. Computed tomography scan at the first visit. (A, B, C) Contrast-enhanced images of lymph node metastases. (D, E) Primary tumor of the right testis and spermatic cord. Only plain images were available. The arrows indicate the tumors.

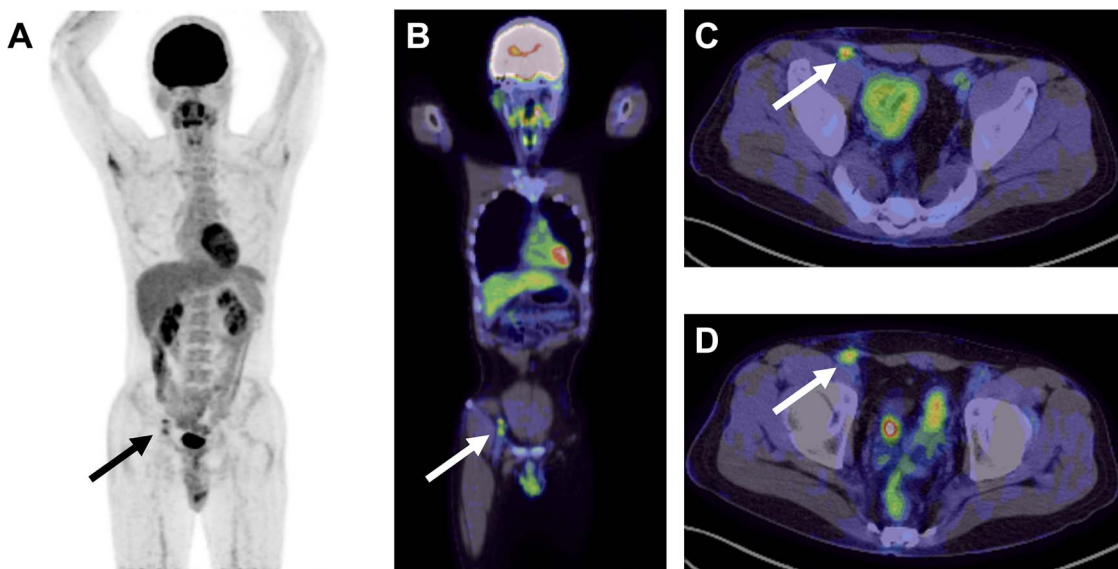


Fig. 2. Post-chemotherapy 2-18fluoro-deoxy-D-glucose positron emission tomography (FDG-PET) images. (A) Maximum intensity projection (MIP) image, (B) MIP-fused image, and (C, D) fused PET-CT images. The arrows show two 10-mm right inguinal FDG-positive nodules.

right inguinal region did not change. However, DWIBS performed at the same time revealed no residual disease in his body (Fig. 3). Resection of the right inguinal nodules was performed because the presence of viable post-chemotherapy seminoma could not be disproved. Pathological examination of the specimen revealed granulomas caused by silk surgical threads, without viable cancer (Fig. 4). The patient is doing well and there has been no recurrence for a year.

3. Discussion

Several guidelines recommend FDG-PET for the evaluation of post-chemotherapy residual nodules in seminoma [1,2]. De Santis et al. reported a high diagnostic accuracy of 100% specificity, 80% sensitivity, 100% positive predictive value, and 96% negative predictive value

when using FDG-PET to detect viable post-chemotherapy seminoma [3]. However, Hinz et al. indicated false-positive FDG-PET results of 45% (9 of 20), which are not uncommon [4]. They revealed that histopathological results of FDG-PET false-positive tumors were sarcoidosis in two cases, inflammation in one, and fibrosis/necrosis in six. According to the guidelines [1,2], an interval of at least 6 weeks after the last chemotherapy cycle is recommended to avoid the occasional false-positivity caused by an acute chemotherapeutic reaction when performing FDG-PET. This might result in a substantial delay in additional treatment. Although FDG-PET is a useful functional imaging modality for the evaluation of metastatic seminoma, there is a limitation to its utility.

DWIBS is a new whole-body diffusion-weighted imaging technique under free breathing that was first reported by Takahara et al. [5]. It

Download English Version:

<https://daneshyari.com/en/article/8822877>

Download Persian Version:

<https://daneshyari.com/article/8822877>

[Daneshyari.com](https://daneshyari.com)