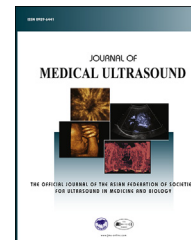


Chinese Taipei Society of
Ultrasound in Medicine

Available online at www.sciencedirect.com

ScienceDirect

journal homepage: www.jmu-online.com



REVIEW ARTICLE

Prenatal Ultrasound Findings of Pregnancy Associated with Zika Virus Infection

Yen-Ni Chen¹, Chih-Ping Chen^{1,2,3,4,5,6*}, Chen-Ju Lin¹,
Shin-Wen Chen¹

¹ Department of Obstetrics and Gynecology, ² Department of Medical Research, Mackay Memorial Hospital, Taipei, ³ Department of Biotechnology, Asia University, ⁴ School of Chinese Medicine, College of Chinese Medicine, China Medical University, Taichung, ⁵ Institute of Clinical and Community Health Nursing, and ⁶ Department of Obstetrics and Gynecology, School of Medicine, National Yang-Ming University, Taipei, Taiwan

Received 10 August 2016; accepted 22 August 2016

Available online ■ ■ ■

KEYWORDS

microcephaly,
prenatal ultrasound,
Zika virus

Abstract The outbreak of Zika virus followed by an increase in cases of fetal microcephaly in Brazil in 2015 has raised the concern of the association of Zika virus infection with fetal microcephaly and other central nervous system (CNS) malformations. Most patients with Zika virus infection are asymptomatic. However, according to a previous report, the most common symptom in pregnant women with Zika virus infection and fetal microcephaly is rash. Reported prenatal ultrasound findings are microcephaly, lissencephaly, agenesis of corpus callosum, intracranial calcification, cerebellar atrophy, ventriculomegaly, brain hypoplasia, microphthalmia, abnormal amniotic fluid volume, abnormal cerebral blood flow, abnormal umbilical artery blood flow, hydrocephalus, intrauterine growth restriction, and arthrogryposis which are mostly CNS lesions. Pregnant women who have a traveling history in active infection areas should have serological testing for Zika virus infection. Targeted ultrasound examinations at 18–20 weeks of gestation and serial ultrasound follow-ups are also suggested. In the cases of fetal microcephaly, intracranial anatomy and extracranial abnormalities should be also carefully examined. Amniocentesis might be needed for suspected Zika virus infection, genetic abnormalities, or other congenital infection.

© 2016, Elsevier Taiwan LLC and the Chinese Taipei Society of Ultrasound in Medicine. This is an open access article under the CC BY-NC-ND license (<http://creativecommons.org/licenses/by-nc-nd/4.0/>).

Conflicts of interest: The authors have no conflicts of interest relevant to this article.

* Correspondence to: Dr Chih-Ping Chen, Department of Obstetrics and Gynecology, Mackay Memorial Hospital 92, Section 2, Chung-Shan North Road, Taipei, Taiwan.

E-mail address: cpc_mmh@yahoo.com (C.-P. Chen).

<http://dx.doi.org/10.1016/j.jmu.2016.08.007>

0929-6441/© 2016, Elsevier Taiwan LLC and the Chinese Taipei Society of Ultrasound in Medicine. This is an open access article under the CC BY-NC-ND license (<http://creativecommons.org/licenses/by-nc-nd/4.0/>).

Please cite this article in press as: Chen Y-N, et al., Prenatal Ultrasound Findings of Pregnancy Associated with Zika Virus Infection, Journal of Medical Ultrasound (2016), <http://dx.doi.org/10.1016/j.jmu.2016.08.007>

Introduction

Zika virus is a flavivirus which was first isolated in rhesus monkeys in 1947 [1]. The primary transmission vector of Zika virus is *Aedes* mosquitoes. Sexual transmission from males to their partners [2–6] have also been reported. Severe outbreaks have been reported in countries in Africa and Asia, then the Pacific region (Yap island in 2007, French Polynesia in 2013), and more recently to the Americas (Brazil in 2015) [7]. In January, 2015, an outbreak in northeast Brazil was noted. Later, in September, an increased number of newborns with microcephaly and other central nervous system (CNS) abnormalities were reported at the infected area (at least 4783 suspected and 404 confirmed cases) which suggested that Zika virus infection might be teratogenic [8]. Further investigation showed positive Zika virus reverse transcription polymerase chain reaction (RT-PCR) results in the amniotic fluid and postmortem fetal brain of the fetuses with microcephaly [9]. Maternal–fetal vertical transmission was confirmed to be the other way of transmission and the cause of fetal abnormalities. Therefore, the possibility of Zika virus associated with fetal congenital CNS malformations was reported by the Center for Disease Control and Prevention (CDC) in January, 2016 [4].

Here we will discuss the possible prenatal fetal abnormalities associated with Zika virus infection, and the recommendations.

Clinical manifestations

Zika virus infection can be symptomatic (20%) or asymptomatic (80%). The major symptoms of Zika virus infection are maculopapular rash, fever, nonpurulent conjunctivitis, and arthralgia. Other less common symptoms are myalgia, headache, retro-orbital pain, edema, and vomiting [10]. Symptoms usually last from several days to 1 week. Although 80% patients are asymptomatic, 74% of mothers were reported to have a rash in the first 35 cases of microcephaly in Brazil [4]. Brasil et al [11] suggest that rash is the most common symptom (100%) in pregnant women with Zika virus infection. The second most common symptom is pruritus (94%) and the third is arthralgia (65%) (Table 1). In the

Table 1 Possible clinical manifestations of Zika virus infection in pregnancy.

Maculopapular rash
Pruritus
Arthralgia
Conjunctival injection
Headache
Fatigue or malaise
Retro-orbital pain
Myalgia
Paresthesia
Lymphadenopathy
Fever
Nausea or vomiting
Gingival bleeding

preliminary report, fetal abnormalities were detected by Doppler ultrasonography in 12 of the 42 ZIKV-positive women (29%) regardless of the timing of maternal infection. Guillain-Barre syndrome has also been reported after Zika virus infection [12,13].

Laboratory diagnosis

Current laboratory diagnosis includes RT-PCR detection of virus RNA during the acute phase (5–7 days after the onset of symptoms) or serum immunoglobulin (Ig) M antibodies to Zika virus during the convalescent phase (from 4 days to 12 weeks after the onset of symptoms) [10,14]. In the case of a positive serous IgM antibodies test, plaque reduction neutralization test is also advised for exclusion of other flavivirus infections [15]. In the case of a suspected fetal Zika virus infection, RT-PCR of viral RNA has also been used in amniotic fluid [16], but the sensitivity and specificity is unknown.

The World Health Organization (WHO) interim guidance development group defines the diagnosis of Zika virus-related fetal brain/other abnormalities as “fetal brain/other abnormalities with a molecular or epidemiological link to Zika virus, and without other known conditions to cause fetal abnormalities” [10]. Therefore, conditions including genetic abnormalities, other congenital infection, or teratogenic agent exposure should be ruled out first.

Pathogenesis

The pathogenesis of microcephaly and CNS malformations associated with Zika virus is still under investigation. One of the hypotheses is that Zika virus is neurotropic because neuronal degeneration, cellular infiltration and areas of softening are present in Zika virus-infected mouse brains [17], suggesting that Zika virus acts directly on neural progenitor cells and then causes CNS malformations. Another hypothesis is that the destruction of the CNS is through the immune system, where the antibodies formed following infection may act against the neuronal myelin sheath, because Guillain-Barre syndrome associated with Zika virus infection was also reported [12,13]. However, the relationship between the timing of maternal infection and fetal abnormalities are still under investigation.

Ultrasound findings

Reported possible ultrasound findings are microcephaly, lissencephaly, agenesis of corpus callosum, intracranial calcification, cerebellar atrophy, ventriculomegaly, brain hypoplasia, hydrocephalus, microphthalmia, abnormal amniotic fluid volume, abnormal cerebral blood flow, abnormal umbilical artery blood flow, intrauterine growth restriction, and arthrogyriosis which are mostly CNS lesions (Table 2) [4,9,11,16,18–22].

The most common ultrasound finding is microcephaly. However, the incidence of microcephaly in Zika virus-infected pregnant women is not well-known. A recent prospective study estimated that the risk of microcephaly

Download English Version:

<https://daneshyari.com/en/article/8823596>

Download Persian Version:

<https://daneshyari.com/article/8823596>

[Daneshyari.com](https://daneshyari.com)