

Available online at www.sciencedirect.com

ScienceDirect

journal homepage: <http://Elsevier.com/locate/radcr>

Emergency Radiology

Acute traumatic superficial femoral arterial laceration findings on computed tomographic angiography: A case report

Shinsuke Takeda MD^{a,b,c,*}, Masahiro Tatebe MD, PhD^b, Yoshine Mori MD, PhD^d, Kenji Tanaka MD^c, Akihiko Tabuchi MD^a, Hitoshi Hirata MD, PhD^b

^a Emergency and Critical Care Center, Anjo Kosei Hospital, 28 Higashihirokute, Anjo, Aichi 466-8602, Japan

^b Department of Hand Surgery, Nagoya University Graduate School of Medicine, 65 Tsurumai-cho, shouwa-ku, Nagoya, Aichi 466-0065, Japan

^c Hand and Microsurgery Center, Anjo Kosei Hospital, 28 Higashihirokute, Anjo, Aichi 466-8602, Japan

^d Department of Radiology, Anjo Kosei Hospital, Anjo, Aichi, Japan

ARTICLE INFO

Article history:

Received 29 December 2017

Accepted 26 February 2018

Available online 11 April 2018

Keywords:

Superficial femoral arterial injury

Arterial laceration

Computed tomographic angiography

ABSTRACT

We present a case of superficial femoral artery laceration that was identified on computed tomographic angiography. The patient was a 25-year-old man who injured his right proximal thigh while using a wood sanding machine and was transferred to our emergency department in a state of hemorrhagic shock. Following resuscitation, preoperative computed tomographic angiography helped predict the arterial injury and aided us in prompt diagnosis and decisive management.

© 2018 the Authors. Published by Elsevier Inc. under copyright license from the University of Washington. This is an open access article under the CC BY-NC-ND license (<http://creativecommons.org/licenses/by-nc-nd/4.0/>).

Introduction

Enhanced computed tomography (ECT) is used to rapidly and reliably diagnose arterial injuries of the extremities in the setting of trauma, thus reducing treatment delay that can be fatal owing to blood loss [1]. Femoral vessels are among the most commonly injured vascular structures, being involved in nearly 70% of all arterial injuries [2,3]. The majority of injuries are secondary to penetrating trauma, particularly gunshot wounds [2–5]. Femoral artery injury, especially lacer-

ation caused by a sanding machine used in wood processing, is rare [2–5]. Several studies have evaluated computed tomographic angiography (CTA) in the diagnosis of trauma-related extremity arterial injuries [1,6–8]. However, there are no reports documenting the importance of CTA images in the detection or treatment of linear arterial lacerations in the emergency unit. Herein, we report a life-threatening case of a linear laceration of the superficial femoral artery (SFA), which was caused by a sanding machine. Preoperative prediction of SFA injury by CTA enabled prompt diagnosis and decisive treatment.

Competing Interests: The authors declare that they have no conflict of interest.

* Corresponding author.

E-mail address: s7.takeda.jpn@gmail.com (S. Takeda).

<https://doi.org/10.1016/j.radcr.2018.02.028>

1930-0433/© 2018 the Authors. Published by Elsevier Inc. under copyright license from the University of Washington. This is an open access article under the CC BY-NC-ND license (<http://creativecommons.org/licenses/by-nc-nd/4.0/>).

Case report

A 25-year-old man injured his right proximal thigh while using a sanding machine for wood processing. He was transferred to our emergency department in a state of hemorrhagic shock, 45 minutes after sustaining the injury. He was brought to the emergency department with the sanding machine, which had entrapped his penile skin (Fig. 1A). Although there was a large longitudinal laceration involving the skin and soft tissue of the proximal part of his thigh, measuring about 22 cm, we could not confirm the exact wound size and depth owing to the hemostatic bandages applied by the emergency medical technicians (Fig. 1B). We observed active oozing of blood through the bandage. On physical examination, the patient had marked facial pallor, cold peripheries, and nonpalpable bilateral dorsalis pedis pulses. His vital signs on admission indicated severe hemorrhagic shock: Glasgow Coma Scale, E3V4M6; temperature, 36.7°C; heart rate, 110 beats/min; left arm blood pressure, 75/44 mm Hg; respiratory rate, 22 breaths/min; and 100% oxygen saturation, on a 100% non-rebreather reservoir mask at 10 L/min of oxygen. We initiated fluid resuscitation for hemorrhagic shock with approximately 1.5 L of crystalloids, which was effective in stabilizing the patient's vital signs: heart rate, 95 beats/min, and left arm blood pressure, 110/65 mm Hg. We avoided disturbing the bandages, and the oozing of blood persisted despite additional manual compression. While continuing blood transfusion through central (right internal jugular vein) and peripheral (left median antebrachial vein) routes, we performed lower extremity ECT with a high-resolution sequence (0.5-mm slice thickness; Brilliance CT scanner, 64-row Aquilion multislice CT system; Toshiba, Tokyo, Japan). We administered 100 mL of iohexol (Omnipaque, 300 mg of iodine/mL; Bayer, Japan) intravenously at a rate of 2.5 mL/s by using a power injector. As per our protocol for lower extremity scanning, a delay of 50 seconds between the beginning of the injection and scanning was maintained. The thin-slice axial ECT images demonstrated hematoma around the SFA and extravasation at its branches. The ECT images also revealed abrupt narrowing of the SFA corresponding to the open wound and contusion over the vastus medialis muscle (Fig. 2). Radiographs ruled out any fracture of the right femur.

The patient was shifted to the operating room for an emergency operation under general anesthesia. A thigh tourniquet

(350 mm Hg) was applied just proximal to the open wound. As there was rapid pulsatile bleeding from the injured artery on releasing the constriction bandage, we also kept an intra-aortic balloon occlusion device as a standby measure. At induction, the patient's hemoglobin on blood gas analysis was 5.2 g/dL. Intraoperatively, we found a linear laceration of the SFA measuring 1 cm, at almost the same level as the adductor canal (Fig. 3), complete avulsion of the muscular branches of the SFA, complete avulsion of the saphenous nerve and the muscular branch of the femoral nerve to the vastus medialis, and extensive contusion of the vastus medialis muscle. The femoral vein was intact. The operation in the narrow working space was facilitated by the presence of the tourniquet. The SFA laceration was repaired by using continuous 6-0 synthetic vascular suture while the distal and proximal arteries were controlled by arterial clamps. All the avulsed muscular branches were ligated. Nerve regeneration conduits (Nerbridge; Toyobo Co., Ltd, Osaka, Japan) were used for repairing defects measuring 15–18 mm in the 2 injured nerves. The fascia and the skin were primarily closed, in layers. The penile skin injury was mild and did not require suturing. The total volume of resuscitation during surgery included 2800 mL of red cells, 2160 mL of fresh frozen plasma, and more than 3000 mL of intravenous fluids. The patient improved clinically, and postoperative ECT on day 14 confirmed the absence of thrombosis or stenosis of the sutured SFA. At his discharge on day 16, the patient had residual sensory disturbance of the saphenous nerve territories in his right lower extremity. We now observe the postoperative prognosis of the repaired nerve by the nerve regeneration conduits.

Discussion

This is the first case to report the usefulness of CTA as a preoperative examination for the management of acute traumatic arterial laceration. Although it is essential to control the bleeding in vascular injuries, blind application of hemostatic clamps should never be performed [7]. Further, we also avoided the removal of the pressure bandage until the vital signs were stabilized, anesthesia backup and instrumentation was arranged, and the patient was shifted to the operating room. Moreover, most importantly, the accurate identification of the bleeding

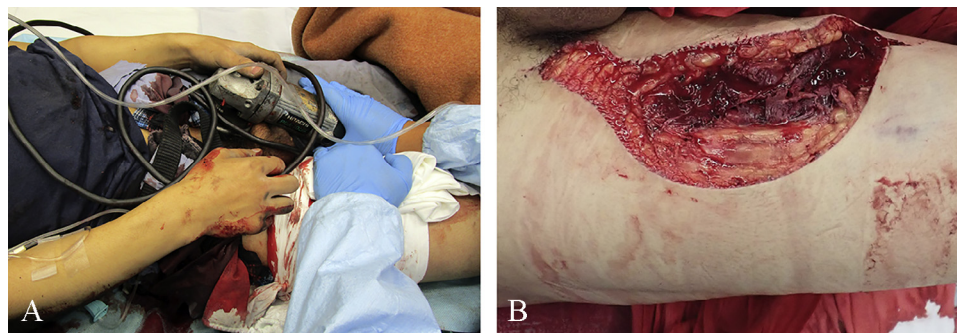


Fig. 1 – (A) The penile skin is trapped in the disk of a sanding machine, and the wound extent could not be confirmed because of the hemostatic bandage. (B) A large laceration (approximately 22 cm) is seen in the proximal part of the thigh.

Download English Version:

<https://daneshyari.com/en/article/8825003>

Download Persian Version:

<https://daneshyari.com/article/8825003>

[Daneshyari.com](https://daneshyari.com)