

Available online at www.sciencedirect.com

ScienceDirect

journal homepage: <http://Elsevier.com/locate/radcr>

Neuroradiology

Pituitary stalk interruption syndrome presenting in a euthyroid adult with short stature

Atif Nawaz MBBS, FCPS-I, FRCR-I*, Muhammad Azeemuddin MBBS, MCPS, FCPS, Jehanzeb Shahid MBBS, FCPS-I

Radiology Department, The Aga Khan University, Stadium Road P. O. Box 3500, Karachi 74800, Pakistan

ARTICLE INFO

Article history:

Received 13 October 2017

Received in revised form 27

November 2017

Accepted 1 December 2017

Available online 5 January 2018

Keywords:

MRI

ABSTRACT

Pituitary stalk interruption syndrome (PSIS) is a distinct and rare clinical entity responsible for congenital hypopituitarism resulting in deficiency of pituitary hormones with deficiency of the growth hormone (100%) and gonadotropins (97.2%) being its most common presentation at the time of hospital encounter (Wang et al., 2015).

Isolated sparing of thyroid-stimulating hormone (TSH) with deficiency of the remaining anterior pituitary hormones may be present in PSIS, as is true in our case. Therefore, it should be kept in mind at the time of examination in suspected cases of PSIS.

© 2017 the Authors. Published by Elsevier Inc. under copyright license from the University of Washington. This is an open access article under the CC BY-NC-ND license (<http://creativecommons.org/licenses/by-nc-nd/4.0/>).

Introduction

Pituitary stalk interruption syndrome (PSIS) is a rare clinical entity with a reported incidence of 0.5/100,000 live births [1]. The first case in the literature was reported in 1987 by Fujisawa et al. after surgical resection of pituitary stalk in patients with idiopathic pituitary dwarfism [2]. The pathophysiology of PSIS is not fully understood, but chromosomal microdeletions and perinatal asphyxia have some established role in the literature as primary miscreants [3,4]. Recent increased incidence of this entity is attributed to novel advancements in radiology and increased use of magnetic resonance imaging (MRI) in patients with suspected hypopituitarism leading to early diagnosis followed by prompt hormonal replacement therapies.

Case report

We report a case of a 32-year-old male patient who was referred from an endocrinology clinic with complaints of short stature and primary infertility. MRI examination for sella was performed at our department and a diagnosis of ectopic posterior pituitary gland was made.

Our case is unique for multiple reasons. Firstly, the age of presentation at our hospital was 32 years, which is a relatively late age of presentation as compared with the mean age. Secondly, tertiary hypothyroidism was not a characteristic of our case as it is, in previously reported cases in the literature. Lastly, only 1 case is reported in the literature from Pakistan to the best of our knowledge to date [5].

Competing Interests: The authors have declared that no competing interests exist.

* Corresponding author.

E-mail address: atif.nawaz@aku.edu (A. Nawaz).

<https://doi.org/10.1016/j.radcr.2017.12.002>

1930-0433/© 2017 the Authors. Published by Elsevier Inc. under copyright license from the University of Washington. This is an open access article under the CC BY-NC-ND license (<http://creativecommons.org/licenses/by-nc-nd/4.0/>).

Case presentation and investigations

Our case is a 32-year-old man referred to us from endocrinology with complaints of short stature and underdeveloped secondary sexual characteristics. He was a nondiabetic and nonhypertensive and had no other known comorbidities. He had 4 siblings and had an insignificant family history. His father and mother had a height of 179 and 164 cm, respectively. There was no history of delayed achievement of developmental milestones and the patient had a good academic record. The patient sometimes complained of lethargy and generalized weakness but was treated symptomatically in the past. There was no known drug allergy or history of smoking. He was married for the past 5 years but had no offspring. Birth history was significant for birth asphyxia and was delivered by C-section because of breech presentation. History of previous surgeries and previous hospitalizations was also insignificant. On examination, the patient was a middle-aged man of average build but short stature, who was fully aware of time, space, and person. The patient had underdeveloped secondary sexual characteristics with decreased facial, pubic, and axillary hair growth. His height was 152 cm and he had a midparental height of 171.5 cm (range 164-179 cm). Pelvis examination showed a normal-appearing scrotum with both testes in the scrotal sac but with a smaller volume (1 and 1.5 mL, respectively). The stretch penile length was 3.5 cm.

Laboratory investigations revealed a hemoglobin level of 13.4 g/dL, with normal total and differential counts, a serum sodium level of 139 mmol/L, a serum potassium level of 4.3 mmol/L, and serum chloride, calcium, and phosphate levels of 102 mmol/L, 9.1 mg/dL, and 6.1 mg/dL respectively. Random blood sugar level was 118 mg/dL and albumin was at 3.9 mg/dL. A complete pituitary hormone profile was performed at our institute, which showed picture of hypopituitarism with relative thyroid sparing. Free T3 and T4 were 4.0 pmol/L (normal 3.5-7.8 pmol/L) and 17.3 pmol/L (9-25 pmol/L). Values for anti-TPO and anti-TG antibodies were also within normal range. Corticotropins were also accessed via short early morning synacthen test showing a morning baseline cortisol level of 0.82 µg/dL (normal = 4.3-22.4 µg/dL), and dexamethasone suppression test revealed cortisol after 60 minutes of 250 mcg cosyntropin injection was 3.1 µg/dL. Insulin-like growth factor levels were 63.3 ng/dL (normal = 245 to 480 ng/mL), follicle-stimulating hormone was 0.32 µIU/mL (normal, 0.0-10.0), and leutinizing hormone was under 0.21 µIU/mL (normal = 1.2-7.8). The patient's morning testosterone level was under 7.9 ng/dL (normal = 280-800 ng/dL). No evidence was noted for posterior pituitary hormone deficiency as urine and serum osmolality was within normal limits, with no complaints of polydipsia and polyuria as well.

MRI examination was performed with pituitary protocol using 1-mm slice thickness. The pituitary gland was not identified in the sella turcica; instead, a T1 hyperintense focus was identified posterior to the optic chiasma in the midline with postcontrast enhancement representing an ectopic posterior pituitary gland (Figs. 1-3). Normal pituitary stalk was not identified, along with nonvisualization of adenohypophysis, thus meeting the typical triad of PSIS [6,7].

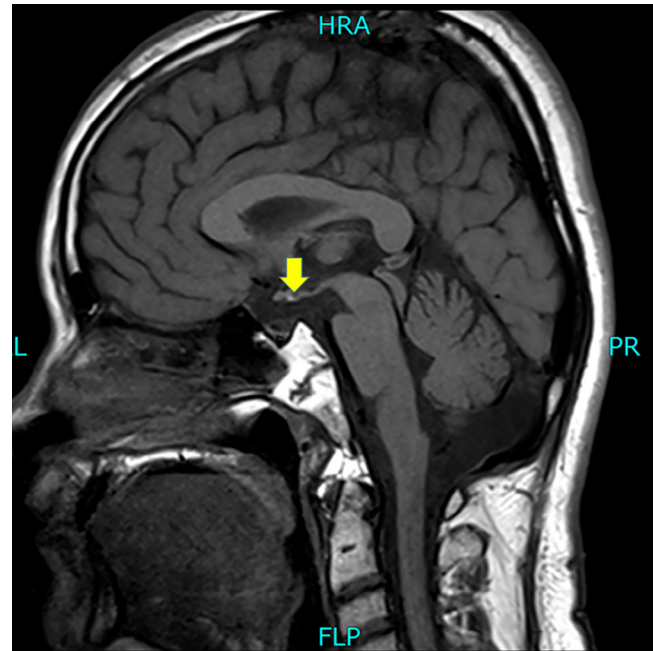


Fig. 1 – T1 sagittal image without contrast, showing hyperintense focus posterior to optic chiasma (yellow arrow). FLP, foot left posterior; HRA, head right anterior; L, left; PR, posterior right.

Assessment of bone age was also done by plain radiograph. A skeletal survey showed a bone age of 20 years using the Tanner-Whitehouse method [8].

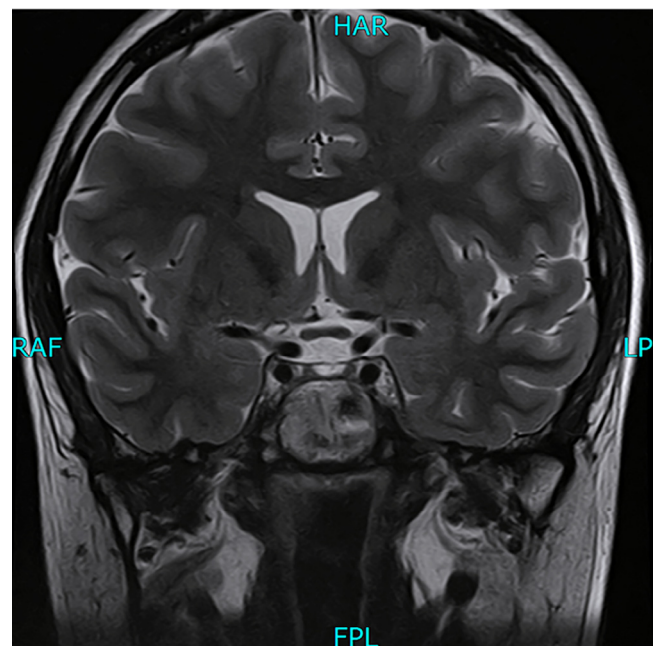


Fig. 2 – Coronal T2 image showing nonvisualization of the pituitary stalk. FPL, foot posterior towards left; HAR, head anterior towards right; LP, left posterior; RAF, right anterior towards front.

Download English Version:

<https://daneshyari.com/en/article/8825122>

Download Persian Version:

<https://daneshyari.com/article/8825122>

[Daneshyari.com](https://daneshyari.com)