

Available online at www.sciencedirect.com

ScienceDirect

journal homepage: <http://Elsevier.com/locate/radcr>

Gastrointestinal

Laparoscopic adjustable gastric band erosion with intragastric band migration: A rare but serious complication

Partha Hota DO, Dina Caroline MD, Sonia Gupta MD, Omar Agosto MD*

Division of Abdominal Imaging, Department of Radiology, Temple University Hospital, 3401 N. Broad St., Philadelphia, PA 19140, USA

ARTICLE INFO

Article history:

Received 6 November 2017

Received in revised form 13

November 2017

Accepted 13 November 2017

Available online

ABSTRACT

Although laparoscopic adjustable gastric banding is considered the most minimally invasive surgical technique for the treatment of morbid obesity, the procedure has a reported overall complication rate of up to 26%. Among the various complications, gastric band erosion with intragastric band migration is the most worrisome because of the risk of subsequent obstruction, peritonitis, and sepsis. Therefore, prompt and accurate diagnosis is crucial during imaging evaluation of these patients in the late postoperative setting. In this article, we report a case of a 47-year-old woman with a gastric band that had eroded into the gastric wall with intragastric migration demonstrating classic findings on fluoroscopic and computed tomography imaging.

© 2017 the Authors. Published by Elsevier Inc. under copyright license from the University of Washington. This is an open access article under the CC BY-NC-ND license (<http://creativecommons.org/licenses/by-nc-nd/4.0/>).

Introduction

Morbid obesity continues to be a major chronic healthcare problem worldwide with an estimated annual medical cost in the United States alone totaling \$147 billion [1]. In recent decades, bariatric surgery has evolved from a nascent pioneer phase to a myriad of sophisticated surgeries numbering 196,000 performed in 2015 [2]. First introduced in 1993, laparoscopic adjustable gastric banding (LAGB) consists of an inflatable gastric band placed below the gastroesophageal junction resulting in the creation of a gastric pouch, with the effective diameter of

the band controlled by a subcutaneous port via a connecting tube [3]. Although originally a popular surgical technique at the time of its introduction, highly reported complication rates of 10%-26% have resulted in a marked decline of LAGB insertion, now accounting for only 6% of all bariatric surgeries [4-6]. Reported complications and incidence of laparoscopic gastric banding include band erosion (28%), port-tubing disconnection (20%), band slippage (4%-13%), incisional hernia (5%), port infection (2%), gastric band erosion with intragastric band migration (2%-4%), and gastric perforation (0.1%-0.8%) [7-9]. Among these complications, gastric band erosion with intragastric band migration is most worrisome because of the risk of subsequent

No institutional review board approval was required for this manuscript.

Competing Interests: The authors have declared that no competing interests exist.

* Corresponding author.

E-mail address: omar.agosto@tuhs.temple.edu (O. Agosto).

<https://doi.org/10.1016/j.radcr.2017.11.012>

1930-0433/© 2017 the Authors. Published by Elsevier Inc. under copyright license from the University of Washington. This is an open access article under the CC BY-NC-ND license (<http://creativecommons.org/licenses/by-nc-nd/4.0/>).

obstruction, peritonitis, and sepsis [4]. Therefore, prompt and accurate diagnosis is crucial during imaging evaluation of these patients in the postoperative setting. Here, we report a case of gastric band erosion with subsequent migration into the stomach.

Case report

A 47-year-old Caucasian woman with a history of laparoscopic gastric band placement 9 years prior presented to our outpatient bariatric surgery clinic with a 1-month history of intermittent shortness of breath and epigastric tenderness. The patient reported a total weight loss of 120 pounds, which she had maintained for the previous 5 years with the last gastric band adjustment performed 2 years prior without apparent complication. The patient denied nausea, vomiting, or significant weight gain. Physical examination revealed tenderness superficial to the laparoscopic gastric band port site with abdominal pain exacerbated by movement. Vital signs and laboratory data were within normal limits. A precontrast radiograph from a double contrast upper gastrointestinal study (Fig. 1) demonstrated a gastric band with a normal phi angle of 48°. After administration of barium oral contrast, contrast was identified pooling circumferentially around the band suspicious for intragastric band migration without evidence of gastric leak. A subsequent contrast-enhanced computed tomography (CT) of abdomen examination (Fig. 2) confirmed a completely intraluminal location of the gastric band within the stomach cardia. The patient was admitted to the hospital and underwent an esophagogastroduodenoscopy (Fig. 3) at which time the gastric band was found to have completely eroded through the gastric wall and was located almost entirely intraluminally. The gastric band was removed laparoscopically

through the abdomen with the gastrostomy site repaired by incorporation of a fat patch and adjacent gastric wall around the closure site. In addition, a Dor fundoplication was performed. Two days later, a single contrast upper gastrointestinal study demonstrated an intact anastomosis without evidence of obstruction or leak. The patient had an uncomplicated postoperative hospital course and was subsequently discharged 1 week later.

Discussion

Although a common form of bariatric surgery at the turn of the century and considered the least invasive bariatric surgical procedure, the incidence of LAGB has declined in the past decade as a result of the relatively high complication rate and increasing popularity of alternative procedures, including sleeve gastrectomy and Roux-en-Y gastric bypass [10]. Of the reported complications, gastric band erosion with intragastric band migration is considered particularly worrisome because of the increased risk of obstruction and peritonitis.

First described in 1998, gastric erosion is a major complication of LAGB with an incidence reported to be between 0.3% and 28%, with the wide range likely attributed to variation in the routine imaging follow-up period of patients in different institutions [8,11,12]. Gastric erosion and intragastric band migration may occur either in the early or in the late postoperative settings. Pathogenesis of gastric band erosion is multifactorial and is dependent on the postoperative time frame. In the early setting, gastric erosion is thought to be secondary to iatrogenic gastric wall damage from the initial procedure or microperforation after postoperative infection [6,13]. Additional risk factors have been reported in the early postoperative setting including formation of adhesions and the use of

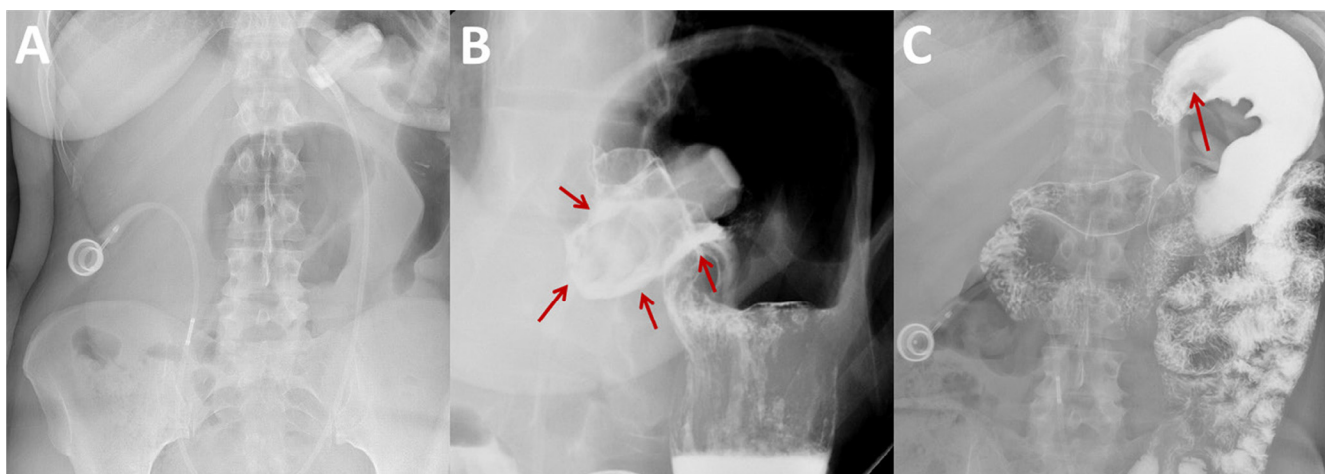


Fig. 1 – Supine radiograph (A) demonstrates the laparoscopic gastric band in appropriate orientation with a normal phi angle. After administration of oral contrast during a double contrast upper gastrointestinal study, an upright spot radiograph (B) demonstrates pooling of oral contrast surrounding the intragastric portion of the laparoscopic adjustable gastric band (arrows) compatible with band erosion with intragastric migration. A prone radiograph obtained at the conclusion of the study (C) demonstrates a completely contrast-filled stomach fundus and body with nonvisualization of the normal radiopaque gastric band. A filling defect in the gastric cardia (arrow) corresponds to the gastric band located within the stomach lumen. There is no extraluminal contrast identified to suggest a gastric leak.

Download English Version:

<https://daneshyari.com/en/article/8825170>

Download Persian Version:

<https://daneshyari.com/article/8825170>

[Daneshyari.com](https://daneshyari.com)