

## REFERENCES

1. Abcarian H, Alexander-Williams J, Christiansen J, Johanson J, Killingback M, Nelson RL, et al. Bening anorectal disease: definition, characterization and analysis of treatment. *Am J Gastroenterol*. 1994;89 Suppl. 8:S182-93.
2. Nivatvongs S. Hemorrhoids. In: Philip G, editor. *Principles and practice of surgery*. 3rd ed. Nueva York: Informa Healthcare; 2007; p. 143-66.
3. Madoff RD, Fleshman JW, Clinical Practice Committee, American Gastroenterological Association. American Gastroenterological Association technical review on the diagnosis and treatment of hemorrhoids. *Gastroenterology*. 2004;126:1463-73.
4. Lewis RT, Maron DJ. Anorectal Crohn's disease. *Surg Clin N Am*. 2010;90:83-97.
5. Radcliffe AG, Ritchie JK, Hawley PR, Lennard-Jones JE, Northover JM. Anovaginal and rectovaginal fistulas in Crohn's disease. *Dis Colon Rectum*. 1988;31:94-9.
6. Morrison JG, Gathright JB Jr, Ray JE, Ferrari BT, Hicks YC, Timmcke AE. Results of operation for rectovaginal fistula in Crohn's disease. *Dis Colon Rectum*. 1989;32:497-9.
7. Cracco N, Zinicola R. Is haemorrhoidectomy in inflammatory bowel disease harmful? An old dogma re-examined. *Colorectal Dis*. 2014;16:516-9.
8. D'Ugo S, Franceschilli L, Cadeddu F, Leccesi L, Blanco G del V, Calabrese E, et al. Medical and surgical treatment of haemorrhoids and anal fissure in Crohn's disease: a critical appraisal. *BMC Gastroenterol*. 2013;13:47.
9. Vidal V, Sapoval M, Sielezneff Y, de Parades V, Tradi F, Louis G, et al. Emborrhoid: a new concept for the treatment of hemorrhoids with arterial embolization: the first 14 cases. *Cardiovasc Intervent Radiol*. 2015;38:72-8.
10. Vidal V, Louis G, Bartoli JM, Sielezneff I. Embolization of the hemorrhoidal arteries (the emborrhoid technique): a new concept and challenge for interventional radiology. *Diagn Interv Imaging*. 2014;95:307-15.

Vicent Primo Romaguera<sup>a\*</sup>, Abel Gregorio Hernández<sup>b</sup>,  
Luís Andreo Hernández<sup>b</sup>, Eduardo de la Morena Valenzuela<sup>a</sup>

<sup>a</sup>Servicio de Cirugía General y Digestiva, Hospital de Dénia Marina-Salud, Dénia, Alicante, Spain

<sup>b</sup>Servicio de Radiología, Hospital de Dénia Marina-Salud, Dénia, Alicante, Spain

\*Corresponding author.

E-mail address: [sentopr@gmail.com](mailto:sentopr@gmail.com) (V. Primo Romaguera).

2173-5077/

© 2017 AEC. Published by Elsevier España, S.L.U. All rights reserved.

## Surgical Treatment of Supraclavicular and Internal Mammary Recurrence of Breast Cancer<sup>☆</sup>



### Tratamiento quirúrgico de la recidiva supraclavicular y a nivel de la mamaria interna por un carcinoma de mama

Brito et al.<sup>1</sup> treated patients with supraclavicular lymph node involvement using multimodal therapy with curative intent (chemotherapy [CTx], surgery and radiotherapy). With this method, they obtained better results than in patients who presented distant disease that was not supraclavicular. These results led to the review and modifications of the American Joint Committee on Cancer (AJCC-TNM) classification. Since its sixth edition, metastases in the ipsilateral supraclavicular lymph nodes have ceased to be considered distant metastases (M1) and have been classified as locoregional disease (N3c).<sup>2,3</sup> To this day, the debate continues and no consensus has been reached for the treatment of these patients.

Likewise, contralateral axillary involvement should be considered stage IV and therefore the treatment of these patients should be palliative.<sup>4</sup> However, there is a hypothesis that dissemination to the contralateral axilla could occur by the lymphatic pathway, therefore locoregional curative treatment would be justified.<sup>5</sup> Therefore, the management

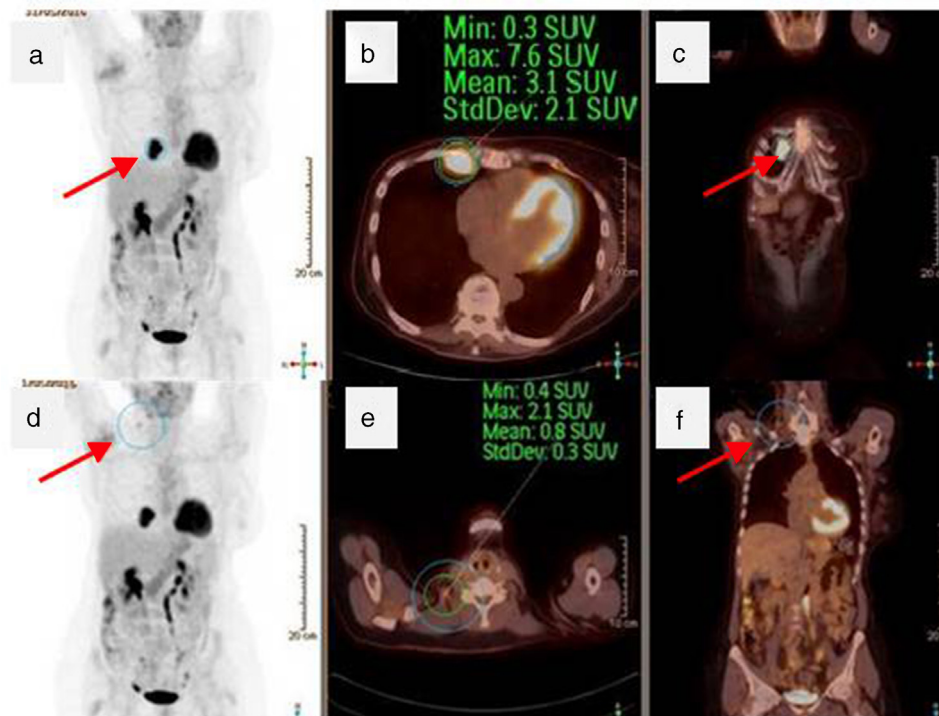
of this situation is not standardized and must be individualized for each patient.

We present a controversial clinical case using multimodal treatment, associating surgery of a metastatic breast carcinoma with contralateral and ipsilateral supraclavicular lymph nodes.

A 57-year-old woman presented with a 10 cm ulcerated tumor infiltrating the skin and chest wall of the right breast. Mammography, magnetic resonance imaging with gadolinium contrast and core-needle biopsy diagnosed the mass as invasive ductal carcinoma (IDC) of the right breast with ipsilateral and contralateral axillary lymph node involvement (cT4c cN1c M1). Immunohistochemistry study reported: estrogen receptors (ER) +++, progesterone receptors (PR) +, cerbB2 ++ (positive FISH), Ki 67 20%.

After 8 cycles of CTx with docetaxel, trastuzumab and pertuzumab with good radiological response, radical mastectomy was performed with right and left axillary lymph node dissection. The pathology study of the piece reported an

<sup>☆</sup> Please cite this article as: de Andrés Gómez A, Villalba Ferrer F, Navarro Moratalla C, Guijarro Jorge R, Fuster Diana C. Tratamiento quirúrgico de la recidiva supraclavicular y a nivel de la mamaria interna por un carcinoma de mama. *Cir Esp*. 2018;96:241-244.



**Fig. 1 – Total-body PET/CT: (a) coronal PET image showing hyperuptake of the internal breast (arrow); (b) axial PET/CT showing the same lesion (circle); (c) coronal PET/CT image with the lesion in white (arrow); (d) coronal PET view with hyperuptake in the right supraclavicular region; (e) axial PET/CT slice demonstrating the same involvement (circle); (f) coronal PET/CT showing right cervical hyperuptake in white (arrow).**

IDC lesion measuring 3.5×3 cm (RE –, RP –, cerb B2 +++ and Ki 67 30%), grade 1, N + (1/14) and an invasive lobular carcinoma measuring 2×1.5 cm (RE –, RP –, cerbB2 –, Ki 67 5%–10%). The axillary lymphadenectomy dissection revealed bilateral lymph node involvement: 1/14 in the right axilla and 4/24 in the left axilla.

The patient did not receive radiotherapy due to limited mobility of the right glenohumeral joint and followed adjuvant treatment with trastuzumab-pertuzumab every 21 days.

Positron emission tomography/computed tomography (PET/CT) one year after surgery (Fig. 1) detected right supraclavicular lymph node and internal mammary involvement, confirmed by fine-needle aspiration. The internal mammary ultrasound detected nodal involvement with a hypoechoic lesion measuring 4×3×4 cm.

Three cycles of CTx were administered with TDM1 (trastuzumab emtansine) and subsequent PET/CT showed a decrease in size and right supraclavicular lymph node metabolism (SUV 2.1, previously 3.3), but increased internal mammary metabolism (SUV 7.6, previously 7) compared to the previous study. Surgical intervention was performed one month after the end of CTx, involving functional right lateral cervical dissection, excision of the internal mammary chain lesion and 5th, 6th and 7th anterior costal arches due to macroscopic involvement of the intercostal muscles. The wall defect was covered with a double-sided mesh (Fig. 2). The

patient progressed favorably and was discharged on the 5th postoperative day.

The pathological anatomy of the internal mammary chain lesion revealed a metastasis measuring 5×1.6 cm, with involvement of soft tissues (striated muscle and fibrous-fatty tissue) by lobular carcinoma, with no bone involvement, free resection margins and immunohistochemistry: RE –, RP –, cerbB2 –, Ki 67 5%–10%. From the cervical lymph node dissection, 52 lymphadenopathies were isolated with no tumor involvement. The patient currently continues with adjuvant CTx with TDM1 and is disease-free 9 months after the intervention.

There are numerous publications that evaluate the results of radiotherapy in the involvement of the internal and supraclavicular mammary arteries<sup>6,7</sup>; however, the role of surgery has not yet been studied.<sup>8</sup> In the review of the literature, there is a study that included patients with recurrence of the disease at the supraclavicular level where surgery was part of the treatment and concluded that surgical excision of these supraclavicular lymph nodes would be a prognostic factor for overall survival.<sup>9</sup>

The negative pathology results of the lymph nodes removed in the cervical lymphadenectomy could be explained by a complete response to CTx that was already evident in the re-evaluation PET after the end of the last cycle, where there was a decrease in metabolic activity.

Download English Version:

<https://daneshyari.com/en/article/8826530>

Download Persian Version:

<https://daneshyari.com/article/8826530>

[Daneshyari.com](https://daneshyari.com)