

REFERENCES

1. Siegel RL, Miller KD, Jemal A. Cancer Statistics, 2016. *CA Cancer J Clin.* 2016;66:7-30.
2. Berry DA, Cronin KA, Plevritis SK, Fryback DG, Clarke L, Zelen M, et al. Effect of screening and adjuvant therapy on mortality from breast cancer. *N Engl J Med.* 2005;353:1784-92.
3. Galcerani J, Ameijide A, Carulla M, Mateos A, Quirós JR, Alemán A, et al. Estimaciones de la incidencia y la supervivencia del cáncer en España y su situación en Europa. Red española de registros de cáncer (REDECAN); 2014. Available from: <http://www.redecn.org> [accessed 07.09.16]
4. Van Eijck CHJ, Krenning EP, Bootsma A, Oei HY, van Pel R, Lindemans J, et al. Somatostatin-receptor scintigraphy in primary breast cancer. *Lancet.* 1994;343:640-3.
5. Bajc M, Ingvar C, Palmer J. Dynamic Indium-111-Pentetreotide scintigraphy in breast cancer. *J Nucl Med.* 1996;37:622-6.
6. Reubi JC, Waser B, Foekens JA, Klijn G, Lamberts SWJ, Laissue J. Somatostatin receptor incidence and distribution in breast cancer using receptor autoradiography: relationship to EGF receptors. *Int J Cancer.* 1990;46:416-20.
7. Orlando C, Raggi CC, Bianchi S, Distante V, Simi L, Vezzosi V, et al. Measurement of somatostatin receptor subtype 2 mRNA in breast cancer and corresponding normal tissue. *Endocr Relat Cancer.* 2004;11:323-32.
8. Dalm S, Melis M, Emmering J, Kwekkeboom DJ, de Jong M. Breast cancer imaging using radiolabelled somatostatin analogues. *Nucl Med Biol.* 2016;43:559-65.
9. Kumar U, Grigorakis SI, Watt HL, Sasi R, Snell L, Watson P, et al. Somatostatin receptors in primary human breast cancer: quantitative analysis of mRNA for subtypes 1-5 and correlation with receptor protein expression and tumor pathology. *Breast Cancer Res Treat.* 2005;92:175-86.
10. Frati A, Rouzier R, Lesieur B, Werkoff G, Antoine M, Rodenas A, et al. Expression of somatostatin type-2 and -4 receptor and correlation with histological type in breast cancer. *Anticancer Res.* 2014;34:3997-4003.

Francisco-Javier Gómez-de la Fuente^a, Julio Jiménez-Bonilla^a, José Estévez^b, Isabel Martínez-Rodríguez^a, Ignacio Banzo^{a,*}

^aServicio de Medicina Nuclear, Grupo de Investigación Imagen Molecular IDIVAL, Hospital Universitario Marqués de Valdecilla, Universidad de Cantabria, Santander, Spain

^bServicio de Obstetricia y Ginecología, Hospital Universitario Marqués de Valdecilla, Universidad de Cantabria, Santander, Spain

*Corresponding author.

E-mail address: ignacio.banzo54@gmail.com (I. Banzo).

2173-5077/

© 2016 AEC. Published by Elsevier España, S.L.U. All rights reserved.

Giant Primary Extra Gastrointestinal Stromal Tumor of the Liver[☆]



Tumor del estroma extragastrointestinal primario hepático gigante

Gastrointestinal stromal tumors (GIST) are a group of mesenchymal neoplasms that affect the gastrointestinal tract, defined by the expression of the CD117 (c-kit) onco-protein.¹ Their appearance outside of the gastrointestinal tract is uncommon.

We present a case of primary hepatic extra-gastrointestinal stromal tumor (EGIST) in an adult patient with a negative extension study for another primary tumor, who was treated surgically, progressed favorably and is currently disease free.

The patient is a 41-year-old male with no personal history of interest. He was under study for abdominal discomfort and

weight loss in previous months. Upon examination, a mass was observed in the hypochondrium and right flank, which reached the right anterior superior iliac spine. Complete blood count was normal, with the following biochemistry results: cholesterol = 222 mg/dL (HDL = 69 mg/dL); total bilirubin = 1.65 g/dL at the expense of indirect (1.38 mg/dL) and GGT = 102 U/L. Liver enzymes, coagulation and tumor markers (α -fetoprotein, CEA, CA-125, CA 15.3 and CA 19.9) were normal.

CT scan and MRI showed a mass measuring 20 × 19.5 × 13.6 cm in length with significant contrast uptake, central necrotic areas and exophytic location (liver segments V and VI), with no infiltration of neighboring organs. The

[☆] Please cite this article as: Carrillo Colmenero AM, Serradilla Martín M, Redondo Olmedilla MD, Ramos Pleguezuelos FM, López Leiva P. Tumor del estroma extragastrointestinal primario hepático gigante. *Cir Esp.* 2017;95:547-550.

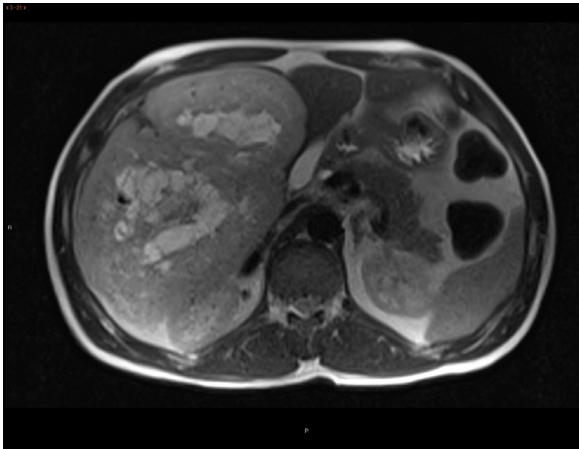


Fig. 1 – MRI: T2-weighted sequence of the axial plane showing a large well-outlined mass, exophytic, dependent on liver segments V-VI, with a compressive effect on extrahepatic structures yet no apparent infiltration and with an extensively necrotic central area or cystic degeneration.

differential diagnosis included hypervascular tumors (adenoma, hypervascular metastasis, sarcoma) (Fig. 1). Gastroscopy and colonoscopy were normal. PET/CT showed no extrahepatic uptake.

The patient underwent surgery, which revealed a hypervascularized encapsulated tumor with terminal involvement of the right suprahepatic branch. A segmentectomy was performed of liver segments V-VI, with an intraoperative blood loss of 600 cc due to this vascularization, requiring a single Pringle maneuver of 23 min.

The postoperative period transpired with type A liver failure, and the patient required the transfusion of 2 units of packed red blood cells. The patient was discharged from hospital on the 8th day post-op, with no further incidents.

The definitive histological diagnosis was: grade 1 GIST tumor, with spindle cells that infiltrated and destroyed the liver parenchyma, leaving a few nests of hepatocytes in the middle of the tumor growth (pT4). The mitotic rate was 5 mitoses per 50 high-power fields and the proliferative index (Ki-67) was 10%, with free surgical margins. The differential diagnosis included leiomyosarcoma and synovial sarcoma, with positivity for DOG-1, CD117 and Bcl-2, while desmin, S100 and CD34 were negative. The mutation analysis demonstrated deletion of exon 9 of the c-kit gene, confirming the diagnosis of GIST (Fig. 2).

After surgery, the patient initiated adjuvant therapy with imatinib at higher doses than usual due to the presence of

risk factors (size, mutation exon 9, Ki-67), and the follow-up PET/CT showed no evidence of hypermetabolic lesions suggestive of recurrence. Currently, the patient continues to be asymptomatic and in complete remission after 18 months of follow-up.

Presently, GIST tumors are defined as fusiform or epithelioid CD117-positive mesenchymal tumors that are primary tumors of the gastrointestinal tract, mesentery and retroperitoneum. GIST were first described in 1983 by Mazur and Clark to designate non-epithelial tumors of the digestive tract lacking smooth muscle ultrastructural features and immunohistochemical characteristics of Schwann cells.¹ GIST are the most common sarcoma of the gastrointestinal tract, accounting for 2% of gastrointestinal tumors, but 80% of sarcomas of this origin. The stomach is the most frequent location. Its incidence is 10 to 20 cases per million inhabitants/year.²⁻⁴ The maximum incidence is in the fourth and sixth decades; the distribution by gender is similar; although some studies suggest a predominance among males.^{2,3} GIST share immunophenotypic similarities with interstitial cells of Cajal and characteristics such as expression of CD117 glycoprotein, CD34, smooth muscle myosin heavy chain and nestin⁵ are common, although there is controversy about the origin from pluripotent stem cells.

The differential diagnosis includes morphologically similar or CD34-positive lesions (fibrohistiocytic tumors, peripheral nerve sheath tumors, Kaposi's sarcoma, etc.) and tumors that express c-kit (melanoma, dedifferentiated liposarcoma, undifferentiated small cell lung cancer).^{4,5}

The presence of metastasis and/or invasion of neighboring organs are criteria for malignancy. As for the molecular biology, the prognostic importance of c-kit mutations in exons 11, 9, 13 and 17⁵⁻⁷ is being assessed, along with other factors such as VEGF expression, loss of CD44 expression, p16 alterations and genetic markers (genetic overexpression of VIL2, COL8A1, CCNB2, HMG2, TSG101, etc.).⁷

Regarding tumor aggressiveness, all authors agree on the influence of tumor size and the mitotic index, establishing prognostic groups.^{8,9} The determination of cell proliferation with Ki-67 staining is also used (index of 10% or more is associated with a poor prognosis).

GIST that appear outside of the gastrointestinal tract are very uncommon and are typically found in one single organ. Cases have been reported in the pancreas, liver, omentum, prostate, seminal vesicle, pleura, etc., although they are rare. These are classified as EGIST.

The primary location in the liver is exceptional, and there are no protocols to assess the risk for malignancy in this location. In our case, gastroscopy and colonoscopy were normal, CT and PET/CT showed no evidence of extrahepatic disease, and there was no evidence of recurrence after 18 months of follow-up. Therefore, we concluded that the disease

Download English Version:

<https://daneshyari.com/en/article/8826635>

Download Persian Version:

<https://daneshyari.com/article/8826635>

[Daneshyari.com](https://daneshyari.com)