



Contents lists available at ScienceDirect

## International Journal of Surgery Case Reports

journal homepage: [www.casereports.com](http://www.casereports.com)

# Surgical approach to a mycotic aneurysm of the pulmonary artery presenting with hemoptysis – A case report and a review of the literature

Leila Louise Benhassen<sup>a,\*</sup>, Anette Højsgaard<sup>a</sup>, Kim Allan Terp<sup>a</sup>, Frank Vincenzo de Paoli<sup>a,b</sup>

<sup>a</sup> Department of Cardiothoracic and Vascular Surgery, Aarhus University Hospital, Palle-Juul Jensens Boulevard 99, DK-8200, Aarhus N, Denmark

<sup>b</sup> Department of Biomedicine, Aarhus University, Vennelyst Boulevard 4, DK-8000, Aarhus C, Denmark

## ARTICLE INFO

## Article history:

Received 25 May 2018

Received in revised form 16 July 2018

Accepted 24 July 2018

Available online 31 July 2018

## Keywords:

Case report

Aneurysm

Pulmonary artery

Hemoptysis

Midline surgical approach

## ABSTRACT

**INTRODUCTION:** Mycotic aneurysms of the pulmonary arteries are very rare and have high mortality. Risk groups are intravenous drug users and patients with congenital heart disorders. The surgical approach varies due to a limited number of reported cases.

**PRESENTATION OF CASE:** We present a case of a mycotic aneurysm of the right pulmonary artery in a 56-year old man presenting with recurrent pneumonias, weight loss and hemoptysis.

**DISCUSSION:** There is often a diagnostic delay because of non-specific symptoms mimicking more common disorders. Treatment strategies include conservative management, surgery and endovascular treatment.

**CONCLUSION:** This report demonstrates a rare case of aneurysm of the pulmonary artery presenting with hemoptysis. For rapidly progressing proximal aneurysms of the pulmonary arteries, the midline surgical approach is recommended.

© 2018 The Author(s). Published by Elsevier Ltd. on behalf of IJS Publishing Group Ltd. This is an open access article under the CC BY-NC-ND license (<http://creativecommons.org/licenses/by-nc-nd/4.0/>).

## 1. Introduction

Aneurysms are irreversible vascular dilatations involving all three layers of the vessel wall [1]. Infections causing aneurysms, mycotic aneurysms, are estimated to represent only 1–3% of all arterial aneurysms and are rarely located in pulmonary arteries [2]. Patients may present with dyspnea, chest pain, cough, pulmonary hypertension, right ventricular failure and hemoptysis. Hemoptysis is estimated to be present in less than 10% of cases, however, when present the suspicion of a pulmonary aneurysm should be raised [1,2]. The non-specific presentation often causes diagnostic delay resulting in critical progression of the aneurysm.

We report here a case of successful surgical treatment for a mycotic aneurysm of the right pulmonary artery. The present case has been reported in line with the SCARE-criteria [3].

## 2. Presentation of case

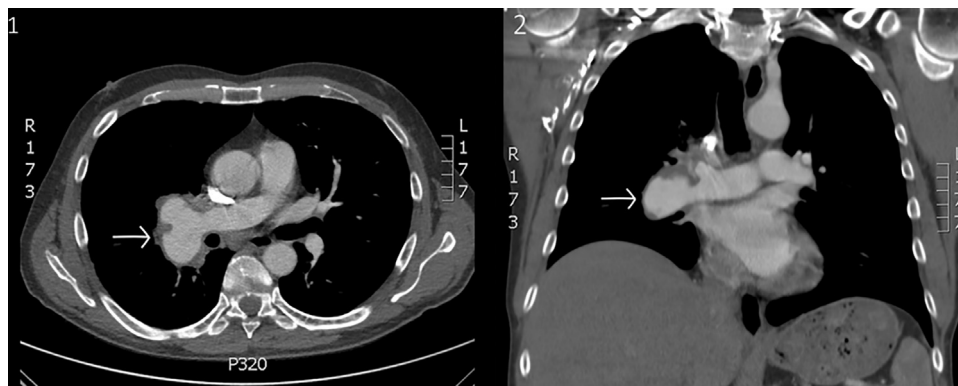
A 56-year old man was admitted with recurrent pneumonias and symptoms of dyspnea and productive coughing for eight months, as well as hemoptysis and relapsing fever for the last three

months. Moreover, he had a weight loss of 12 kilos, excessive tiredness and persistently elevated infection parameters. A PET/CT scan showed pneumonic infiltrates in the upper and lower lobe of the right lung and an enlarged mass in the right hilum, interpreted as lymph nodes. Bronchoscopy and bronchoalveolar lavage revealed no signs of malignancy. The patient was treated with antibiotics but showed no signs of recovery during the following three months. An additional CT scan with contrast was performed suggesting the enlarged mass in the right hilum to be an aneurysmatic expansion of the right pulmonary artery (55 mm) indicating a mycotic aneurysm-formation with peripheral pulmonary embolisms to all three lobes of the right lung (Figs. 1 and 2). Following a multidisciplinary team meeting it was decided to manage the aneurysm conservatively with anticoagulants and antibiotics and repeat CT scan after 4 weeks. However, four days later an x-ray raised suspicion of progression of the aneurysm. An urgent CT scan confirmed progression of the aneurysm to 595 mm, as well as progression of pulmonary embolisms (Fig. 3). Transesophageal echocardiography (TEE) showed no signs of endocarditis or pulmonary hypertension. There was no confirmation of positive blood cultures. The treatment strategy was changed to a pneumonectomy of the right side.

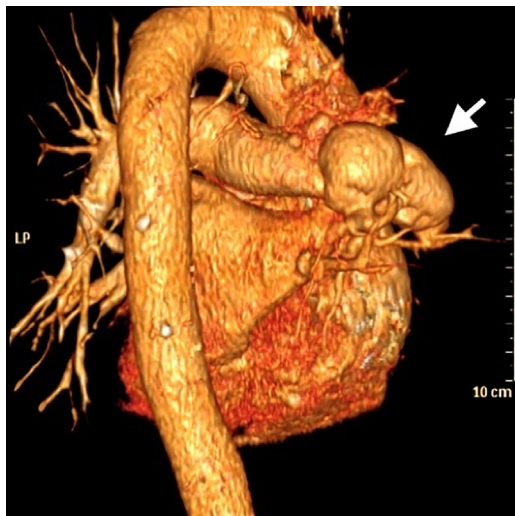
A pneumonectomy of the right lung was performed through a median sternotomy. Intraoperatively, the tissue of the aneurysm was considered of good quality, which made it possible to resect the tissue in close proximity to the aneurysm. The operation was per-

\* Corresponding author.

E-mail address: [benhassen@live.dk](mailto:benhassen@live.dk) (L.L. Benhassen).



**Fig. 1.** 1) Cross-sectional CT with contrast. Arrow pointing at the mycotic aneurysm with thrombus-formation located on the right pulmonary artery; 2) Longitudinal CT contrast. Arrow pointing at the mycotic aneurysm.



**Fig. 2.** CT reconstruction from a posterior-lateral view. Arrow pointing at the aneurysm on the right pulmonary artery.

formed without complications and the patient made an uneventful recovery and was discharged 15 days after surgery. Biopsies from the aneurysm revealed no microbiological focus, despite this the patient received Carbapenem for two weeks and Moxifloxacin for another two weeks postoperatively. Four months after the surgery, the patient revealed no symptoms or signs of infection and has started working again. Control CT scan shows no abscesses or new aneurysm formation.

### 3. Discussion

The case presented several diagnostic and management challenges. The enlarged mass in the right hilum found on X-ray was initially interpreted as enlarged lymph nodes. Due to malignancy-suspect symptoms such as weight loss, coughing and recurrent pneumonias, cancer was considered as a differential diagnosis, but was excluded on the subsequent PET/CT scan. Bronchoscopy and bronchoalveolar lavage revealed no signs of malignancy, and the patient was discharged with antibiotics. When the patient showed no signs of recovery after months, a CT scan was performed, and what was thought to be enlarged lymph nodes was now recognized as a pulmonary artery aneurysm with several septic thromboembolisms.

Relative few cases have been reported of aneurysms of the pulmonary arteries. Known risk factors are IV drug use, congenital heart disease such as ventricular septal defect (VSD), generalized

vasculitis, pulmonary hypertension, infection and immunosuppression [1]. Additional, according to Table 1 endocarditis seems to be a major predisposing factor for development of mycotic aneurysms. Mycotic aneurysms of the pulmonary arteries constitute a minority of the aneurysms at this site, and as seen in Table 1 they are commonly caused by suppurative bacterial infections such as staphylococci and streptococci or fungi including *Candida* and *Aspergilli* [4,5]. In the present case neither a bacteriological focus nor any of the risk factors mentioned above were present, however, since several septic thromboembolisms were located in the right lung, a mycotic aneurysm was a plausible diagnosis.

The proposed pathological mechanisms are i) direct spreading to a pulmonary artery from an adjacent focus of pulmonary infection, ii) ischemic injury to the pulmonary arterial wall as a result of infection of the vasa vasorum or iii) direct extension into a vessel wall from an intraluminal septic thromboembolus or from hematogenous spreading [1,4]. According to Table 1, the latter is the most frequent route of transmission with endovascular seeding originating from endocarditis, IV drug use, skin abscesses or pneumonia [1]. Since TEE showed no signs of endocarditis and all blood cultures were negative, in our case direct spread from a pulmonary focus or endovascular seeding from the pulmonary embolisms are the most likely pathological mechanisms.

Pulmonary angiography was previously gold standard, but recently MRI and CT with contrast have become the preferred diagnostic alternatives [4], which is confirmed in this case report. According to Bartter et al. the prognosis for mycotic aneurysms of the pulmonary arteries without interventional treatment is awful with mortality rates of 40–82% due to rupture [1]. Indeed, these mortality rates are confirmed in Table 1 showing a 63% (10 of 16 cases) mortality rate for patients not receiving surgical intervention, in contrast, patients receiving open surgical intervention with aneurysmectomy or removal of the affected part of the lung have a reduced mortality rate of 22% (2 of 9 cases). The management of these patients is difficult due to a lack of clear guidelines and sparse clinical experience. The proposed treatment strategies are diverse and include surgical interventions such as aneurysmectomy, lobectomy, pneumonectomy or embolotherapy [4,5]. Small mycotic aneurysms can also be treated conservatively, but regular CT scans are mandatory [6]. Less invasive approaches, e.g. lobectomy or segmental resection of lung parenchyma through a thoracotomy, are normally recommended, if feasible. However, for rapid progressing proximal aneurysms of the pulmonary artery, a midline approach through a sternotomy is to be recommended due to the possibility of central control in case of complications such as bleeding and the possibility to divide the structures more proximally in case of fragile tissue. Alternative nonsurgical interventional procedures, such as coil embolization or occlusion by detachable balloons might be

Download English Version:

<https://daneshyari.com/en/article/8832403>

Download Persian Version:

<https://daneshyari.com/article/8832403>

[Daneshyari.com](https://daneshyari.com)