CASE REPORT – OPEN ACCESS

International Journal of Surgery Case Reports 48 (2018) 65–68

Contents lists available at ScienceDirect

International Journal of Surgery Case Reports

journal homepage: www.casereports.com

A gastrointestinal stromal tumor of the jejunum presenting with an intratumoral abscess: A case report and a literature review

Soichi Ito*, Yuma Tsuchitani, Yuro Kim, Souhei Hashimoto, Yuichi Miura, Takuji Uemura, Kazunori Katsura, Takayuki Abe, Koichiro Sato, Hirotaka Kato

Department of Surgery, Iwate Prefectural Iwai Hospital, 17 Odaira, Kozenji, Ichinoseki, Iwate, 029-0192, Japan

ARTICLE INFO

Article history:
Received 18 April 2018
Accepted 17 May 2018
Available online 29 May 2018

Keywords:
Gastrointestinal stromal tumor
Small intestine
Intratumoral abscess
Case report

ABSTRACT

INTRODUCTION: Gastrointestinal stromal tumors (GISTs) are the most common mesenchymal tumors of the gastrointestinal tract. The small intestine is the second-most frequent location where GISTs occur after the stomach. Attention should be paid to small intestinal GISTs because they infrequently present with acute abdomen, which necessitates emergency surgery. This report describes a patient with a small intestinal GIST developing a giant intratumoral abscess, in whom emergency surgery was performed.

PRESENTATION OF CASE: A 56-year-old woman presented with worsening abdominal pain. Computed tomography scan showed an approximately 9.5 cm × 9 cm tumor bearing a thick and hypervascularized wall with an internal air-fluid level. Emergency laparotomy revealed the tumor originated from the jejunum, and partial resection of the jejunum was performed. A large amount of pus was contained inside the tumor. Immunohistochemically, the tumor was diagnosed as a high risk GIST of the Cjejunum, and imatinib mesylate was initiated.

DISCUSSION AND CONCLUSION: When an intratumoral abscess in the abdomen is confirmed, GISTs should be listed as differential diagnosis. Complete surgical resetcion with careful handling and adjuvant chemotherapy with imatinib mesylate are considered to be important for this state.

© 2018 The Authors. Published by Elsevier Ltd on behalf of IJS Publishing Group Ltd. This is an open access article under the CC BY-NC-ND license (http://creativecommons.org/licenses/by-nc-nd/4.0/).

1. Introduction

Gastrointestinal stromal tumors (GISTs) are the most common mesenchymal tumor of the gastrointestinal tract. They can occur throughout the gastrointestinal tract, and the small intestine is the second-most frequent location after the stomach. Small intestinal GISTs are often asymptomatic until they grow large, and their clinical presentation is highly variable. Attention should be paid to small intestinal GISTs because they infrequently manifest abdominal emergencies such as bowel obstruction, tumor rupture, perforation, and intratumoral abscess formation. This report describes a patient with a small intestinal GIST that developed a giant intratumoral abscess together with a review of published cases. This work has been reported in line with the SCARE criteria [1].

2. Presentation of case

A 56-year-old otherwise healthy woman walked into the emergency room of our hospital with worsening abdominal pain for 4 days. Her body temperature was 38.1°; blood pressure, 92/54 mmHg; and heart rate, 107 beats/min. Physical examination revealed tenderness and muscular defense around the lower abdomen. Blood tests showed elevation in white blood cell count (11,160/μl) and C-reactive protein level (5.4 mg/dl). Levels of CEA and CA19-9 were within normal ranges. Contrast-enhanced computed tomography (CT) scan showed an irregularly shaped tumor in the lower abdomen measuring approximately 9.5 cm × 9 cm × 5.5 cm (Fig. 1a, b). The tumor wall was thick and enhanced with intravenous contrast material, suggesting hypervascularity. An air-fluid level was contained in the tumor. Free air and ascites were not observed. Because her general condition was not bad, and the CT scan findings did not suggest peritonitis, intravenous administration of antibiotics was chosen as initial treatment. In addition, preoperative examinations including upper and lower endoscopies and magnetic resonance imaging were planned. However, because her clinical symptoms and laboratory data did not respond to the treatment, and because her status was accompanied with high fever after admission, an emergency surgical procedure was performed on the 6th day after her admission.

Diagnostic laparoscopy was initially performed. Slightly turbid ascites were observed and collected for the culture test. The procedure also showed that the tumor was movable and was expected to be resectable. Therefore, open exploration was performed through

Abbreviations: GIST, gastrointestinal stromal tumors; CEA, carcinoembryonic antigen; CA19-9, cancer antigen 19-9.

* Corresponding author.
E-mail address: soitou-ncd@umin.ac.jp (S. Ito).

https://doi.org/10.1016/j.ijscr.2018.05.012
2210-2612/© 2018 The Authors. Published by Elsevier Ltd on behalf of IJS Publishing Group Ltd. This is an open access article under the CC BY-NC-ND license (http://creativecommons.org/licenses/by-nc-nd/4.0/).

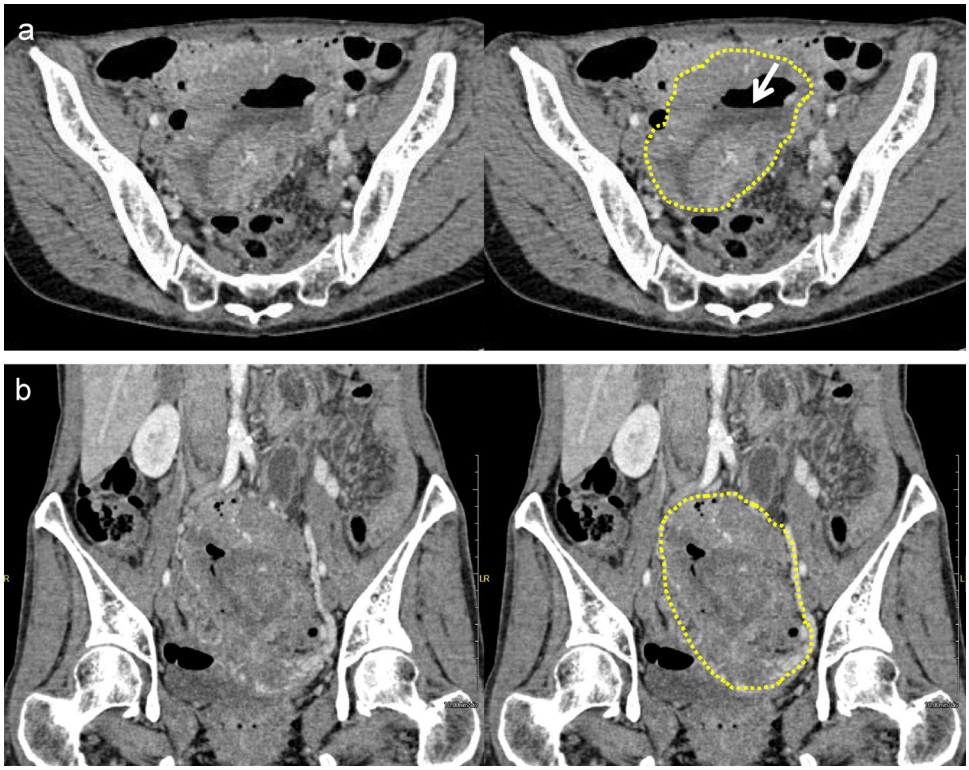

Fig. 1. (a, b) Contrast-enhanced computed tomography scan of the lower abdomen showing a large tumor (dotted line) bearing a thick and enhanced wall with an internal air-fluid level (arrow).

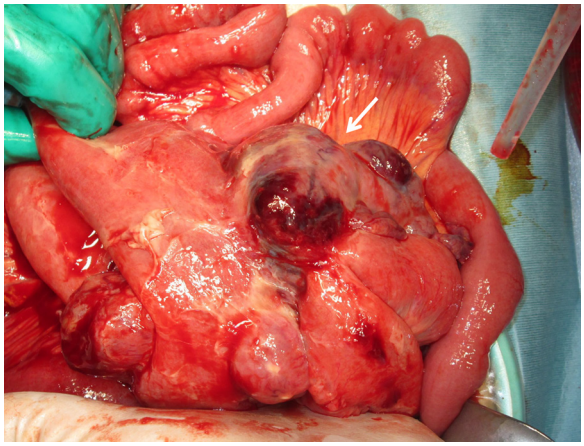

Fig. 2. Intraoperative photograph showing a tumor arising from the jejunal wall (arrow).

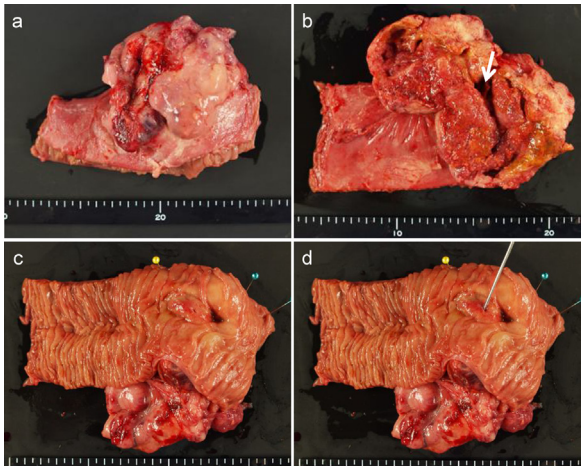

Fig. 3. Macroscopic findings of the tumor. (a) Gross appearance of the tumor. (b) A cavity surrounded by a thick tumor wall (arrow). (c, d) A small fistula between the cavity and intestinal lumen was observed.

a midline incision. The laparotomy revealed that the tumor arose from the jejunum wall, and was located 20 cm from the ligament of Treitz (Fig. 2). Loose adhesion without invasion was observed and the tumor was easily separable with blunt dissection. Macroscopic perforation was not observed to be apparent. Partial resection of the jejunum with the tumor and sampling of some nearby lymph nodes were performed, and a small portion of the tumor was sent for frozen section, which revealed proliferation of spindle-shaped tumor cells. Thus, this patient was diagnosed as having a mesenchymal tumor of the jejunum, and lymphadenectomy was omitted.

At macroscopic observation, the excised tumor, measuring 9 cm in diameter, was irregularly shaped with a soft tumor wall, and had a central cavity containing a large amount of pus (Fig. 3a, b). There was a small fistula between the cavity and the intestinal lumen (Fig. 3c, d). The culture test of the ascites was negative for bacteria.

Hematoxylin and eosin staining showed proliferation of spindle-shaped tumor cells. Immunohistochemical staining showed that the tumor cells were positive for c-KIT, CD34, SMA, and negative for Desmin, S-100. Mitotic count was 6/50 High Power Fields. Metastasis to the sampled lymph nodes was not observed. Therefore, the final diagnosis was high-risk GIST of the jejunum. Postoperative recovery was uneventful and she was discharged home on the 10th postoperative day. Thereafter, adjuvant imatinib mesylate was administered.

3. Discussion

GISTs are the most common mesenchymal tumors of the gastrointestinal tract. They can occur throughout the gastrointestinal

Download English Version:

https://daneshyari.com/en/article/8832567

Download Persian Version:

https://daneshyari.com/article/8832567

Daneshyari.com