



Contents lists available at ScienceDirect

International Journal of Surgery Case Reports

journal homepage: www.casereports.com

Paracecal hernia with intestinal ischemia treated with laparoscopic assisted surgery

Koichi Inukai*, Eri Tsuji, Shuhei Uehara

Department of Surgery, Kariya Toyota General Hospital, Aichi, Japan

ARTICLE INFO

Article history:

Received 21 December 2017
Received in revised form 18 January 2018
Accepted 11 February 2018
Available online 14 February 2018

Keywords:

Paracecal hernia
Internal hernia
Laparoscopic surgery

ABSTRACT

INTRODUCTION: Paracecal hernia is rare, and strangulation with ischemia has been infrequently observed in the limited number of published reports on paracecal hernias.

PRESENTATION OF CASE: We describe a case of an incarcerated paracecal hernia with resultant ischemic bowel that was successfully treated with laparoscopic-assisted surgery. A 54-year-old man who had not undergone any surgery previously presented to our hospital with abdominal pain and vomiting. An abdominal computed tomographic scan showed evidence of an intestinal obstruction at a paracecal site. An emergency laparoscopic surgery demonstrated incarceration of a loop of the small bowel in the paracecal fossa. We removed the incarcerated small bowel from the paracecal fossa, noted that the tissue was necrotic, and resected this segment of bowel through a mini-laparotomy incision. The patient was discharged on the 13th postoperative day.

DISCUSSION AND CONCLUSION: This case is unique in that the patient presented with small bowel strangulation, causing intestinal ischemia. Laparoscopic surgery is useful in the diagnosis of internal hernias and is also useful for the treatment of small bowel obstruction due to paracecal hernias complicated by ischemic bowel.

© 2018 The Author(s). Published by Elsevier Ltd on behalf of IJS Publishing Group Ltd. This is an open access article under the CC BY-NC-ND license (<http://creativecommons.org/licenses/by-nc-nd/4.0/>).

1. Introduction

Internal hernias are relatively rare, and the incidence of paracecal hernia is particularly low [1]. Paracecal hernia is an uncommon type of internal hernia that is difficult to diagnose preoperatively because of its varied symptoms. In a paracecal hernia, herniation generally occurs through an orifice that develops from the peritoneal recess formed by folds of the peritoneum in the paracecal area. According to reviews of cases that describe such hernias, it is unlikely that bowel resection is necessary for treatment because of the wide hernia orifice. Laparoscopic surgery for acute bowel obstruction is less invasive than laparotomy. We report a case of a paracecal hernia complicated by ischemic bowel that was successfully treated with laparoscopic-assisted surgery. The work has been reported in line with the SCARE criteria [2].

2. Case presentation

A 54-year-old man visited our hospital with abdominal pain and vomiting. He had not undergone any surgery previously. On physical examination, his body temperature was 36.9 °C, his blood

pressure was 101/66 mmHg, and his pulse rate was 71 bpm. He had slight tenderness to palpation in the right lower abdomen. Laboratory findings were only significant for an abnormally elevated white blood cell count of 11,100/mm³. A plain x-ray imaging of the abdomen showed bowel gas in his left upper abdomen (Fig. 1). An enhanced computed tomographic scan showed evidence of an intestinal obstruction at a paracecal site, with dilatation of the small intestine at the proximal side (Fig. 2a). A change in the small intestinal caliber was seen around the cecum (Fig. 2b). Small bowel ischemia was suspected because of the weak radiographic contrast effect. Based upon this clinical picture, the patient was diagnosed as having intestinal ileus from small bowel strangulation due to an internal hernia. An emergency laparoscopic surgery was performed.

First, a trocar was placed in the umbilical position under optical guidance, and then two additional trocars were added in the lower median region and the left lower quadrant. A segment of ileum about 15 cm in length was visibly incarcerated in the paracecal fossa (Fig. 3a). The hernia contents were difficult to reduce because of the size of the hernia defect. The infarcted segment of the small bowel was released with considerable effort, and the redundant peritoneum was resected (Fig. 3b). Through a mini-laparotomy incision, the ischemic bowel segment was resected, followed by an anastomosis. After surgery, the patient had a paralytic ileus, but conservative therapy improved his condition in a short period of

* Corresponding author at: 5-15 Sumiyoshi-cho, Kariya, Aichi, 448-8505, Japan.
E-mail address: koichi.sums@gmail.com (K. Inukai).

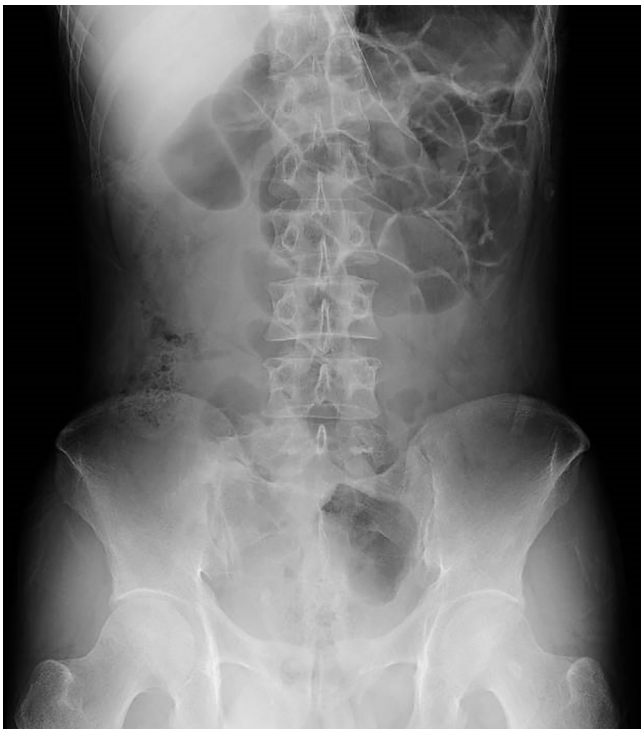


Fig. 1. A plain x-ray imaging of the abdomen showed bowel gas in his left upper abdomen.

time. The patient was discharged from the hospital 17 days after the operation.

3. Discussion

The paracecal hernia is a type of internal hernia. It is identified as the cause of 1% of all cases of intestinal ileus [1]. Internal hernias are classified into six types: paraduodenal, pericecal, foramen

of Winslow, transmesenteric, pelvic and supravesical, and intersigmoid [3]. Pericecal hernias can be sub-classified into four types: superior ileocecal recess, inferior ileocecal recess, paracolic sulcus, and retrocecal recess [4]. According to Hirokawa et al. [5], paracecal hernias are the most common type of pericecal hernia.

In a PubMed search of the literature published from 1980 to 2017, using the keywords “paracecal hernia,” “retrocecal hernia,” “pericecal hernia,” and “ileocecal hernia”, we found only 21 English language reports, describing 26 cases of internal hernias (Table 1). A summary of our search indicated a mean patient age of 62 years, with the patient ages ranging from 8 weeks to 92 years. There appeared to be no significant differences in the occurrence rate between men and women. Four patients had a prior history of abdominal surgery. Only five patients required bowel resection because of intestinal ischemia [6–9]. Four of those five patients had no history of abdominal surgery [7–9]. Pericecal hernia occurs primarily as a result of congestive factors. Moreover, it may be possible that pericecal hernias are acquired by fragility due to aging, increased pressure in the inner abdomen, adhesions in the retroperitoneum, and potentially other undiscovered factors [10]. We were previously inclined to believe that pericecal hernias would be unlikely to cause intestinal ischemia by strangulation. However, this case presented the possibility that the strangulation in these cases, and that the onset can be both rapid and aggressive. Therefore, whenever small bowel strangulation is suspected, surgery should be performed immediately.

Recently, laparoscopic surgery has been widely performed for small bowel obstructions [11]. Laparoscopic surgery is highly diagnostic, but is also minimally-invasive in comparison with open surgery. There have been seven prior reports of pericecal hernia treated using laparoscopy [5,10,12–16].

To our knowledge, this is the first case of pericecal hernia with a bowel resection performed via laparoscopic-assisted surgery. Laparoscopic management is currently considered to be satisfactory for both diagnosis and treatment due to faster patient recovery times. Even in cases involving bowel resection, minimally invasive laparoscopic treatment for this condition may be available.

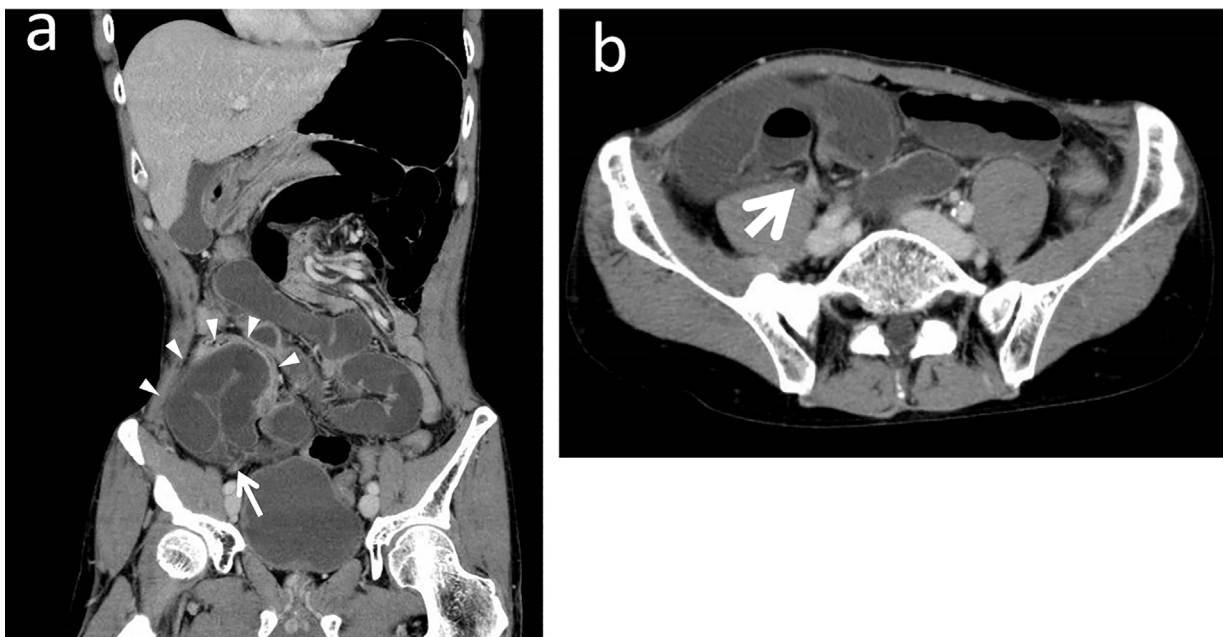


Fig. 2. (a) An enhanced computed tomographic scan showed evidence of an intestinal obstruction at a paracecal site, with dilatation of the small intestine at the proximal side. The hernia sac (arrowheads) and defect (arrow) could be seen. (coronal image). (b) A change in the small intestinal caliber was seen around the cecum (axial image, arrowhead).

Download English Version:

<https://daneshyari.com/en/article/8832752>

Download Persian Version:

<https://daneshyari.com/article/8832752>

[Daneshyari.com](https://daneshyari.com)